



**JOSÉ ALVAREZ-NEMEGYEI, MD, MSc**

Unidad de Investigación en Epidemiología Clínica, Unidad Médica de Alta Especialidad, Instituto Mexicano del Seguro Social, Mérida, Yucatán, México

**JUAN J. CANOSO, MD**

Rheumatologist, American British Cowdray Medical Center, Mexico City, Mexico; Adjunct Professor of Medicine, Tufts University School of Medicine, Boston, MA

# Heel pain: Diagnosis and treatment, step by step

## ■ ABSTRACT

The differential diagnosis of heel pain is broad and can be overwhelming if a systematic approach is not used. Focused questions and physical examination can help identify heel pain as Achilles tendinopathy or plantar fasciitis, or as due to a less common cause such as gout, spondyloarthritis, or hypercholesterolemia.

## ■ KEY POINTS

Noninsertional Achilles tendinopathy arises from tendon overuse or, less often, from fluoroquinolone antibiotic use. Key features are pain, swelling, and tenderness 2 to 6 cm from the insertion of the Achilles tendon into the calcaneus.

Many case reports have suggested an association between fluoroquinolone use and tendinopathy. In most instances the Achilles tendon was involved, predominantly the noninsertional portion.

Insertional Achilles tendinitis is caused by local mechanical factors or enthesitis. Pain, swelling, and tenderness occur at the Achilles tendon insertion. Treatment depends on the cause.

Plantar heel pain in athletes is caused by overuse, while in nonathletes the exact cause remains controversial. Pain and focal tenderness at the inferior heel are key features. Treatments include risk factor modification, nonsteroidal anti-inflammatory drugs, stretching, and orthotics.

**H**EEL PAIN COULD be a sign of spondyloarthritis or gout, or even a clue to hypercholesterolemia and sickle-cell disease. But most often it is an isolated, local complaint that results from a deranged tendon, bursa, nerve, or bone.

In this article, we offer a stepwise approach to the diagnosis and management of heel pain, and we review what the medical literature to date says about the effectiveness of current treatments.

## ■ THREE STEPS TO NARROW THE DIAGNOSIS

The differential diagnosis of heel pain is broad (TABLE 1) and can be overwhelming if a systematic approach is not used.<sup>1</sup>

As with any musculoskeletal problem, the first question to ask is, Where does it really hurt? The patient may point to the back of the heel, the bottom of the heel, or around the ankle.

Next is to look for any structural faults by assessing passive and resisted motion and palpating for the site of maximum tenderness.

Finally, further questions should be directed at uncovering inflammatory and metabolic diseases, in particular spondyloarthritis and gout, as well as recent use of a fluoroquinolone antibiotic.

## ■ NONINSERTIONAL ACHILLES TENDINOPATHY

In noninsertional Achilles tendinopathy, the tendon is damaged 2 to 6 cm from its insertion into the calcaneus. It is not only the most frequent cause of posterior heel pain, but also the most common tendon disorder in athletes.<sup>2</sup> It

TABLE 1

**Differential diagnosis of heel pain****Posterior heel pain**

Noninsertional Achilles tendinopathy

Overuse

Fluoroquinolone-induced

Dyslipidemia (xanthomas)

Rheumatoid arthritis (nodules)

Gout (tophi)

Insertional Achilles tendinitis

Enthesitis: spondyloarthropathies

Fluoroquinolone-induced

Dyslipidemia (xanthomas)

Isotretinoin-induced

Fluorosis

Ochronosis

Haglund deformity

Superficial retrocalcaneal bursitis

Deep retrocalcaneal bursitis

Spondyloarthropathies

Rheumatoid arthritis

Crystal-induced (gout, calcium pyrophosphate dihydrate)

**Plantar heel pain**

Plantar fasciopathy

Enthesitis: spondyloarthropathies

Calcaneal stress fracture or bone bruise

Fat pad atrophy

Neuropathies

Tarsal tunnel syndrome

Medial calcaneal branch of the posterior tibial nerve

Abductor digiti quinti muscle nerve

Soft-tissue tumors, primary or metastatic bone tumors

Paget disease of bone

Sever disease

Referred causes: S1 radiculopathy

MODIFIED FROM BUCHBINDER R. PLANTAR FASCIITIS. *N ENGL J MED* 2004; 350:2159-2166;  
AND CANOSO JJ, ALVAREZ-NEMEGYEI J. *SOFT TISSUE RHEUMATOLOGY*. IN: LAHITA RG,  
WEINSTEIN A, EDITORS. *EDUCATIONAL REVIEW MANUAL IN RHEUMATOLOGY*. 3RD EDITION.  
NEW YORK: CASTLE CONNOLLY GRADUATE MEDICAL PUBLISHING LTD, 2004

may result from overuse of the tendon, from use of a fluoroquinolone antibiotic, or from nodular formation within the tendon, as seen in tophaceous gout, xanthomatosis, and rheumatoid arthritis.

**An 'angiofibroblastic' rather than an inflammatory process**

In noninsertional Achilles tendinopathy due to overuse, histologic studies have not shown any inflammation. Instead, studies have consistently found "angiofibroblastic tendinopathy,"<sup>3</sup> a term that refers to degenerative

changes that occur when a tendon has failed to heal properly after an injury or after repetitive microtrauma (overuse). Histologically, angiofibroblastic tendinopathy is characterized by dense populations of fibroblasts, vascular hyperplasia, and disorganized collagen. Thus, the term "tendinitis" is inappropriate for noninsertional Achilles tendinopathy.<sup>3,4</sup>

In athletes, abnormal limb alignment, unequal leg length, lack of muscle flexibility, faulty training, and inappropriate equipment are all risk factors for this condition. Evidence suggests that sports-related noninsertional Achilles tendinopathy occurs when the tendon is exposed to a workload that is beyond its physical capability. Excessive, repetitive loads alter both tendon matrix and cells, cause microtears, and lead to incomplete healing. Persistence of the causative factor or factors eventually results in tendon thickening, nodularity, and in many cases a macroscopic tear.<sup>2,5</sup>

Hypovascularity was once thought to be a major pathogenic factor, but flow analysis and power Doppler ultrasonography have ruled this out.<sup>6,7</sup>

**Diagnosis: More common in athletes**

Noninsertional Achilles tendinopathy occurs most often in professional or recreational athletes. It may arise acutely and feature pain, swelling, and tenderness in the middle third of the Achilles tendon. More commonly, however, it presents in a subdued fashion with tendon pain and a feeling of hindfoot stiffness upon arising in the morning. Typically, symptoms fade after the first few steps. As the condition progresses, pain arises during the athletic activity. Eventually, the pain may be present throughout the day.<sup>2</sup>

**Clinical diagnostic tests** include direct palpation, the arc sign test (the tendinous swollen area moves during dorsiflexion and plantarflexion of the ankle), and the Royal London Hospital test. In the Royal London test, local tenderness is elicited by palpating the tendon with the ankle either in neutral position or with slightly plantar flexion. The tenderness decreases significantly or disappears completely with ankle dorsiflexion.

In a recent study,<sup>8</sup> the sensitivity and specificity of these tests were 58% and 74% for direct palpation, 52% and 83% for the arc sign



test, and 54% and 91% for the Royal London test. When the three tests were combined, sensitivity was 58% and specificity was 83%.

**Ultrasonography and magnetic resonance imaging (MRI)** have both shown an excellent diagnostic performance in this condition,<sup>9</sup> but ultrasonography is much less expensive, making it the choice of the two.

### Management based on some consensus

Despite limited evidence of the effectiveness of one treatment vs another, some agreement has been reached about therapy for noninsertional Achilles tendinopathy.<sup>2,10</sup> Initial measures include identification, suppression, and modification of predisposing factors, temporary suspension of sports activities, use of a nonsteroidal anti-inflammatory drug (NSAID), and physiotherapy that includes stretching exercises, especially those that focus on the calf muscles.

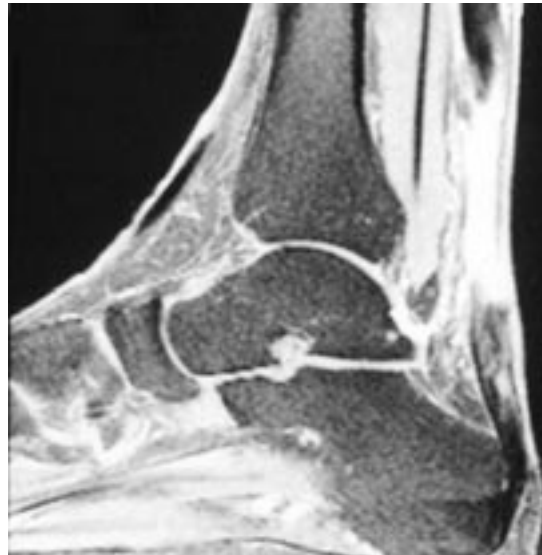In refractory cases, a peritendinous glucocorticoid injection is often used and may indeed be efficacious. Whether this procedure leads to tendon rupture has not been conclusively shown. Patients whose condition fails to improve with the above program should be considered for surgical treatment.

### Prognosis

In a prospective study by Paavola et al,<sup>11</sup> 83 of 107 patients with noninsertional Achilles tendinopathy underwent conservative treatment. Of these 83, 24 (29%) required surgical treatment, 70 (84%) returned to all activities, and 78 (94%) were asymptomatic or had mild pain during strenuous exercise. However, a comparison of the involved vs the uninvolved limb at  $8 \pm 2$  years of follow-up showed that the uninvolved limb still had a statistically significant advantage over the involved limb in terms of physical performance and tendon thickness measured with ultrasonography. Remarkably, 34 patients (41%) had subsequent involvement of the initially unaffected side.

### ■ FLUOROQUINOLONE-INDUCED ACHILLES TENDINOPATHY

Many case reports have suggested an association between fluoroquinolone use and



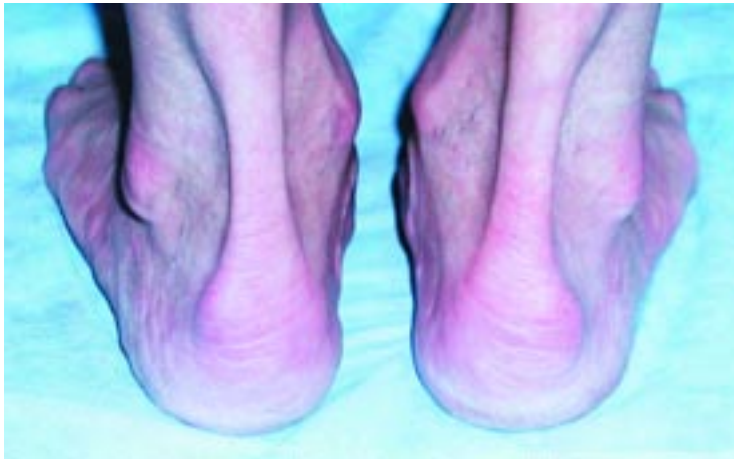**FIGURE 1.** A 60-year-old man developed pain, swelling, and severe tenderness in both Achilles tendons while taking ciprofloxacin for recurrent urinary tract infections. The severity of symptoms and suspicion of a partial rupture prompted magnetic resonance imaging, which showed an intense, bright signal within the noninsertional region of the Achilles tendon, suggesting rupture. During subsequent surgical exploration, the central portion of the tendon was found to be necrotic and was resected. The patient's recovery was slow but complete.

**First ask,  
Where does it  
really hurt?**

tendinopathy.<sup>12</sup> In most instances the Achilles tendon was involved, predominantly the noninsertional portion (**FIGURE 1**).

### Incidence and risk

Two retrospective controlled studies have been devoted to this issue. In the first, van der Linden et al<sup>13</sup> found a weak association—a relative risk of 1.3, with a 95% confidence interval of 0.4 to 4.7—between fluoroquinolone use and Achilles tendinopathy. In the second,<sup>14</sup> the adjusted risk for Achilles tendinopathy after fluoroquinolone exposure was 3.2 per 1,000, and the relative risk for Achilles tendinopathy after the first month of fluoroquinolone exposure was 1.9 (95% confidence interval 1.3–2.6). Age older than 60 years and concurrent glucocorticoid use were identified as additive risk factors.



**FIGURE 2.** A 46-year-old woman had a 2-week history of right posterior calcaneal pain. A prominent bump was seen laterally in both heels, lifting the distal Achilles tendon. She was advised to wear sandals and then try better fitting shoes.

**Insertional  
Achilles  
tendinitis:  
pain, swelling,  
posterior  
calcaneal  
tenderness**

**Features include bilateral involvement**

Features of fluoroquinolone-induced noninsertional Achilles tendinopathy include bilateral involvement, onset of symptoms during the first month after initial exposure (several cases occurred after a single dose), and a prolonged healing time.<sup>12</sup> The high rate of tendon tears suggested by the early case reports, contrasting with only 5% in the second van der Linden report, may have resulted from a Berkson's bias, ie, the high rate reflecting the fact that these patients were more likely to seek treatment at a hospital.

**Diagnosis via ultrasonography**

Ultrasonography is the method of choice for diagnostic imaging, as it is noninvasive, is relatively inexpensive, and can identify tendinopathy and tears.

**How fluoroquinolones damage tendons**

Several studies have begun to shed light on the pathogenesis of quinolone-induced tendinopathy. In vitro, human tenocytes express more matrix metalloproteinase 3 (which degrades connective tissue) in response to interleukin 1 if they are first incubated in ciprofloxacin. Furthermore, in experiments in rats, several fluoroquinolone compounds had a dose-dependent in vitro and in vivo tenotoxic effect.<sup>15-17</sup>

**■ INSERTIONAL ACHILLES TENDINITIS**

Insertional Achilles tendinitis may be caused mechanically by a heel bump (Haglund deformity) (FIGURE 2) compressing the tendon against the shoe counter, or it may be inflammatory, as in gout and the spondyloarthropathies.

**Pathogenesis**

Insertional Achilles tendinitis is an inflammation of the enthesis, the designation for the site where tendons, ligaments, and joint capsule attach to the bone. Enthesitis is a pivotal clinical and pathologic finding in the spondyloarthropathies, a group of conditions that include reactive arthritis, psoriatic arthritis, and ankylosing spondylitis, among others.<sup>18,19</sup> However, enthesitis in these conditions is not limited to the insertion site. For example, in spondyloarthropathy-associated insertional Achilles tendinitis, a concurrent effusion is often present in the retrocalcaneal bursa, wedged between the Achilles tendon and the calcaneus. Furthermore, calcaneal erosions in these conditions often develop beneath the bursa rather than at the actual site of tendon attachment.

These clinicopathologic features have led to the concept of the "entheseal organ" (FIGURE 3), an arrangement that includes the tendinous or ligamentous bone attachment and adjacent synovial cavity and cartilage.<sup>18-20</sup>

**Diagnostic maneuvers**

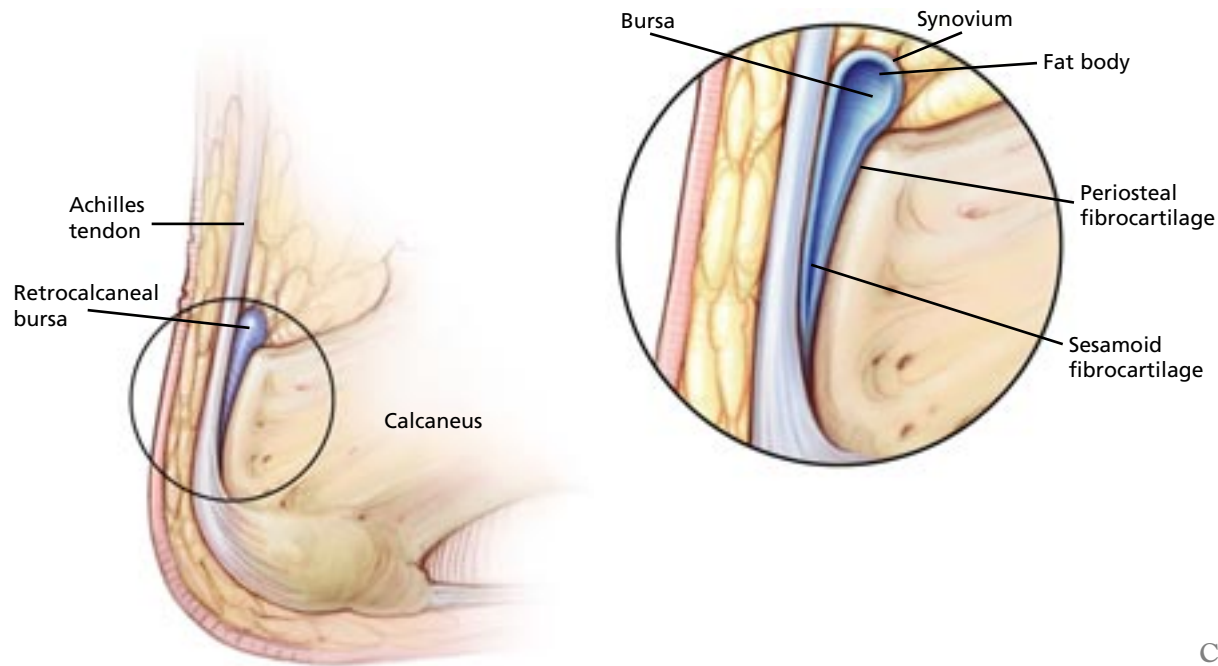
The key features of insertional Achilles tendinitis are pain, swelling, and tenderness in the back of the calcaneus. A calcaneal bump above and lateral to the Achilles insertion is characteristic of the Haglund deformity (FIGURE 2). In the spondyloarthropathies, in addition to the tendon findings, an effusion in the retrocalcaneal bursa can often be felt by three-finger palpation. In this maneuver the examiner places the index finger and thumb of one hand at each side of the insertional angle and applies pressure on the distal tendon with the other index finger. Fluctuation indicates an effusion of the retrocalcaneal bursa.

**Management**

Heel pain caused by a Haglund deformity may be relieved by using better-fitting shoes. The



## ■ Conceptualization of the ‘entheseal organ’



CCF  
©2006

**FIGURE 3.** According to the concept of the “entheseal organ,” the Achilles tendon inserts into the inferior half of the back of the calcaneus. The retrocalcaneal bursa is interposed between the tendon and the upper half of the calcaneus. The anterior and posterior walls of the bursa are cartilaginous: periosteal fibrocartilage in the calcaneal side, and sesamoid fibrocartilage in the tendon side. A fat body covered by synovium forms the roof of the bursa. This fat body fills the bursa in plantar flexion and exits the bursa in dorsiflexion.

same goes for the posterior heel pain caused by inflammation of a subcutaneous bursa in back of the heel. Refractory pain due to a Haglund deformity may be treated with open or endoscopic wedge osteotomy.

Entheseal organ inflammation in the spondyloarthropathies may be treated with systemic medications (which may include biologics such as tumor necrosis factor antagonists, if the case calls for these expensive drugs) or by an intrabursal corticosteroid injection. These injections are best given with ultrasonographic guidance whenever possible.<sup>18–20</sup> Because their safety is still an unresolved issue, intrabursal glucocorticoid injection should be performed by an expert after careful consideration of the risks (such as tendon tear and infection) and benefits.

Finally, surgical treatment should be considered when the condition does not respond to the conservative treatments mentioned above.

### ■ PLANTAR HEEL PAIN

As any physician working in an outpatient setting can attest, plantar heel pain is one of the most common regional pain syndromes. It is therefore surprising that we still do not know its true prevalence or incidence rate. Riddle<sup>21</sup> recently estimated that plantar fasciitis accounts for 1 million primary care consults and 1% of orthopedic visits a year in the United States.<sup>21</sup>

#### How and why it occurs

Several hypotheses have been advanced to explain the genesis of plantar heel pain.<sup>22</sup> A lesser thickness or compressibility index of the subcalcaneous fat pad has been proposed.<sup>23</sup> Another hypothesis is that it is due to an entrapment neuropathy of the nerve supplying the abductor digiti quinti. However, histologic evidence and most evidence from con-

trolled studies using scintigraphy, ultrasonography, and MRI suggest that it most often represents a noninflammatory (as in angiofibroblastic tendinopathy), mechanically induced enthesopathy at the calcaneal insertion of the plantar fascia.<sup>24–28</sup>

**Risk factors.** Plantar heel pain may result from overuse in recreational or professional athletic activities. Case-control studies with multivariate analysis indicate that structural and biomechanical factors bearing on the plantar fascia (pes cavus, pronated foot, an abnormal range of plantar flexion) increase the risk of plantar heel pain.<sup>29,30</sup>

Data on risk factors in nonathletes are few. Earlier studies that used univariate analysis suggest that both an increase in body mass index and overweight are risk factors in nonathletes.<sup>31,32</sup> Thus, in a recent controlled study by Riddle et al,<sup>33</sup> a decreased range of ankle dorsiflexion, a body mass index greater than 30, and a job that requires standing were identified as independent risk factors.

### Diagnosis

The diagnosis is almost always clinical. Typically, the location of the pain and the absence of associated symptoms indicating a systemic disease strongly suggest the diagnosis.

The key physical finding is central or centro-medial tenderness in the plantar aspect of the heel. In rare situations, imaging studies such as lateral radiography of the hindfoot, ultrasonography, or MRI are required to exclude alternative diagnoses, such as an amorphous calcium deposit, calcaneal stress fracture, or soft-tissue tumor.

Because the role of calcaneal spurs in the pathogenesis of plantar heel pain is controversial, and given their lack of prognostic or therapeutic implications, a radiographic search for a calcaneal spur is not warranted. Given its low cost and high resolution, ultrasonography is the imaging study of choice when the diagnosis of plantar heel pain is unclear.

### Management

Myriad treatments have been used for plantar heel pain, but scientific proof of efficacy for any of them is hard to come by. This is evi-

denced by a Cochrane database systematic review, based on 19 published controlled clinical trials of fair or good methodological quality.<sup>34</sup> The reviewers concluded that there was limited evidence that topical corticosteroids given by iontophoresis are effective in reducing pain. There was also some evidence that local corticosteroid injections provide temporary relief of pain.

The evidence in support of low-energy extracorporeal shock-wave therapy remained equivocal, and limited evidence supported the effectiveness of dorsiflexion night splints in reducing pain.<sup>34</sup>

### Other studies of treatment of plantar heel pain

In a controlled clinical trial, Di Giovanni et al<sup>35</sup> found that an exercise program specifically focused on distention of the plantar fascia resulted in less pain, greater patient satisfaction, and a higher functional status than exercises focusing on distention of the Achilles tendon.

Crawford et al<sup>36</sup> compared locally injected methylprednisolone vs lidocaine and found that after 1 month of treatment the patients receiving methylprednisolone had less pain.

The efficacy of extracorporeal shock-wave therapy in refractory plantar heel pain has been suggested in several reports. These findings were reinforced by a meta-analysis that concluded that extracorporeal shock-wave therapy is indeed efficacious in the treatment of plantar talalgia.<sup>37</sup> On the other hand, recent studies of good methodological quality suggest an opposite conclusion.<sup>38–40</sup> Thus, there is an obvious need for an updated systematic review that should include the earlier positive studies and the recent negative studies to shed additional light on this controversial issue.

Other therapies such as low-intensity local laser therapy, magnetic insoles, and therapeutic ultrasound have not shown efficacy compared with placebo in a controlled study. Controlled studies have also never been done to assess commonly used therapies such as NSAIDs and heel cups, infrequently used surgical treatment, and seldom-used low-dose local radiotherapy.<sup>34,41</sup>

**We still have no solid evidence of efficacy of plantar fasciitis treatments**



## Our recommendation: Step-by-step treatment

In our view, and in the view of most authors, treatment of plantar heel pain should proceed in a stepwise fashion and, according to the patient's response, as follows:

- First, modify or suppress the alleged risk factors, give an NSAID, prescribe a stretching program for the Achilles tendon, and recom-

mend orthotics such as heel pads and, if necessary, an ankle dorsiflexion night splint.

- If these fail, give one or two local injections of a glucocorticoid.
- If the injections are ineffective, consider extracorporeal shock-wave therapy or surgery.

At any rate, this progression should not be hurried, since many cases of plantar heel pain are self-limited.

## REFERENCES

1. Buchbinder R. Plantar fasciitis. *N Engl J Med* 2004; 350:2159–2166.
2. Alfredson H. Chronic midportion Achilles tendinopathy: an update on research and treatment. *Clin Sports Med* 2003; 22:727–741.
3. Astrom M, Rausing A. Chronic Achilles tendinopathy. A survey of surgical and histopathologic findings. *Clin Orthop Relat Res* 1995; 316:151–164.
4. Khan KM, Cook JL, Bonar F, Harcourt P, Astrom M. Histopathology of common tendinopathies. Update and implications for clinical management. *Sports Med* 1999; 27:393–408.
5. McCrory JL, Martin DF, Lowery RB, et al. Etiologic factors associated with Achilles tendinitis in runners. *Med Sci Sports Exerc* 1999; 31:1374–1381.
6. Astrom M, Westlin N. Blood flux in chronic Achilles tendinopathy. *Clin Orthop Rel Res* 1994; 308:166–172.
7. Reiter M, Ulreich N, Dirisamer A, Tscholakoff D, Bucek RA. Colour and power Doppler sonography in symptomatic Achilles tendon disease. *Int J Sports Med* 2004; 25:301–305.
8. Maffulli N, Kenward MG, Testa V, Capasso G, Regine R, King JB. Clinical diagnosis of Achilles tendinopathy with tendinosis. *Clin J Sport Med* 2003; 13:11–15.
9. Astrom M, Gentz CF, Nilsson P, Rausing A, Sjoberg S, Westlin N. Imaging in chronic achilles tendinopathy: a comparison of ultrasonography, magnetic resonance imaging and surgical findings in 27 histologically verified cases. *Skeletal Radiol* 1996; 25:615–620.
10. Järvinen TA, Kannus P, Paavola M, Järvinen TL, Jozsa L, Järvinen M. Achilles tendon injuries. *Curr Opin Rheumatol* 2001; 13:150–155.
11. Paavola M, Kannus P, Paakala T, Pasanen M, Jarvinen M. Long-term prognosis of patients with Achilles tendinopathy. An observational 8-year follow-up study. *Am J Sports Med* 2000; 28:634–642.
12. Khaliq Y, Zhanel GG. Fluoroquinolone-associated tendinopathy: a critical review of the literature. *Clin Infect Dis* 2003; 36:1404–1410.
13. van der Linden PD, van de Lei J, Nab NW, Know A, Stricker BH. Achilles tendinitis associated with fluoroquinolones. *Br J Clin Pharmacol* 1999; 48:233–237.
14. van der Linden PD, Sturkenboom MCJ, Herings RMC, Leufkens HGM, Striker BHC. Fluoroquinolones and risk of Achilles tendon disorders: case control study. *BMJ* 2002; 324:1306–1307.
15. Corps AN, Carral RL, Curry VA, Fenwick SA, Hazleman BL, Riley GP. Ciprofloxacin enhances the stimulation of matrix metalloproteinase 3 expression by interleukin-1beta in human tendon-derived cells. A potential mechanism of immature rats. *Arthritis Rheum* 2002; 46:3034–3040.
16. Kashida Y, Kato M. Characterization of fluoroquinolone-induced Achilles tendon toxicity in rats: comparison of toxicities of 10 fluoroquinolones and effects of anti-inflammatory compounds. *Antimicrob Agents Chemother* 1997; 41:2389–2393.
17. Shakibaei M, Stahlman R. Ultrastructural changes induced by the des-F(6)-quinolone garenoxacin (BMS-284756) and two fluoroquinolones in Achilles tendon from immature rats. *Arch Toxicol* 2003; 77:521–526.
18. McGonagle D, Gibbon W, Emery P. Classification of inflammatory arthritis by enthesitis. *Lancet* 1998; 352:1137–1140.
19. Canoso JJ. The premiere enthesitis. *J Rheumatol* 1998; 25:1254–1256.
20. Benjamin M, Moriggl B, Brenner E, Emery P, McGonagle D, Redman S. The "enthesitis organ" concept: why enthesopathies may not present as focal insertional disorders. *Arthritis Rheum* 2004; 50:3306–3313.
21. Riddle DL. Volume of ambulatory care visits and patterns of care for patients diagnosed with plantar fasciitis: a national study of medical doctors. *Foot Ankle Int* 2004; 25:303–310.
22. Singh D, Angel J, Bentley WB, Trevino SG. Plantar fasciitis. *BMJ* 1997; 315:172–175.
23. Prichasuk S. The heel pad in plantar heel pain. *J Bone Joint Surg* 1994; 76B:140–142.
24. Lemont H, Ammirati KM, Usen N. Plantar fasciitis: a degenerative process (fasciosis) without inflammation. *J Am Podiatr Med Assoc* 2003; 93:234–237.
25. O'Duffy EK, Clunie GPR, Gacinovic S, Edwards JCW, Bomanji JB, Eil PJ. Foot pain: specific indications for scintigraphy. *Br J Rheumatol* 1998; 37:442–447.
26. Kamel M, Kotob H. High frequency ultrasonographic findings in plantar fasciitis and assessment of local steroid injection. *J Rheumatol* 2000; 27:2139–2141.
27. Akfirat M, Sen C, Gunes T. Ultrasonographic appearance of the plantar fasciitis. *Clin Imaging* 2003; 27:353–357.
28. Yu JS. Pathologic and post-operative conditions of the plantar fascia: review of MR findings appearances. *Skeletal Radiol* 2000; 29:491–501.
29. Krivickas LS. Anatomical factors associated with overuse sports injuries. *Sports Med* 1997; 24:132–146.
30. Messier SP, Pittala K. Etiologic factors associated with selected running injuries. *Med Sci Sports Exerc* 1988; 20:501–505.
31. Hill JJ, Cutling PJ. Heel pain and body weight. *Foot Ankle* 1989; 9:254–256.
32. Rano JA, Fallat LM, Svoy-Moore RT. Correlation of heel pain with body mass index and other characteristics of heel pain. *J Foot Ankle Surg* 2001; 40:351–356.
33. Riddle D, Pulisic M, Pidcoe P, Johnson RE. Risk factors for plantar fasciitis. A matched case-control study. *J Bone Joint Surg* 2003; 85A:872–876.
34. Crawford F, Thompson C. Interventions for treating plantar heel pain. *Cochrane Data Syst Rev* 1, 2003.
35. DiGiovanni BF, Nawoczenski DA, Lintal ME, et al. Tissue-specific plantar fascia-stretching exercise enhances outcomes in patients with chronic heel pain. A prospective, randomized study. *J Bone Joint Surg* 2003; 85A:1270–1277.
36. Crawford F, Atkins D, Young P, Edwards SJ. Steroid injection for heel pain: evidence of short-term effectiveness. A randomized controlled trial. *Rheumatology* 1999; 38:974–977.
37. Ogden JA, Alvarez RG, Marlow M. Shockwave therapy for chronic proximal plantar fasciitis: A meta-analysis. *Foot Ankle Int* 2002; 23:301–308.
38. Buchbinder R, Ptaszink R, Gordon J, Buchanan J, Prabakaran V, Forbes A. Ultrasound-guided extracorporeal shock wave therapy for plantar fasciitis: A randomized controlled clinical trial. *JAMA* 2002; 288:1364–1372.
39. Haake M, Buch M, Schoellner C, et al. Extracorporeal shockwave therapy for plantar fasciitis: randomised controlled multicentre trial *BMJ* 2003; 327:75.
40. Speed CA, Nichols D, Wies J. Extracorporeal shock wave therapy for plantar fasciitis. A double blind randomised controlled trial. *J Orthop Res* 2003; 21:937–940.
41. Alvarez-Nemegyei J, Canoso JJ. Evidence based soft tissue rheumatology V: plantar talalgia. *J Clin Rheumatol* 2004; 10:259–262.

ADDRESS: José Alvarez-Nemegyei, MD, MARTHA No. 167, Col. Lomas de Tonalá, C.P. 45401, Tonalá, Jalisco, México; e-mail nemegyei@yahoo.com.mx.