



FIRAS ZAHR, MD

Department of Pulmonary, Allergy,  
and Critical Care Medicine,  
Cleveland Clinic

ATUL C. MEHTA, MD

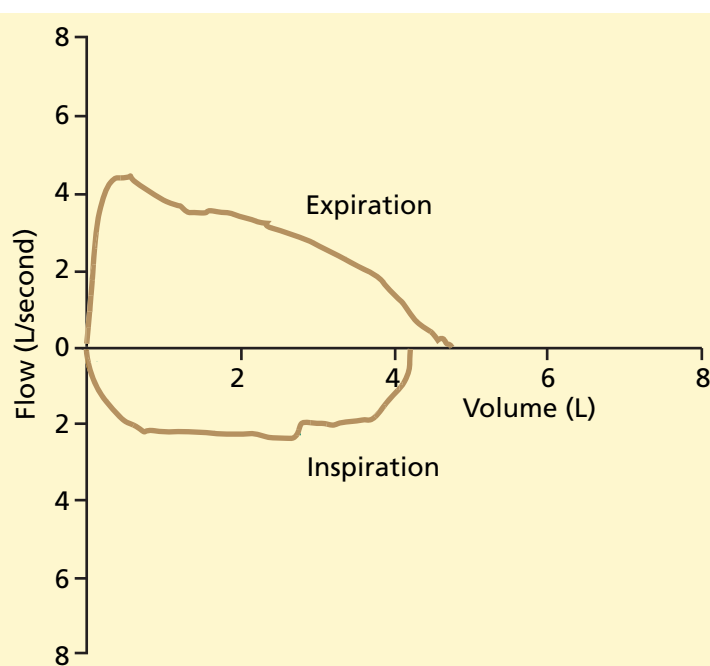
Department of Pulmonary, Allergy, and  
Critical Care Medicine, Cleveland Clinic

OMAR A. MINAI, MD

Department of Pulmonary, Allergy, and  
Critical Care Medicine, Cleveland Clinic

# The Clinical Picture

## A young man with unexplained dyspnea



**FIGURE 1.** Flow-volume loop in a patient with persistent dyspnea.

He underwent sinus surgery with difficult intubation. He was diagnosed with Wegener granulomatosis based on histopathology and was prescribed daily prednisone and cyclophosphamide. The pulmonary nodules resolved but the shortness of breath persisted.

**Physical examination.** Now, the patient has bilateral sinus tenderness, saddle-nose deformity, and malodorous nasal crusting. His lung fields are clear and his heart sounds are normal. His breathing pattern is normal with no use of accessory muscles or paradoxical breathing.

**CT of the chest** shows new nonspecific bilateral parenchymal nodules (2–3 mm), but marked improvement compared with the previous CT.

**Pulmonary function tests** reveal normal flows, volumes, and diffusion capacity. His FEV<sub>1</sub> has improved (3.4 L, 69% of predicted). His flow-volume loop is seen in **FIGURE 1**.

### ■ DYSPNEA IN WEGENER GRANULOMATOSIS

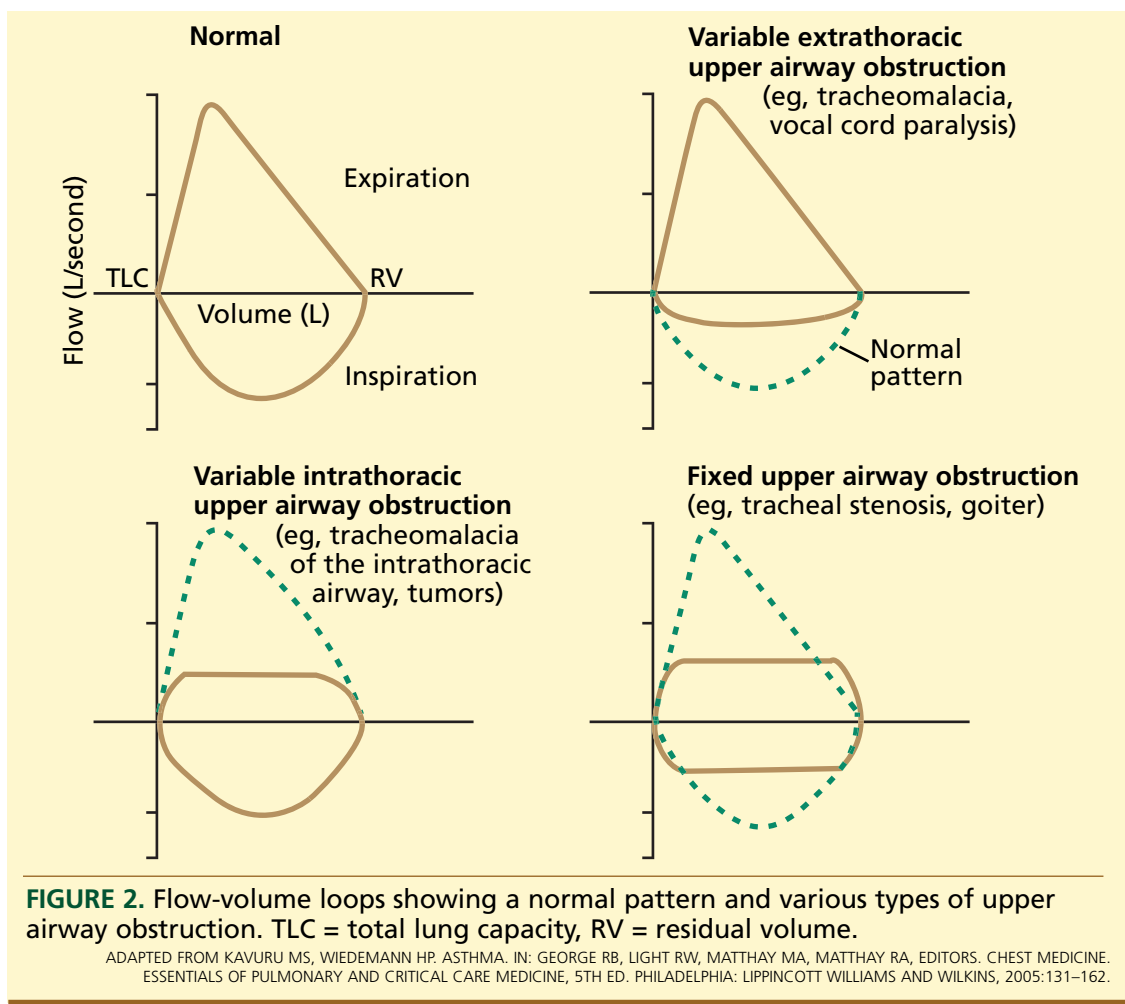
**Q:** What is the most likely cause of his persistent shortness of breath?

- ☐ Pulmonary vascular disease complicating Wegener granulomatosis
- ☐ Parenchymal lung disease due to Wegener granulomatosis
- ☐ Fixed upper airway obstruction
- ☐ Neuromuscular weakness

**A:** Pulmonary vascular disease complicating Wegener's granulomatosis is extremely rare<sup>1</sup> and does not explain the shape of the flow-volume loop or the bronchoscopic findings.

**A** 22-YEAR-OLD MAN presents to the pulmonary clinic with persistent dyspnea with exertion, nasal congestion, and epistaxis.

About a year ago, the patient was evaluated for the same symptoms at a community hospital. At the time, computed tomography (CT) of the chest revealed multiple pulmonary nodules with cavitation. Serum was positive for antineutrophil cytoplasmic antibodies with a cytoplasmic staining pattern (c-ANCA). Pulmonary function tests showed a forced vital capacity of 4.1 L (70% of predicted value) and a forced expiratory volume in 1 second (FEV<sub>1</sub>) of 2.62 L (54% of predicted).



Wegener causes otolaryngologic problems in more than 90% of cases

Parenchymal lung disease due to Wegener granulomatosis is an unlikely cause of the dyspnea because of the patient's significantly improved CT scan and pulmonary function findings following therapy.<sup>2</sup>

Neuromuscular weakness is not evident from the patient's clinical examination and measures of respiratory muscle strength.

Fixed upper airway obstruction is correct. Although the patient's pulmonary function tests are normal, the flow-volume loop (FIGURE 1) shows flattening of the inspiratory and expiratory limbs, indicating that fixed upper airway obstruction is likely.

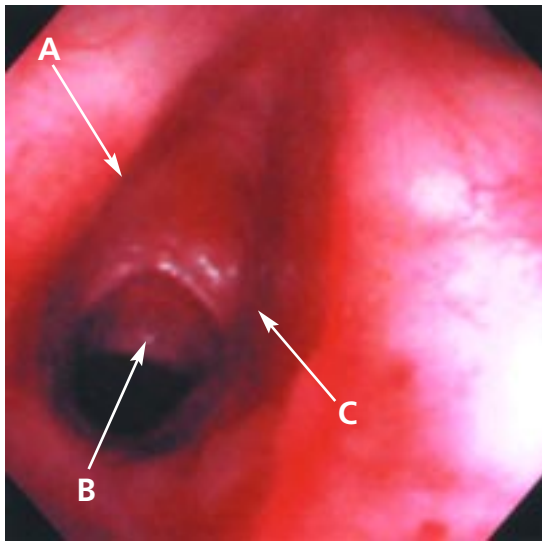
## ■ DEFINING UPPER AIRWAY OBSTRUCTION

Upper airway obstruction can be categorized into three types,<sup>3</sup> each having characteristic flow-volume loops (FIGURE 2).

**Variable extrathoracic obstruction** occurs with tracheomalacia or vocal cord paralysis. The pressure around the extrathoracic airway is approximately atmospheric throughout the respiratory cycle, so during inspiration the transmural pressure favors narrowing of the extrathoracic airway. The flow-volume loop shows flattening of the inspiratory limb.

**Variable intrathoracic obstruction** occurs with tracheomalacia of the intrathoracic airway or tumors. During restful breathing, the pressure surrounding the intrathoracic large airway approximates pleural pressure. During forced expiration, the pleural pressure may become positive relative to the airway pressure, and the transmural pressure favors narrowing of the intrathoracic airway. The flow-volume loop shows flattening of the expiratory limb.

**Fixed upper airway obstruction** occurs



**FIGURE 3.** Bronchoscopic image showing the vocal cords (arrows A and C) and severe subglottic stenosis (arrow B).

with tracheal stenosis or goiter. Both limbs of the flow-volume loop are flattened.

### ■ TRACHEAL STENOSIS

Our patient undergoes flexible bronchoscopy, which demonstrates severe subglottic stenosis (FIGURE 3). In this case, the cause is likely to be either Wegener granulomatosis or the previous traumatic intubation.

### ■ REFERENCES

1. Sanchez O, Garcia G, Hamid A, et al. Pulmonary hypertension complicating systemic diseases other than connective tissue diseases [in French]. *Presse Med* 2003; 32:800–803.
2. Schwarz MI, Brown KK. Small vessel vasculitis of the lung. *Thorax* 2000; 55:502–510.
3. Aboussouan LS, Stoller JK. Diagnosis and management of upper airway obstruction. *Clin Chest Med* 1994; 15:35–53.
4. Aozasa K, Ohsawa M, Tajima K, et al. Nation-wide study of lethal mid-line granuloma in Japan: frequencies of Wegener's granulomatosis, polymorphic reticulosis, malignant lymphoma and other related conditions. *Int J Cancer* 1989; 44:63–66.
5. Langford CA, Sneller MC, Hallahan CW, et al. Clinical features and therapeutic management of subglottic stenosis in patients with Wegener's granulomatosis. *Arthritis Rheum* 1996; 39:1754–1760.
6. Alaani A, Hogg RP, Drake Lee AB. Wegener's granulomatosis and subglottic stenosis: management of the airway. *J Laryngol Otol* 2004; 118:786–790.
7. Kastanos N, Estopa Miro R, Marin Perez A, Xaubet Mir A, Agusti-Vidal A. Laryngotracheal injury due to endotracheal intubation: incidence, evolution, and predisposing factors. A prospective long-term study. *Crit Care Med* 1983; 11:362–367.

**ADDRESS:** Omar A. Minai, MD, Department of Pulmonary, Allergy, and Critical Care Medicine, G62, Cleveland Clinic, 9500 Euclid Ave, Cleveland OH 44195; e-mail minai@ccf.org.