



**EMIL HAYEK, MD**

Assistant professor of Medicine, Northeastern Ohio  
Universities College of Medicine, Rootstown, OH;  
cardiologist, Akron General Medical Center,  
Akron, OH

# An elderly woman with severe anemia

**A** 77-YEAR-OLD WOMAN IS ADMITTED to the hospital with complaints of severe generalized weakness and dizziness. She denies having abdominal pain, rectal bleeding, melena, or hematemesis.

Her medical history includes hypertension, hypothyroidism, total abdominal hysterectomy, and cholecystectomy. Her current medications include triamterene and hydrochlorothiazide (Dyazide, Maxzide), conjugated estrogen (Premarin), levothyroxine (Synthroid), and alendronate (Fosamax).

She looks pale but otherwise seems well. She is afebrile, and her blood pressure is 154/83 mm Hg without orthostatic change, pulse 82 per minute, and oxygen saturation 100% on room air.

The physical examination is normal, no masses are palpable on rectal examination, and her stool is guaiac-negative.

Routine laboratory studies are performed (TABLE 1). A peripheral blood smear shows hypochromic, microcytic erythrocytes.

## ■ DIFFERENTIAL DIAGNOSIS

**1** Which is the most likely cause of her anemia?

- Anemia of chronic disease
- Iron-deficiency anemia
- Myelodysplastic syndrome
- Beta-thalassemia

Iron deficiency is the most common cause of a microcytic anemia in postmenopausal women.

Anemia of chronic disease (eg, in chronic inflammation, infection, and malignancy) can cause hypochromic, microcytic anemia due to iron-deficient erythropoiesis; however, this anemia usually is normochromic and normocytic.

Patients with myelodysplastic syndromes, which encompass a heterogeneous group of clonal disorders of myeloid hematopoiesis, may present with anemia, but this is usually macrocytic and is often accompanied by other cytopenias.

**Her peripheral blood smear shows hypochromic, microcytic erythrocytes**

**TABLE 1**

### The patient's laboratory study results

TEST	PATIENT'S VALUES	NORMAL RANGE
White blood cell count	5.0 × 10 <sup>9</sup> /L	4.4–9.7
Hemoglobin concentration	7.7 g/dL	11.7–14.7
Hematocrit	28.3%	34.7–43.3
Mean corpuscular volume	62 fL	82–97
Red cell distribution width	21%	12–15
Platelet count	345 × 10 <sup>9</sup> /L	150–370
Sodium	143 mmol/L	136–145
Potassium	3.6 mmol/L	3.5–5.3
Chloride	105 mmol/L	100–111
Blood urea nitrogen concentration	18 mg/dL	3–25
Serum creatinine concentration	1.3 mg/dL	0.7–1.5
Thyrotropin	3.84 μIU/L	0.4–4.5

Beta-thalassemia trait, an inherited heterozygous defect in beta-globin chain synthesis, also causes microcytic anemia; however, it would be unusual for this diagnosis to be made initially in a 77-year-old woman.

### ■ CONFIRMING IRON DEFICIENCY

Acting on the presumed diagnosis of iron-deficiency anemia, her physicians measure her serum ferritin concentration, which is 4 ng/mL (normal postmenopausal range 18–300). It should be noted that, due to age-specific variation in serum ferritin levels in normal individuals, the diagnostic sensitivity for iron-deficiency in the elderly is improved by using a higher cutoff of 45 to 60 ng/mL.

**2** Which study is required to confirm iron-deficiency anemia?

- Bone marrow examination
- Serum iron
- Total iron-binding capacity
- No further testing is necessary

The finding of a markedly reduced serum ferritin concentration (< 10 ng/mL) confirms severe iron deficiency with a specificity of 99%, thus obviating the need for a confirmatory bone marrow examination. Total iron-binding capacity, an indirect measure of the serum transferrin concentration, is usually elevated with iron deficiency but is a less specific finding than a low serum ferritin. In the presence of both iron-deficiency anemia and anemia of chronic disease, serum iron is decreased; serum ferritin is normal to increased in anemia of chronic disease.<sup>1</sup> Therefore, the finding of microcytic anemia with severely reduced serum ferritin confirms the diagnosis of iron-deficiency anemia, and no further testing is necessary.<sup>2</sup>

### ■ FINDING THE SOURCE OF BLEEDING

**3** Which test should be performed next in this patient?

- Capsule endoscopy
- Tagged red blood cell radionuclide imaging
- Colonoscopy and esophagogastroduodenoscopy (EGD)
- Air-contrast barium enema x-ray

The most common cause of iron-deficiency anemia in a postmenopausal woman without an obvious source of blood loss is occult gastrointestinal bleeding. The differential diagnosis includes colorectal carcinoma, peptic ulcer disease, inflammatory bowel disease, and vascular ectasia. While iron deficiency is the most common nutritional deficiency worldwide, there is nothing in our patient's history to suggest inadequate nutritional intake or impaired iron absorption, such as may occur with atrophic gastritis. Colonoscopy and EGD offer the highest probability of detecting the source of occult gastrointestinal bleeding, and they should be the first tests performed.<sup>3</sup>

Capsule endoscopy, which is performed by having the patient swallow a wireless, pill-sized video camera, is used to investigate the small bowel, which cannot be visualized by EGD or colonoscopy. Small-bowel sources of blood loss are less common, so capsule endoscopy should be considered if colonoscopy and EGD do not reveal the cause of the blood loss.

Tagged red blood cell radionuclide imaging is used to determine the site of active rapid bleeding exceeding 0.1 to 0.4 mL per minute.

Air-contrast barium enema examination can identify mass lesions, but endoscopy is more sensitive for detecting mucosal lesions or vascular ectasia and would therefore be preferred.

### ■ ENDOSCOPIC STUDIES ARE NORMAL, NEW SYMPTOMS DEVELOP

The patient undergoes colonoscopy and EGD, which are normal. Given our patient's profound symptoms of severe anemia and given her advanced age, she receives a transfusion of packed red blood cells and is started on oral ferrous sulfate. One month later she develops palpitations, watery diarrhea, and episodic facial flushing.

**4** Which laboratory study should be ordered next?

- 24-hour urine collection for metanephrines and vanilmandelic acid
- 24-hour urine collection for 5-hydroxyindoleacetic acid (5-HIAA)
- Serum serotonin
- Carbohydrate antigen 125 (CA-125)
- Serum serotonin plus 24-hour urine collection for 5-HIAA

**Colonoscopy and EGD could not find the source of her occult bleeding**

TABLE 2

### Differential diagnosis of facial flushing

#### Diseases

Autonomic epilepsy  
 Carcinoid syndrome  
 Mastocytosis  
 Medullary thyroid carcinoma  
 Migraine  
 Pheochromocytoma  
 Polycythemia  
 Renal cell carcinoma

#### Medications

Nicotinic acid  
 Phosphodiesterase-5 inhibitors  
 (sildenafil, tadalafil, vardenafil)

#### Foods

Alcohol  
 Monosodium glutamate  
 Sodium nitrite (cured meats)  
 Sulfites

#### Other

Anxiety  
 Idiopathic  
 Menopause  
 Rosacea

### In carcinoid syndrome, serotonin causes flushing, diarrhea, and bronchospasm

The differential diagnosis of facial flushing is broad and includes anxiety, medical conditions such as mastocytosis, and the use of alcohol and various medications (TABLE 2).<sup>4-6</sup> If the flushing is due to foods, alcohol, or medications, a careful history will usually point to the cause. Flushing reactions with alcohol are more common in the Asian population due to alcohol dehydrogenase deficiency, and it also occurs with the concomitant use of drugs such as disulfiram (Antabuse), chlorpropamide (Diabinese), paroxetine (Paxil, Pexeva), and metronidazole (eg, Flagyl). The presence of associated systemic symptoms, such as in our patient, should prompt a search for a more serious underlying condition, such as a neuroendocrine tumor, eg, pheochromocytoma or carcinoid tumor.

The best next step in our patient is to measure the 24-hour urinary excretion of the serotonin metabolite 5-HIAA. Elevated urinary excretion of 5-HIAA is a specific marker for carcinoid tumor, particularly in a patient

with hepatic metastases. Given the inherent difficulties of accurate 24-hour urine collection and preservation, especially in the elderly, it is useful to concomitantly measure other biochemical markers in the blood. Elevated plasma, whole blood, and platelet serotonin and fasting plasma 5-HIAA are biomarkers highly specific and modestly sensitive for carcinoid tumor, especially in patients with liver metastasis. More recently, plasma chromogranin A has been found to be a sensitive biochemical marker for both diagnosis and monitoring of disease progression.

The studies in this patient showed markedly elevated urinary 5-HIAA (118.7 mg/24 hours, normal < 6.0 mg/24 hours) and serum serotonin (2,233 pmol/mL, normal < 180 pmol/mL), confirming the diagnosis of malignant carcinoid syndrome.

An important note: ingestion of amine-rich foods such as bananas may cause elevated urinary 5-HIAA levels in the absence of carcinoid tumor (ie, a false-positive result) and should be avoided for at least 12 hours before measurement. Accordingly, our patient avoided amine-rich foods for 12 hours before the urine collection.

Urinary excretion of metanephrines and vanilmandelic acid is elevated in patients with pheochromocytoma, a rare tumor usually of adrenal origin that causes episodic palpitations, hypertension, headache, and sweating due to release of catecholamines—an unlikely diagnosis in our patient, who lacks this constellation of symptoms.

CA-125 is a tumor antigen associated with ovarian carcinoma. Ovarian carcinoma would be highly unlikely in this patient, however, given her history of total abdominal hysterectomy.

### ■ CARCINOID SYNDROME

Carcinoid tumors are rare, with an incidence of 1 to 2 per 100,000 in the United States, but are the most common neuroendocrine tumor.<sup>7</sup> They are most often found in the gastrointestinal tract (74% of cases), particularly in the small bowel and appendix, but they are also found in the bronchopulmonary system (25% of cases).<sup>7</sup>

Carcinoid tumors in the bowel can pre-

sent with iron-deficiency anemia, while gastric carcinoid may cause pernicious anemia.<sup>8</sup> Carcinoid tumors may present with localized symptoms (eg, intestinal obstruction) or systemic symptoms (as in carcinoid syndrome), or they may be found incidentally during surgery, endoscopy, or autopsy.

## ■ FINDING THE TUMORS

**5** Which is the best next step in the evaluation of this patient?

- Exploratory laparotomy
- Contrast-enhanced abdominal computed tomography (CT)
- Radiolabeled somatostatin receptor scintigraphy
- Hepatic venous sampling

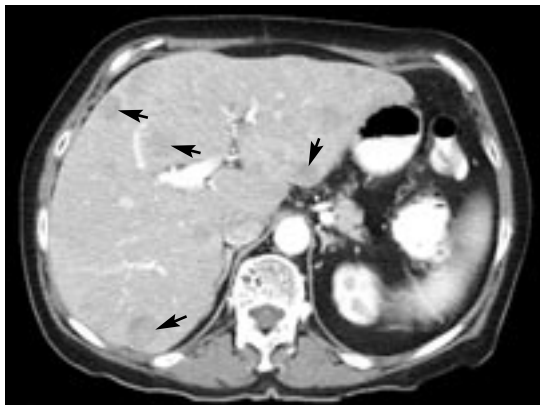Our patient presented with carcinoid syndrome, and hepatic metastases are likely on the basis of her symptoms of flushing, diarrhea, and palpitations.

Carcinoid syndrome, characterized by episodic flushing (usually of the face and chest), secretory diarrhea, and bronchospasm, occurs when high serum concentrations of vasoactive substances released by the tumor, most notably serotonin, reach the systemic circulation. Most of the time this occurs when there is distant metastasis, usually to the liver. Polypeptide hormones, particularly those responsible for bradykinin production, are implicated in flushing symptoms and bronchoconstriction, while increased intestinal levels of tachykinins have been associated with secretory diarrhea.

Imaging studies such as CT, magnetic resonance imaging (MRI), positron emission tomography, and radionuclide studies can determine the location and the stage of the tumor before surgical exploration. Contrast-enhanced abdominal CT would be the noninvasive study most likely to yield the diagnosis.

Exploratory laparotomy should not be the initial diagnostic test: a noninvasive imaging test should be done first to locate the primary tumor and detect distant metastasis, thus determining the appropriate medical and surgical therapy.

Since most carcinoid tumors express somatostatin receptors, scintigraphy with radiolabeled



**FIGURE 1.** Abdominal computed tomography with contrast shows numerous low-density hepatic nodules (arrows) in both lobes due to metastatic carcinoid tumor.

octreotide, a somatostatin analogue, offers excellent sensitivity and is superior to scintigraphy with meta-iodobenzylguanidine (MIBG) iodine 131. However, while scintigraphy is an excellent choice for tumors that cannot be located by CT or MRI, it is also technically more difficult to perform than CT and is not as accurate as CT at determining the size of the tumor and its proximity to surrounding structures, and therefore it should not be the initial study.

Hepatic venous sampling is an invasive method and should be reserved for the rare and particularly challenging diagnosis of carcinoid syndrome when the tumor is not visualized by less invasive means such as CT or MRI.

## Imaging results

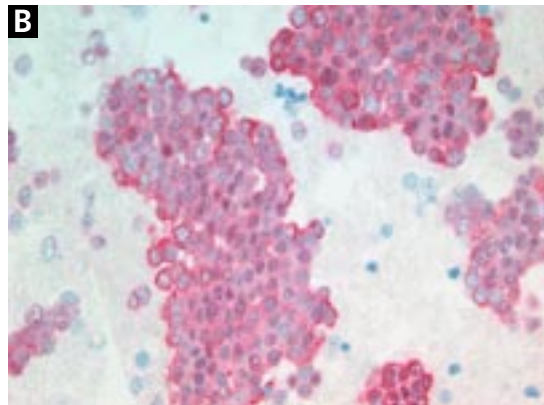
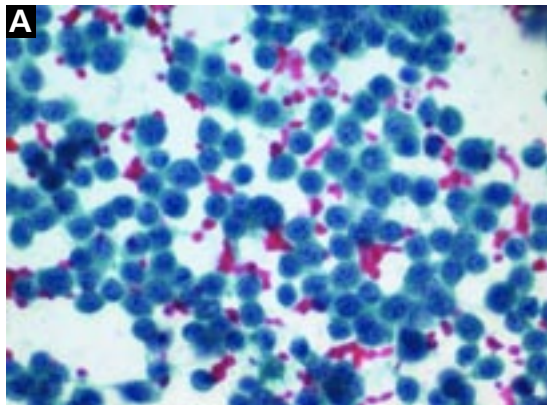
Abdominal CT in our patient reveals a 3-by-2-cm mass at the root of the small-bowel mesentery, as well as numerous low-density nodules consistent with metastases in both hepatic lobes (FIGURE 1). Fine-needle aspiration of one of the hepatic masses shows monotonous sheets of cells that stain strongly for both chromogranin and neuron-specific enolase, products of neuroendocrine tumors (FIGURE 2).

## ■ WHAT ARE HER TREATMENT OPTIONS?

**6** Which treatment option should be considered at this point?

- Surgical resection of the small bowel tumor and the hepatic metastases
- Chemoembolization of the hepatic artery

**Carcinoid syndrome can indicate distant metastases, eg, to the liver**



**FIGURE 2.** Fine-needle aspiration of a hepatic mass shows monotonous round carcinoid cells (A) that stain strongly for chromogranin (B).

- Monthly injections of octreotide
- MIBG iodine 131
- All of the above except for surgical resection of the tumor and metastases

All of the above are options except for surgical resection. Surgical resection is an option when metastatic disease is confined to a single hepatic lobe, particularly with a solitary tumor; however, most patients have unresectable disease at the time of diagnosis, and surgery, even when feasible, is rarely curative.

The goals of treatment in this patient should be cytoreduction and control of symptoms that are due to excess circulating neuropeptides.

By inhibiting neuropeptide release, somatostatin analogues such as octreotide, usually given as a monthly injection, offer symptomatic improvement in most patients.<sup>9</sup> However, octreotide has not been shown to prolong survival or to have any impact on hepatic tumor burden.

Systemic chemotherapy is of limited value due to poor response rates and systemic toxicity.

Hepatic tumor cytoreduction has been achieved by surgical approaches such as intraoperative cryoablation and radiofrequency ablation, as well as by catheter-based techniques. Targeted therapy either with hepatic artery embolization or chemoembolization has been used successfully to diminish symptoms and tumor burden in patients with unresectable disease.<sup>10</sup>

About 70% of carcinoid tumors have receptors for MIBG, a biogenic amine precursor analogue that is taken up by neuroendocrine tumors. Targeted radiation therapy with MIBG iodine 131 in receptor-positive patients has been shown to relieve symptoms.<sup>11</sup>

#### ■ MORE SYMPTOMS DEVELOP

The patient is treated with octreotide but develops refractory symptoms of flushing and diarrhea with an associated increase in size of the hepatic metastases. She undergoes hepatic artery chemoembolization of the largest hepatic tumor, which improves her symptoms.

Three months later she develops increasing dyspnea and lower-extremity edema. The physical examination shows elevated jugular venous pressure with a prominent *v* wave, clear lung fields, loud pansystolic murmur along the lower left-sternal border accentuated with inspiration, loud P<sub>2</sub>, severe bilateral leg edema, and ascites.

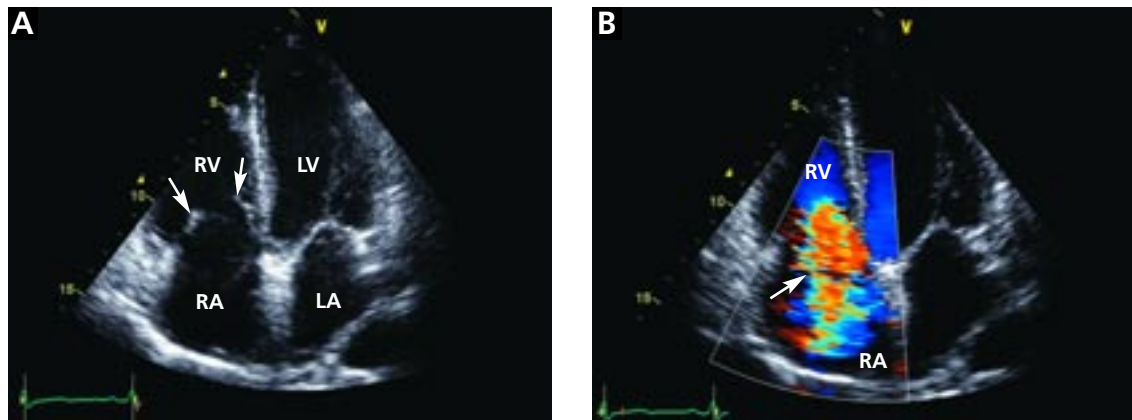
**7** Which is the most likely explanation for these symptoms?

- Thrombosis of the inferior vena cava
- Carcinoid crisis
- Carcinoid heart disease
- Cardiac metastasis

The findings of our patient's cardiac examination are consistent with severe tricuspid insufficiency and resultant right-sided heart failure, which is characteristic of carcinoid heart disease,

**With carcinoid tumors, octreotide helps with symptoms but does not prolong survival**





**FIGURE 3.** Two-dimensional echocardiography (at end-diastole with closed mitral valve) shows marked retraction of the tricuspid leaflets and failure of coaptation (A, arrows). This resulted in severe tricuspid insufficiency, as seen on color Doppler imaging (B, arrow).

and which we confirmed in this patient with two-dimensional echocardiography (FIGURE 3).

Tumor extension into the inferior vena cava is most often associated with renal cell carcinoma. Carcinoid crisis is a rare, life-threatening, acute complication of surgical resection or chemotherapy characterized by hypotension, profound flushing, confusion, and hyperthermia. Most cardiac tumors are benign, and the most common metastatic tumors to the heart are bronchogenic carcinoma, breast carcinoma, melanoma, and lymphoma.

#### ■ CARCINOID SYNDROME AND THE HEART

Cardiac involvement occurs in as many as 66% of patients with carcinoid syndrome and, as the tumor-released vasoactive substances are inactivated by the lung, primarily affects the right heart. Left heart involvement is less frequent but may occur with patent foramen ovale, bronchopulmonary carcinoid, or very high levels of circulating serotonin from extensive hepatic metastases.

The most common finding is endocardial fibrosis of the tricuspid and pulmonary valves leading to tricuspid insufficiency, tricuspid stenosis, and pulmonic stenosis due to thickening, retraction, and fixation of the leaflets (FIGURE 3). The degree of tricuspid insufficiency is usually much more severe than the degree of stenosis and leads to dilation and dysfunction of the right ventricle.

Serotonin appears to play a significant role in the development of the typical endo-

cardial fibrotic plaques, as evidenced by the correlation of urinary 5-HIAA levels and the development of carcinoid heart disease.<sup>12</sup>

#### 8 How should this patient be managed?

- Diuretics to control symptoms
- Beta-antagonists
- Tricuspid valve replacement
- Tricuspid valve annuloplasty

Loop diuretics along with salt and water restriction treat the symptoms of right-sided heart failure and would be appropriate in our patient. Beta-antagonists may worsen right-sided heart failure in patients with right ventricular dysfunction. Tricuspid valve replacement, often with pulmonary valvuloplasty, may be considered in some younger patients, particularly when carcinoid heart involvement is diagnosed early, as the cause of death in these patients is more often right-sided heart failure rather than progressive malignancy.<sup>13</sup> Tricuspid valve replacement is preferred over annuloplasty repair due to marked retraction of the valve leaflets.


The patient develops progressive right-sided heart failure and dies 2 years after the diagnosis of carcinoid syndrome.

#### ■ TAKE-HOME POINTS

- Carcinoid tumors are rare neuroendocrine tumors usually localized to the gastrointestinal tract.

**Carcinoid heart disease is usually confined to the right heart**



- Carcinoid syndrome occurs with metastatic disease to the liver and results in symptoms of flushing, diarrhea, and bronchospasm due to circulating serotonin and neuropeptides.
- Most patients with carcinoid syndrome have unresectable disease, and management is confined to symptom relief and cytoreduction.
- Carcinoid heart disease, usually confined to the right heart, is commonly seen with carcinoid syndrome and may lead to right-sided congestive heart failure. 

## ■ REFERENCES

1. **Guyatt GH, Oxman AD, Ali M, Willan A, McIlroy W, Patterson C.** Laboratory diagnosis of iron-deficiency anemia: an overview. *J Gen Intern Med* 1992; 7:145–153.
2. **Weiss G, Goodnough LT.** Anemia of chronic disease. *N Engl J Med* 2005; 352:1011–1023.
3. **Rockey DC.** Occult gastrointestinal bleeding. *N Engl J Med* 1999; 341:38–46.
4. **Tur E, Ryatt KS, Maibach HI.** Idiopathic recalcitrant facial flushing syndrome. *Dermatologica* 1990; 181:5–7.
5. **Friedman BS, Germano P, Miletti J, Metcalfe DD.** A clinicopathologic study of ten patients with recurrent unexplained flushing. *J Allergy Clin Immunol* 1994; 93(1 Pt 1):53–60.
6. **Aldrich LB, Moattari AR, Vinik AI.** Distinguishing features of idiopathic flushing and carcinoid syndrome. *Arch Intern Med* 1988; 148:2614–2618.
7. **Modlin IM, Sandor A.** An analysis of 8305 cases of carcinoid tumors. *Cancer* 1997; 79:813–829.
8. **Coppola A, Izzo G, Mastrolorenzo L, et al.** A 69-year-old woman with persistent iron deficiency anemia. *Ann Hematol* 2004; 83:474–476.
9. **Arnold R, Trautmann ME, Creutzfeldt W, et al.** Somatostatin analogue octreotide and inhibition of tumour growth in metastatic endocrine gastroenteropancreatic tumours. *Gut* 1996; 38:430–438.
10. **Gupta S, Johnson MM, Murthy R, et al.** Hepatic arterial embolization and chemoembolization for the treatment of patients with metastatic neuroendocrine tumors: variables affecting response rates and survival. *Cancer* 2005; 104:1590–1602.
11. **Taal BG, Hoefnagel CA, Valdes Olmos RA, Boot H, Beijnen JH.** Palliative effect of metaiodobenzylguanidine in metastatic carcinoid tumors. *J Clin Oncol* 1996; 14:1829–1838.
12. **Moller JE, Connolly HM, Rubin J, Seward JB, Modesto K, Pellikka PA.** Factors associated with progression of carcinoid heart disease. *N Engl J Med* 2003; 348:1005–1015.
13. **McDonald ML, Nagorney DM, Connolly HM, Nishimura RA, Schaff HV.** Carcinoid heart disease and carcinoid syndrome: successful surgical treatment. *Ann Thorac Surg* 1999; 67:537–539.

.....  
**ADDRESS:** Emil Hayek, MD, Akron General Medical Center, 400 Wabash Avenue, Akron, OH 44307; e-mail hayeke@adelphia.net.