

**SACHIN GOEL, MD**Department of Internal Medicine,
Cleveland Clinic**DANIEL G. CLAIR, MD**Chairman, Department of Vascular Surgery,
Cleveland Clinic**TERESA L. CARMAN, MD**Department of Cardiovascular Medicine,
and director, fellowship program, Section
of Vascular Medicine, Cleveland Clinic**A SELF-TEST
ON A
CLINICAL
CASE**
.....

An 18-year-old with effort-related arm swelling

AN 18-YEAR-OLD RIGHT-HANDED MAN presents to the emergency department with acute-onset swelling of the entire left arm. He is a high school senior with a baseball scholarship. He says he was fine until the night before. He says he has not recently changed his usual activities, except for raking leaves earlier that day.

On examination, his heart sounds are normal, with a regular rate and rhythm and no murmurs, and his chest is clear bilaterally on auscultation. His left arm is swollen, but no dilated veins are noted. His blood pressure is 160/70 mm Hg in his right arm and 150/70 mm Hg in his left arm.

■ WHICH IMAGING TEST?

1 Which is the most appropriate initial diagnostic test to evaluate this patient's arm swelling?

- ☐ Venography
- ☐ Magnetic resonance imaging (MRI)
- ☐ Duplex venous ultrasonography
- ☐ Plain radiography of the humerus
- ☐ Computed tomography (CT)

Given this patient's young age and the absence of trauma, a fracture is unlikely. His presentation with sudden onset of swelling in the arm raises the suspicion of deep vein thrombosis (DVT). In fact, from 4% to 10% of all cases of DVT occur in the arms.^{1,2}

To prevent serious complications, upper extremity DVT needs to be treated promptly. Pulmonary embolism occurs in up to one third of patients with upper extremity DVT.³

Another serious complication is post-thrombotic syndrome, a chronic condition

that develops in 20% to 50% of patients after DVT and is characterized by chronic pain, swelling, heaviness, and skin changes in the affected limb.⁴⁻⁷ In the first study of its kind in patients with upper extremity DVT, Kahn et al⁸ showed that almost half the patients developed postthrombotic syndrome, that it was associated with significant functional disability and impaired quality of life, and that for many patients it required a change in lifestyle.⁸

Duplex venous ultrasonography is the best choice for initial diagnostic imaging because it is noninvasive and is highly sensitive and specific for peripheral—in this case jugular, distal subclavian, and axillary—DVT.³ One shortcoming is that acoustic shadowing from the clavicle may limit the view of a short segment of the subclavian vein, resulting in a false-negative study,⁹ so if DVT is strongly suspected on clinical grounds but the venous ultrasonography study is negative, further investigation is warranted.

Our patient underwent duplex venous ultrasonography, which revealed a left subclavian DVT.

Venography provides excellent definition of the venous anatomy but has drawbacks: it requires venous cannulation and a contrast agent, it is contraindicated during pregnancy, and it carries a small risk of venous thromboembolism.

MRI is an accurate and noninvasive method for detecting thrombosis and defining the venous anatomy, and its findings correlate well with those of venography.¹⁰ It can be used in situations where contrast venography is contraindicated.

Chest radiography. Up to 3% of patients with obstruction of the thoracic outlet have

**Up to 10%
of DVTs
occur in the
arms**

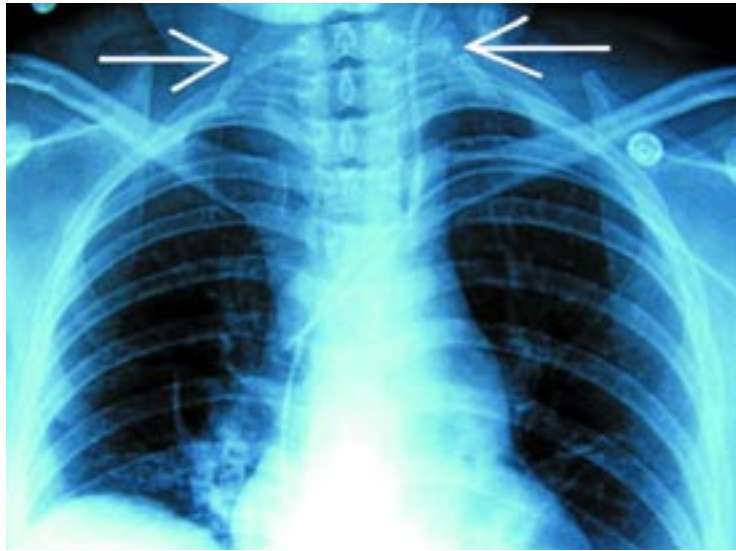


FIGURE 1. Chest radiograph in another patient shows anomalous ribs arising from the 7th cervical vertebra, a common cause of thoracic outlet obstruction.

an anomalous rib arising from the last cervical vertebra (cervical rib) (**FIGURE 1**). These patients may present with arterial compromise, neurogenic symptoms, or, as in this case, subclavian vein thrombosis. However, although chest radiography can show a cervical rib, it cannot show thrombosis and therefore is not the initial study to obtain. Our patient's chest radiograph was normal.

CT of the chest would be appropriate if a mass in the thorax were suspected, especially in the apex of the lung (Pancoast tumor), since such a mass can cause vascular complications. However, this is less likely in an otherwise healthy 18-year-old, so CT would not be the initial diagnostic imaging test. CT with contrast enhancement may also help identify thrombosis of the subclavian vein; however, it is not the initial test of choice. In addition, it can show evidence of chronic occlusive disease in the form of collateral venous drainage, but our patient seems to have an acute problem, not a chronic one.

■ CAUSES OF UPPER EXTREMITY DVT

2 Which is the strongest risk factor for upper extremity DVT?

- ☐ Cancer
- ☐ Central venous catheter
- ☐ Thrombophilia
- ☐ Idiopathic, effort-induced

The risk factors for upper extremity DVT differ from those for lower extremity DVT.

Central venous catheters. About 40% of patients who develop upper extremity DVT have a central venous catheter in place,¹¹ and a recent study² found these devices to be the strongest risk factor for upper extremity DVT. Other risk factors include cancer, pacemakers, inherited thrombophilias, oral contraceptive use, immobilization of the arm, and family history.^{2,12–14}

The incidence of DVT of the upper extremities is on the rise, in part due to the growing use of indwelling devices such as catheters, pacemakers, and defibrillators, and in part due to refinements in duplex imaging, which improve our ability to identify thrombi in the upper extremities.

Thrombophilias. Data are limited as to the prevalence of hypercoagulable states in upper extremity DVT. One study¹⁵ documented lupus anticoagulants or anticardiolipin antibodies as the most common type of thrombophilia in patients with upper extremity DVT, found in 27% of patients. Factor V Leiden is the most common hereditary thrombophilia in patients with upper extremity DVT, occurring in 25.3% of patients in one study.¹⁶

Cancer. The association of malignancy with venous thrombosis is well known, and patients may present with spontaneous upper extremity DVT. However, most of these cases are in patients with an indwelling catheter.

Idiopathic. Our patient is otherwise healthy, has no indwelling catheter, and has no other symptoms. He has no family history of cancer or of a hypercoagulable disorder. He later undergoes testing for thrombophilia, but that is negative. This leaves idiopathic or effort-induced thrombosis.

■ EFFORT-INDUCED THROMBOSIS

Spontaneous or effort-induced DVT as a cause of pain and swelling in the arm was first postulated by Paget in England in 1875. Von Schroetter in Germany in 1884 was the first to relate the syndrome to thrombosis of axillary and subclavian veins.^{17,18} Subsequent investigations have revealed that, although the event seems to be spontaneous, it is actually the

Up to 1/3 of patients with upper extremity DVTs develop pulmonary embolism

TABLE 1

Provocative thoracic outlet maneuvers**ADSON TEST**

Maneuver: With the arm dependent, the patient is asked to hyperextend the neck, turn the chin towards the affected side, and take a deep breath

Positive test: Loss or decrease of radial pulsation, or bruit in the costoclavicular space, or reproduction of neurologic symptoms

Mechanism: Narrowing of the space between the scalenus anticus and medius, resulting in neurovascular compression

ELEVATED ARM STRESS TEST (EAST) OR ROOS TEST

Maneuver: Patient is asked to repeatedly clench and unclench the fists while keeping the arms abducted and externally rotated (palms upwards and forwards). Elbows are braced slightly behind the frontal plane

Positive test: Inability to carry on for 3 minutes due to forearm fatigue or cramping

Mechanism: Abduction and external rotation of the shoulder narrows the thoracic outlet and compromises subclavian artery blood flow, with repeated clenching movements adding stress

HALSTED (COSTOCLAVICULAR) TEST

Maneuver: Patient is instructed to take an exaggerated military position with shoulders thrust backward and downward

Positive test: Loss or decrease of radial pulsation, or bruit in the costoclavicular space, or reproduction of neurologic symptoms

Mechanism: Narrowing of the space between first rib and the clavicle, resulting in neurovascular compression

WRIGHT (HYPERABDUCTION) TEST

Maneuver: Patient is asked to raise hands above the head with the elbows somewhat flexed and extending out laterally from the body

Positive test: Loss or decrease of radial pulsation or reproduction of symptoms

Mechanism: Constriction of the neurovascular bundle in the thoracic outlet beneath the insertion of the pectoralis minor tendon into the coracoid due to prolonged hyperabduction of shoulders

VIJAYSADAN V, ZIMMERMAN AM, PAJARO RE. PAGET-SCHROETTER SYNDROME IN THE YOUNG AND ACTIVE. J AM BOARD FAM PRACT 2005; 18:314–319. REPRODUCED BY PERMISSION OF THE AMERICAN BOARD OF FAMILY MEDICINE.

result of an underlying chronic venous compressive anomaly at the thoracic outlet.^{19–21}

Effort-induced DVT, also termed Paget-Schroetter syndrome, occurs in young, active persons and is characterized by spontaneous or effort-related upper extremity DVT, usually in the dominant arm, after repetitive physical activity involving the upper extremity, such as rowing, weight lifting, baseball pitching, playing volleyball, tennis, and swimming.²² Some have hypothesized that, with venous hypertension caused by compression at the thoracic outlet, heavy exertion—especially with arms in the overhead position—causes microtrauma to the vessel intima, activation of the

coagulation cascade, and thrombosis.

The thoracic outlet can be compressed by adjoining bones such as a cervical rib or the clavicle, by fibrous or ligamentous bands, or by muscular structures such as hypertrophied anterior scalene or subclavius muscles.^{23,24}

The prevalence of hypercoagulable states in patients with Paget-Schroetter syndrome is unknown. Case reports have been published,^{25,26} but the role of testing for thrombophilia in these patients remains unclear. Thrombophilia testing should be done in these patients only if the results would alter management, such as in antiphospholipid antibody syndrome.

Most patients with Paget-Schroetter syndrome present with a dull aching pain in the shoulder or arm associated with arm swelling, usually within 24 hours of the strenuous activity. Physical examination usually reveals edema and erythema. Occasionally, subcutaneous collateral veins over the upper arm and chest may appear dilated.

Corroborative clinical evidence for arterial compression or neurologic involvement can come from differences in blood pressure in the two arms and from tests for thoracic outlet syndrome, such as the Adson test, the costoclavicular maneuver, supraclavicular pressure, and the elevated arm stress test (TABLE 1). It should be noted that up to 10% of the normal population—ie, people with no pathologic abnormality—may have a positive thoracic outlet compression test.

Urschel and Razzuk¹⁷ evaluated 312 extremities in 294 patients with Paget-Schroetter syndrome and found that all of the extremities tested positive on at least one of the maneuvers listed in TABLE 1. In a study by Kunkel and Machleder,¹⁸ 84% of patients with Paget-Schroetter syndrome had a positive maneuver.

In our patient, an elevated arm stress test is positive, with palmar pallor bilaterally and forearm fatigue. On performing the other maneuvers described in TABLE 1, he develops a bruit in the region of the right subclavian artery without loss of the radial pulse, but with loss of the left radial pulse on abduction without a bruit in the region of the left subclavian artery, suggesting coexisting arterial compression. On the basis of his clinical history and presentation, he is diagnosed with effort-related DVT consistent with Paget-Schroetter syndrome.

■ MANAGING PAGET-SCHROETTER SYNDROME

3 How should we manage this patient with subclavian DVT?

- ☐ Catheter-directed thrombolysis
- ☐ Warfarin (Coumadin)
- ☐ Resection of the first rib
- ☐ All of the above
- ☐ None of the above

The management options for Paget-Schroetter syndrome include thrombolytic

therapy, anticoagulants, surgery, or a combination of these. Improved understanding of the pathophysiology of Paget-Schroetter syndrome and advances in local catheter-based delivery of thrombolytic agents have led to the development of treatment algorithms designed to relieve venous obstruction, correct the underlying anatomic abnormality at the thoracic outlet, and prevent recurrence of thrombosis. The “best” approach is not known, however, because no prospective randomized controlled trial has compared the various management strategies.

Thrombolytic therapy of acute DVT leads to higher rates of vein patency and a lower incidence of postthrombotic syndrome than with standard anticoagulation therapy alone.^{27–29}

One of the most widely accepted algorithms was initially proposed by Kunkel and Machleder in 1989.¹⁸ Their approach combined early local catheter-based thrombolytic therapy, a 3-month period of anticoagulation with warfarin, and delayed surgical decompression of the thoracic outlet with transaxillary resection of the first rib. A series of 50 patients, one of the largest studies of Paget-Schroetter syndrome, showed that this multimodal strategy was safe and effective.²²

Surgery: Sooner vs later?

Many patients with Paget-Schroetter syndrome are young and healthy and are at lower risk for bleeding complications from surgery. This has led some to advocate surgical decompression immediately or soon after thrombolysis.^{30,31} However, early surgical decompression could result in hemorrhagic and technical complications: thrombosis of any vein can be accompanied by an intense inflammatory reaction, and rib resection in this setting could present the opportunity for vein injury and hemorrhage.

In 2001, Angle et al³² published a review of 18 patients, 9 of whom underwent early surgery after thrombolysis and 9 of whom underwent the traditional thrombolysis and delayed surgery (ie, usually 3 months later). Performing surgery sooner (immediately after thrombolysis) rather than later did not increase the rates of perioperative complications or death.

Risk factors for upper extremity DVT differ from those for lower extremity DVT

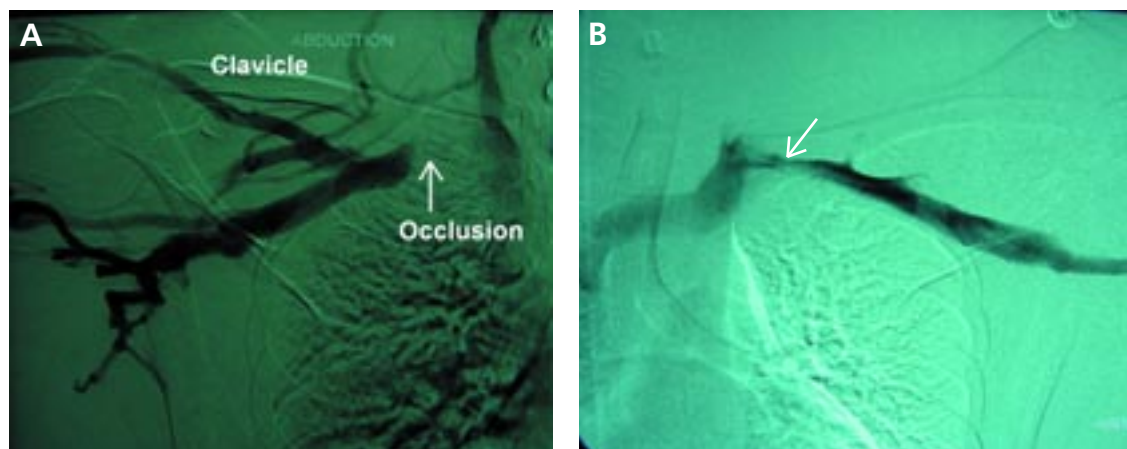


FIGURE 2. Follow-up venography in our patient after successful thrombolysis of a deep vein thrombosis of the left subclavian vein, anticoagulant therapy, and resection of the left first rib. In image A, the arrow indicates stenosis of 20% to 30% still present on the left on abduction of the arm, while image B shows severe occlusion on abduction of the right arm.

However, not every patient can or agrees to undergo surgical decompression of the thoracic outlet during the initial hospital visit, and it is appropriate to recommend thrombolysis followed by anticoagulation until arrangements for surgery can be made, as in our patient (see below).

Which surgical approach?

The thoracic outlet can be decompressed by resecting either the first rib or the mid-portion of the clavicle. The most common approach is resection of the first rib through either a transaxillary or supraclavicular approach.

Both approaches have their proponents. A recent audit in the United Kingdom showed that 58% of surgeons preferred resecting the first rib, and that 55% of those preferred the transaxillary approach vs 28% who preferred the supraclavicular.³³

Patients with isolated obstruction of the subclavian vein have a more favorable outcome than do those with combined neurologic and venous pathologic features.³⁴

■ CASE CONTINUED

Our patient was admitted to the hospital and underwent successful catheter-directed thrombolysis with recombinant tissue-type plasminogen activator (r-TPA). He then received heparin as a bridge to warfarin therapy. Anticoagulation was continued, and he

was referred to a vascular surgeon for consideration of resection of his left first rib. Transaxillary left first rib resection was performed 4 weeks later. He recovered from the surgery without complications.

Four weeks after surgery he underwent bilateral upper extremity venography, which revealed patent basilic, brachial, axillary, subclavian, and brachycephalic veins on the left side. On abduction of the left arm, a small (20%–30%) stenosis was noted at the level of the subclavian vein (FIGURE 2), but this did not appear to be hemodynamically significant. On the right side, the brachial, basilic, axillary, and subclavian veins were patent. But on abduction of the right arm, severe compression of the right axillary subclavian venous system was noted, which suggested thoracic outlet syndrome on the right side (FIGURE 2). The patient subsequently underwent successful transaxillary resection of the right first rib.

Comments

Bilateral venous abnormalities are not unusual in patients with effort-related upper extremity DVT. In fact, they have been reported in more than 50% of patients.^{22,30} In these patients, the contralateral thoracic outlet has usually been managed conservatively. However, in patients with significant venous compression with continued repetitive trauma, as occurs in certain athletic activities (eg, throwing a baseball), prophylactic thoracic outlet decompression, as per-

Bilateral venous abnormalities are not unusual in patients with effort-related upper extremity DVT

formed in this patient, can be considered.^{18,35}

Paget-Schroetter syndrome or effort-related upper extremity DVT needs to be diagnosed and treated early to prevent long-term complications such as the postthrombotic syn-

drome, which may cause significant disability. Management is multimodal, with immediate catheter-directed thrombolysis followed by anticoagulation until decompression surgery can be performed. ■

REFERENCES

- Hill SL, Berry RE. Subclavian vein thrombosis: a continuing challenge. *Surgery* 1990; 108:1-9.
- Joffe HV, Kucher N, Tapson VF, Goldhaber SZ. Upper-extremity deep vein thrombosis: a prospective registry of 592 patients. *Circulation* 2004; 110:1605-1611.
- Prandoni P, Polistena P, Bernardi E, et al. Upper-extremity deep vein thrombosis. Risk factors, diagnosis, and complications. *Arch Intern Med* 1997; 157:57-62.
- Elman EE, Kahn SR. The post-thrombotic syndrome after upper extremity deep venous thrombosis in adults: a systematic review. *Thromb Res* 2006; 117:609-614.
- Prandoni P, Lensing AW, Cogo A, et al. The long-term clinical course of acute deep venous thrombosis. *Ann Intern Med* 1996; 125:1-7.
- Kahn SR, Ginsberg JS. Relationship between deep venous thrombosis and the postthrombotic syndrome. *Arch Intern Med* 2004; 164:17-26.
- Schulman S, Lindmarker P, Holmstrom M, et al. Post-thrombotic syndrome, recurrence, and death 10 years after the first episode of venous thromboembolism treated with warfarin for 6 weeks or 6 months. *J Thromb Haemost* 2006; 4:734-742.
- Kahn SR, Elman EA, Bornais C, Blostein M, Wells PS. Post-thrombotic syndrome, functional disability and quality of life after upper extremity deep venous thrombosis in adults. *Thromb Haemost* 2005; 93:499-502.
- Haire WD, Lynch TG, Lund GB, Lieberman RP, Edney JA. Limitations of magnetic resonance imaging and ultrasound-directed (duplex) scanning in the diagnosis of subclavian vein thrombosis. *J Vasc Surg* 1991; 13:391-397.
- Hartnell GG, Hughes LA, Finn JP, Longmaid HE 3rd. Magnetic resonance angiography of the central chest veins. A new gold standard? *Chest* 1995; 107:1053-1057.
- Horattas MC, Wright DJ, Fenton AH, et al. Changing concepts of deep venous thrombosis of the upper extremity—report of a series and review of the literature. *Surgery* 1988; 104:561-567.
- Blom JW, Doggen CJ, Osanto S, Rosendaal FR. Old and new risk factors for upper extremity deep venous thrombosis. *J Thromb Haemost* 2005; 3:2471-2478.
- Martinelli I, Battaglioli T, Bucciarelli P, Passamonti SM, Mannucci PM. Risk factors and recurrence rate of primary deep vein thrombosis of the upper extremities. *Circulation* 2004; 110:566-570.
- Heit JA, O'Fallon WM, Petterson TM, et al. Relative impact of risk factors for deep vein thrombosis and pulmonary embolism: a population-based study. *Arch Intern Med* 2002; 162:1245-1248.
- Leebeek FW, Stadhouders NA, van Stein D, Gomez-Garcia EB, Kappers-Klunne MC. Hypercoagulability states in upper-extremity deep venous thrombosis. *Am J Hematol* 2001; 67:15-19.
- Bombeli T, Basic A, Fehr J. Prevalence of hereditary thrombophilia in patients with thrombosis in different venous systems. *Am J Hematol* 2002; 70:126-132.
- Urschel HC Jr, Razzuk MA. Paget-Schroetter syndrome: what is the best management? *Ann Thorac Surg* 2000; 69:1663-1668.
- Kunkel JM, Machleder HI. Treatment of Paget-Schroetter syndrome. A staged, multidisciplinary approach. *Arch Surg* 1989; 124:1153-1157.
- McCleery RS, Kesterson JE, Kirtley JA, Love RB. Subclavius and anterior scalene muscle compression as a cause of intermittent obstruction of the subclavian vein. *Ann Surg* 1951; 133:588-602.
- Daskalakis E, Bouhoutos J. Subclavian and axillary vein compression of musculoskeletal origin. *Br J Surg* 1980; 67:573-576.
- Aziz S, Straehley CJ, Whelan TJ, Jr. Effort-related axillosubclavian vein thrombosis. A new theory of pathogenesis and a plea for direct surgical intervention. *Am J Surg* 1986; 152:57-61.
- Machleder HI. Evaluation of a new treatment strategy for Paget-Schroetter syndrome: spontaneous thrombosis of the axillary-subclavian vein. *J Vasc Surg* 1993; 17:305-315.
- Zell L, Kindermann W, Marschall F, Scheffler P, Gross J, Buchter A. Paget-Schroetter syndrome in sports activities—case study and literature review. *Angiology* 2001; 52:337-342.
- Makhoul RG, Machleder HI. Developmental anomalies at the thoracic outlet: an analysis of 200 consecutive cases. *J Vasc Surg* 1992; 16:534-542.
- Sayinalp N, Ozcebe OI, Kirazli S, Dogan R, Dundar SV, Gurgey A. Paget-Schroetter syndrome associated with FV:Q506 and prothrombin 20210A—a case report. *Angiology* 1999; 50:689-692.
- Kreienberg PB, Chang BB, Darling RC 3rd, et al. Long-term results in patients treated with thrombolysis, thoracic inlet decompression, and subclavian vein stenting for Paget-Schroetter syndrome. *J Vasc Surg* 2001; 33:5100-5105.
- Elliot MS, Immelman EJ, Jeffery P, et al. A comparative randomized trial of heparin versus streptokinase in the treatment of acute proximal venous thrombosis: an interim report of a prospective trial. *Br J Surg* 1979; 66:838-843.
- Turpie AG, Levine MN, Hirsh J, et al. Tissue plasminogen activator (rt-PA) vs heparin in deep vein thrombosis. Results of a randomized trial. *Chest* 1990; 97:1725-1755.
- Comerota AJ, Thom RC, Mathias SD, Haughton S, Mewissen M. Catheter-directed thrombolysis for iliofemoral deep venous thrombosis improves health-related quality of life. *J Vasc Surg* 2000; 32:130-137.
- Azaki A, McElhinney DB, Thompson RW, Raven RB, Messina LM, Stoney RJ. Surgical management of subclavian-vein effort thrombosis as a result of thoracic outlet compression. *J Vasc Surg* 1998; 28:777-786.
- Urschel HC Jr, Razzuk MA. Improved management of the Paget-Schroetter syndrome secondary to thoracic outlet compression. *Ann Thorac Surg* 1991; 52:1217-1221.
- Angle N, Gelabert HA, Farooq MM, et al. Safety and efficacy of early surgical decompression of the thoracic outlet for Paget-Schroetter syndrome. *Ann Vasc Surg* 2001; 15:37-42.
- Khan SN, Stansby G. Current management of Paget-Schroetter syndrome in the UK. *Ann R Coll Surg Engl* 2004; 86:29-34.
- Divi V, Proctor MC, Axelrod DA, Greenfield LJ. Thoracic outlet decompression for subclavian vein thrombosis: experience in 71 patients. *Arch Surg* 2005; 140:54-57.
- Thompson RW, Schneider PA, Nelken NA, Skioldebrand CG, Stoney RJ. Circumferential venolysis and paraclavicular thoracic outlet decompression for "effort thrombosis" of the subclavian vein. *J Vasc Surg* 1992; 16:723-732.

ADDRESS: Teresa L. Carman, MD, Section of Vascular Medicine, S60, Cleveland Clinic, 9500 Euclid Avenue, Cleveland, OH 44145; e-mail carmant@ccf.org.