

JEFFREY M. GOLDBERG, MD

Head, Section of Reproductive Endocrinology and Infertility, Department of Obstetrics and Gynecology, Cleveland Clinic

TOMMASO FALCONE, MD

Chairman, Department of Obstetrics and Gynecology, Cleveland Clinic

MARJAN ATTARAN, MD

Section of Reproductive Endocrinology and Infertility, Department of Obstetrics and Gynecology, Cleveland Clinic

In vitro fertilization update

■ ABSTRACT

Success rates with in vitro fertilization (IVF) continue to improve as we gain insight into optimal culture conditions for gametes and embryos. New procedures such as in vitro egg maturation, preimplantation genetic testing, single embryo transfer, and oocyte freezing hold the promise of reducing the cost, inconvenience, and risks of IVF, as well as preserving future fertility. We provide an overview of the current and experimental assisted reproductive technology techniques.

■ KEY POINTS

Oocytes are retrieved by transvaginal ultrasound-guided needle aspiration following the induction of multiple follicular maturation by a regimen of gonadotropin stimulation.

IVF is still associated with considerable cost and inconvenience as well as multiple gestations.

The number of embryos transferred to the uterus should be limited to reduce the number of high-order multiple pregnancies (triplets or more). Ultimately, single embryo transfers will eliminate multiple pregnancies altogether while maintaining high pregnancy rates.

THE SCIENCE OF IN VITRO FERTILIZATION (IVF) has improved considerably in the more than 25 years since the first “test-tube” baby was born. Originally indicated for women with tubal factor infertility, IVF has become the treatment of last resort for all causes of infertility when conventional therapy fails or is unlikely to be successful. A greater understanding of the nutritional and environmental requirements of oocytes and embryos led to advances in culture conditions that have improved IVF pregnancy rates.

Unfortunately, IVF remains expensive and inconvenient and leads to an unacceptably high percentage of multiple pregnancies. Ideally, we will eventually be able to select a single embryo to transfer to the uterus, without compromising pregnancy rates currently achieved with more than one embryo per transfer, to ensure the birth of a healthy singleton.

■ BASIC STEPS OF IN VITRO FERTILIZATION

IVF was originally performed with the single dominant ovarian follicle produced during a spontaneous menstrual cycle. This was very inefficient and pregnancy rates were dismal. Consequently, “superovulation” protocols using parenteral gonadotropins to induce maturation of multiple follicles were soon adopted worldwide. The retrieval of multiple oocytes allows for the selection of the embryos best to transfer. In addition, any supernumerary embryos remaining after uterine transfer may be cryopreserved for future embryo transfers without the need for another IVF cycle.

Superovulation for multiple follicle maturation

There are several basic superovulation protocols. A standard protocol involves three basic steps:

- A gonadotropin-releasing hormone (GnRH) analog such as leuprolide acetate (Lupron) is given as a daily subcutaneous injection at a dose of 0.5 mg starting around cycle day 21 to induce pituitary suppression. The purpose is to prevent a spontaneous luteinizing hormone (LH) surge, leading to ovulation prior to oocyte retrieval. Pituitary suppression usually requires 10 to 14 days, after which the dose is reduced to 0.25 mg daily.
- Recombinant follicle-stimulating hormone (FSH) is given after pituitary suppression at a usual starting dose between 150 and 300 IU. It is given as a daily subcutaneous injection for another 10 to 14 days. Subsequent doses and the frequency of follicular monitoring with transvaginal ultrasonography and concomitant serum estradiol levels are individualized based on the ovarian response.
- Human chorionic gonadotropin is given subcutaneously once the lead follicles have achieved a mature size of 18 to 20 mm. The human chorionic gonadotropin simulates the endogenous LH surge to bring about final oocyte maturation.

Newer GnRH antagonists have the advantages of more rapid pituitary suppression and fewer injections compared with GnRH agonists, but they are more expensive and may be associated with lower pregnancy rates.¹ There are conflicting data regarding the relative benefits of the older urinary gonadotropin products (containing FSH and LH) vs the newer recombinant FSH drugs. Some have advocated adding the recently available recombinant LH to pure FSH protocols, though the data to support this are weak.

Oocyte retrieval

For the first decade of IVF, mature oocytes were recovered laparoscopically. Since then, oocyte retrieval has been performed by transvaginal ultrasound-guided needle aspiration, under conscious sedation, 34 to 38 hours after the delivery of human chorionic gonadotropin. The follicular fluid obtained is immediately examined by the embryologist for an oocyte with its accompanying cumulus mass of granulosa cells. From one to more than 40 oocytes may be retrieved, though 10 to 20 is typical. The oocytes are then placed in a cul-

ture medium based on human fallopian tubal fluid and incubated at 37°C. From 100,000 to 200,000 sperm are then added to the oocytes in a small drop of media, or by direct injection of a single sperm using intracytoplasmic injection as explained below. Fertilization can be documented 12 to 20 hours later by the presence of a male and female pronucleus in approximately 65% of the oocytes. Lower fertilization rates suggest intrinsic defects in one or both of the gametes.

Embryo transfer

The embryos with the best morphologic grade are selected for transfer. However, experience with preimplantation genetic testing (PGD) has taught us that good morphology does not predict the absence of aneuploidy and vice versa.² Embryos are usually transferred into the uterus 3 days after retrieval and fertilization via a small flexible transcervical catheter. The implantation of the embryo into the endometrium about 4 days later is the step that limits the IVF success rates. A strategy to improve embryo implantation is to transfer the embryos 5 days after oocyte retrieval at the blastocyst stage. In theory, the best embryos are able to continue dividing in extended culture, whereas the poorer quality embryos undergo arrested development. Unfortunately, most studies have been unable to confirm a significant improvement over the standard day 3 transfer.³⁻⁵

In an effort to reduce high-order multiple pregnancies (triplets or more), the American Society of Reproductive Medicine guidelines recommend that no more than two embryos should be transferred in women under age 35, three embryos in women 35 to 37, four in women 38 to 40, and five in women over 40, although fewer embryos may be transferred.⁶ Ultimately, the goal is to transfer a single embryo to avoid twin gestations as well. This has already been legislated in several countries.

Exogenous progesterone is given after embryo transfer to optimize endometrial receptivity for embryo implantation. It may be given by intramuscular injections (50 or 100 mg) or various vaginal formulations during the luteal phase and continued until gestational week 8 or 10.

A series of subcutaneous injections of human chorionic gonadotropin can also be used to increase endogenous progesterone pro-

The goal of IVF is to transfer a single embryo to avoid multiple gestations

duction, but this is associated with an increased risk of ovarian hyperstimulation syndrome.

Risk of ovarian hyperstimulation syndrome

Ovarian hyperstimulation syndrome is potentially life-threatening and poses the greatest medical risk to women undergoing IVF. Mild ovarian hyperstimulation syndrome is common, with lower abdominal discomfort beginning about 1 week after oocyte retrieval because of the presence of multiple functional cysts in the superovulated ovaries. The cysts resolve spontaneously, usually within 2 weeks, though they may last for several weeks if the patient is pregnant.

The underlying pathogenesis of moderate to severe ovarian hyperstimulation syndrome is increased vascular permeability leading to the loss of intravascular fluid into the third space. This can result in electrolyte imbalances, prerenal oliguria and renal failure, tense ascites with respiratory compromise, and, rarely, adult respiratory distress syndrome and hypercoagulability with thromboembolism.

Ovarian hyperstimulation syndrome is self-limited, and treatment is supportive until spontaneous resolution occurs, usually by 8 to 10 weeks of gestation.

■ SUCCESS OF IVF DECLINES WITH MATERNAL AGE

The Society for Assisted Reproductive Technology (SART) and the US Centers for Disease Control and Prevention (CDC) compile data from all the IVF programs in the United States on a yearly basis and provide information on each center, as well as cumulative summary statistics on the outcomes of all IVF cycles. The most current data available are from 2004.⁷ During this year 94,242 cycles were initiated, resulting in 36,760 live births. The pregnancy rate per cycle was 33.7%, while the live birth rate per cycle was 27.7%. Of the ongoing pregnancies, 60.3% were singleton, 28.6% were twins, and 4.9% were triplets or more. The age of the woman was the factor most predictive of success, with a rapid drop each year after 40 (FIGURE 1).⁷ The indication for IVF did not affect success rates except in cases of diminished ovarian reserve, which compro-

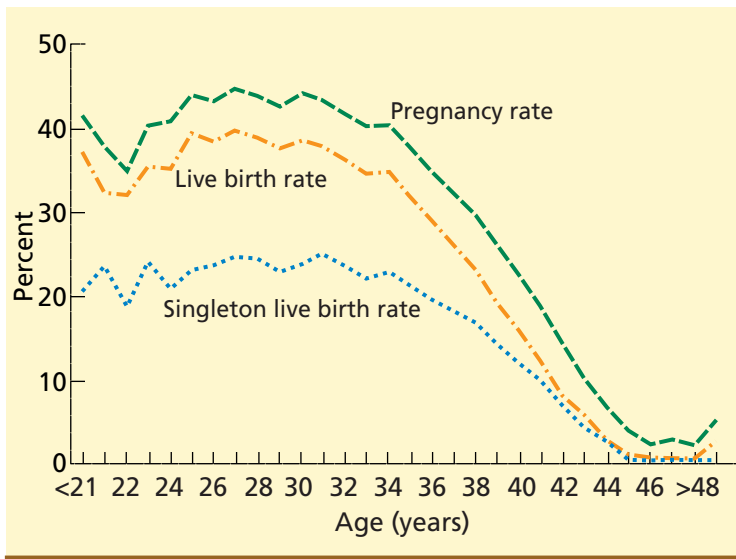


FIGURE 1. Rates of pregnancy, live birth, and singleton live birth for women of different ages who underwent an assisted reproductive technology procedure using fresh nondonor eggs or embryos in 2004.

FROM THE US CENTERS FOR DISEASE CONTROL AND PREVENTION

mises oocyte quality, or a uterine factor, which compromises uterine receptivity.

■ ADVANCES IN ASSISTED REPRODUCTIVE TECHNOLOGY

A number of standard and experimental techniques have been applied to improve the success rates and reduce the risks of IVF. These include intracytoplasmic sperm injection (ICSI), assisted embryo hatching, preimplantation genetic diagnosis (PGD), in vitro maturation (IVM), and oocyte and ovarian tissue cryopreservation. These techniques involve the micromanipulation of the gametes and embryos under an inverted microscope at 400 × magnification with joystick-type controllers. The motion is scaled and transferred to holding pipettes and injection needles. The embryologist must work quickly to return the gametes and embryos back to optimal culture conditions in the incubator.

■ ICSI OVERCOMES MALE FACTOR INFERTILITY

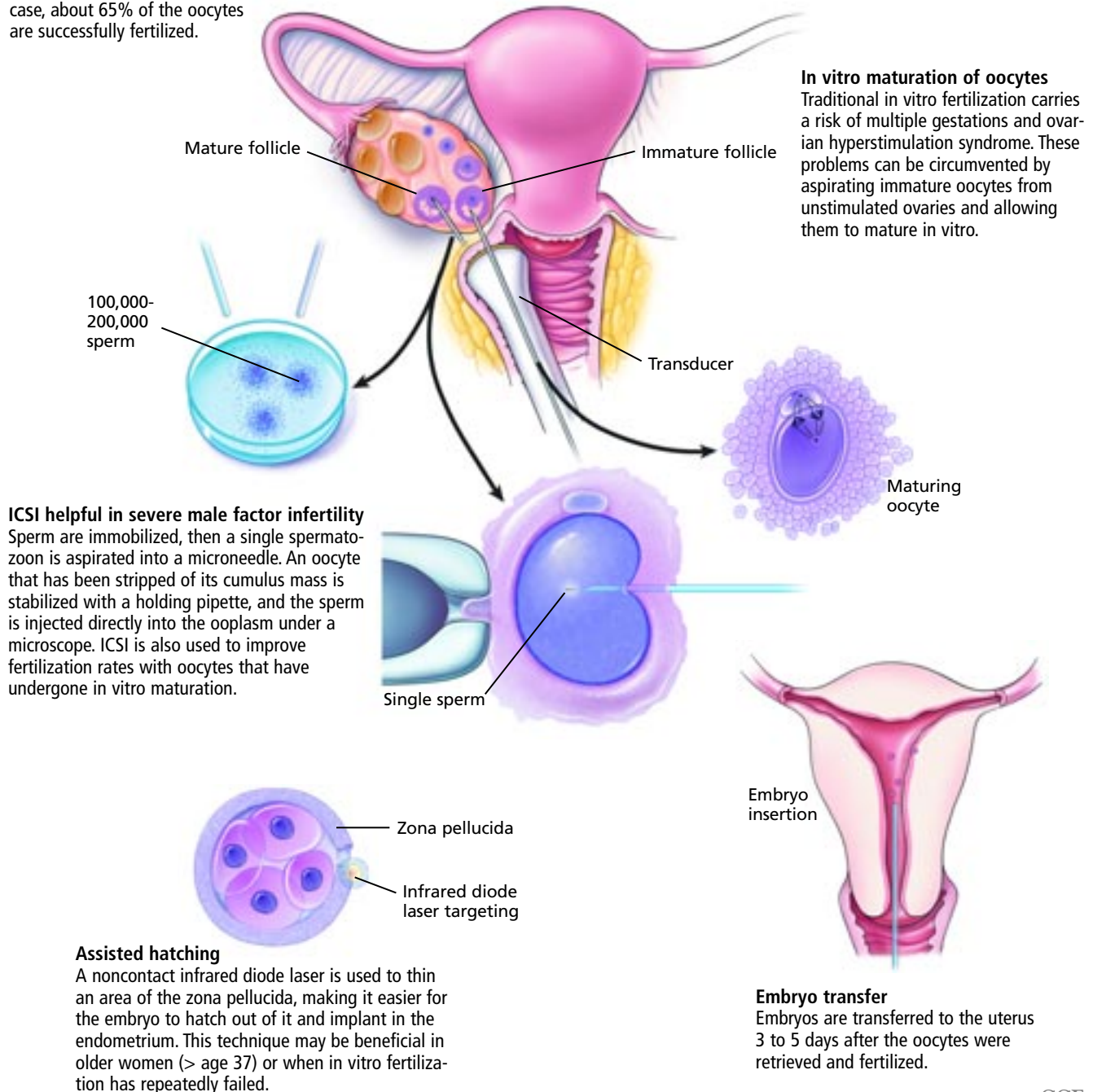
More than any other ancillary technique, ICSI revolutionized assisted reproductive

■ The 'ART' and science of in vitro fertilization

Assisted reproductive technology, or ART, has made it possible for many infertile couples to conceive. A variety of ancillary techniques are currently used to improve pregnancy rates of in vitro fertilization.

Standard in vitro fertilization

After ovarian stimulation with gonadotropins, the oocytes are retrieved by needle aspiration guided by transvaginal ultrasonography. They are transferred to a culture medium and mixed with 100,000 to 200,000 sperm, or each oocyte is inseminated directly with a single sperm – a technique called intracytoplasmic sperm injection (ICSI). In either case, about 65% of the oocytes are successfully fertilized.



Medical Illustrator: Joseph Pangrace CCF ©2007

FIGURE 2

technology. Prior to the first successful ICSI pregnancy in 1992,⁸ favorable outcomes with conventional IVF were uncommon in couples with severe male factor infertility. Artificial insemination or IVF with donor sperm was the only option for these couples. ICSI restores fertilization and pregnancy rates to those comparable to conventional IVF with no male factor infertility, even when semen specimens are of extremely poor quality.⁹

ICSI involves immobilizing sperm in polyvinylpyrrolidone, or by crushing the tail, then aspirating a single spermatozoon into a microneedle. The oocyte, which has been stripped of its surrounding cumulus mass, is stabilized with a holding pipette, and the sperm is injected directly into the ooplasm. Fertilization is documented the following morning by the presence of the male and female pronuclei.

Besides abnormal semen analyses, ICSI is also indicated for obstructive azoospermia due either to congenital absence of the vas deferens or to prior vasectomy, and nonobstructive azoospermia from sperm maturation arrest. In these cases, sperm are obtained by microsurgical or percutaneous aspiration from the epididymis or the testes. This typically yields extremely low numbers of poor quality sperm. ICSI is also used when there are antisperm antibodies in the semen and when there has been poor fertilization in a previous IVF cycle despite a normal semen analysis. It also improves fertilization rates with oocytes matured in vitro or cryopreserved. It is used in conjunction with PGD to prevent DNA contamination from sperm that may still be adherent to the oocyte after fertilization by conventional IVF, as will be discussed below.

Although rarely successful, "rescue ICSI" of unfertilized eggs following conventional IVF may be attempted.¹⁰ ICSI has not been shown to improve success rates over conventional IVF in the absence of male factor infertility.^{11,12}

Therefore, there is no benefit to justify the potential risks with ICSI in those cases without a clear indication for its use.

Concerns about ICSI

Concerns have been raised about ICSI, as it bypasses any mechanism for natural selection

and may thus allow for fertilization with a genetically abnormal sperm or oocyte. Further, the procedure may disrupt the meiotic spindle apparatus, which may lead to an aneuploid embryo.¹³ There does not seem to be a procedure-dependent increase in spontaneous abortions, birth defects, low birth weight, or prematurity.^{11,13}

In 10% to 15% of cases, extremely poor semen analysis or obstructive azoospermia is due to genetic anomalies in the man, especially microdeletions of long arm of the Y chromosome. ICSI in these cases will result in all of the male offspring having the same genetic defect.⁹ None of these children have reached puberty yet, but it can be assumed that they too will be infertile. It has even been estimated that if half of all azoospermic men underwent ICSI, the incidence of male infertility would double within seven generations.¹⁴

There is also some evidence that ICSI induces de novo chromosomal anomalies, usually involving the sex chromosomes, but the phenotypes are normal.^{11,15} Birth defects following ICSI are not significantly different than those after conventional IVF.¹⁶ Mental development is also normal in children conceived through ICSI.¹⁷

■ ASSISTED HATCHING MAY HELP IN SOME CASES

The zona pellucida is an acellular matrix of glycoproteins, carbohydrates, and zona-specific proteins surrounding the oocyte and early embryo. It plays a role in sperm binding and fertilization, prevents polyspermic fertilization, and aids compaction of the blastomeres. Once the embryo reaches the blastocyst stage, it produces proteases to dissolve the zona in order to hatch out of it and implant in the endometrium. Increased zona thickness or hardening may impair the ability of the blastocyst to hatch, thus preventing pregnancy.

Several techniques have been developed to assist hatching and improve IVF pregnancy rates. The original method reported in 1990 was partial zona dissection, performed by creating a small slit in the zona with a microneedle.¹⁸ Next to be tried was thinning an area of the zona with acid Tyrode's solution delivered

**ICSI
revolutionized
the field of
assisted
reproductive
technology**

through a microneedle.¹⁹

We are currently using a noncontact infrared diode laser, which is safer, easier to use, and more precise, and yields more consistent results.^{20,21} The latest innovation is a piezo-electric micromanipulator to deliver vibratory pulses to facilitate hatching.²²

Success rates are difficult to assess as the studies to date are small and of poor quality.²³ A recent meta-analysis found no significant improvement in the live birth rate when assisted hatching was applied in unselected patients. However, clinical pregnancy rates were higher in women who had already had more than one unsuccessful IVF cycle. Women over age 37 also appeared to benefit from assisted hatching, but the study lacked statistical significance because of small sample size.²³ Several studies suggested that the risk of monozygotic twinning may be higher following assisted hatching.²⁰

Not for routine use. The Practice Committee of the American Society for Reproductive Medicine and others have advised against the routine use of assisted hatching for all patients. Its use should be limited to older women or to women who have had previous unsuccessful IVF attempts.^{20,23,24} It may also be considered when the zona pellucida is abnormally thick, when the embryo has been cryopreserved, and possibly when the woman has an elevated serum FSH level.²⁰

■ GENETIC TESTING OF THE EMBRYO BEFORE TRANSFER

PGD is indicated for couples at increased risk of spontaneous abortions or of having a child with a genetic anomaly. The most frequent cause of these is aneuploidy of the embryo. Risk factors for aneuploidy are advanced maternal age (over age 37), a chromosomal rearrangement such as a balanced translocation in one of the partners, and a history of recurrent miscarriage or multiple failed IVF attempts. PGD is also an option for couples with the potential to have a child with an autosomal or sex-linked disorder. More controversial uses of PGD are to choose the sex of the child or to select unaffected HLA-compatible embryos for the purpose of having a child and using the umbilical cord stem cells

to treat a sibling with an inherited metabolic disorder or malignancy.

The technique. Following fertilization by ICSI and thinning of the zona pellucida, as for assisted hatching, one or two blastomeres are aspirated from day 3 embryos using the micromanipulator. Fluorescence in-situ hybridization (FISH) is performed on the biopsied cells to detect chromosomal aneuploidy. The probes typically used are for chromosomes 13, 16, 18, 21, 22, X, and Y. Only genetically normal embryos are transferred on day 5.

The oocyte polar bodies can also be analyzed by FISH; this provides an earlier diagnosis and reduces the risk of damaging the embryo. However, it only yields information on the chromosomal status of the oocyte, not of the embryo.

How effective is it?

The rate of embryonic aneuploidy is 20% to 83% depending on the clinical situation.²⁵ Several studies have reported that PGD for aneuploidy screening significantly increased implantation and pregnancy rates and reduced miscarriage.²⁶ However, most of these studies lacked an appropriate control group.²⁷ A recent literature review failed to find consistent evidence of improved live birth rates.²⁸ Large, multicenter, randomized trials are under way to determine its effectiveness.

Single-gene disorders may be diagnosed with PGD by performing DNA amplification by the polymerase chain reaction (PCR) and hybridization to the probe for the allele of interest. Approximately 40 conditions resulting from autosomal dominant, recessive, and X-linked inheritance can be diagnosed with PGD. **TABLE 1** provides a partial list of these conditions.

Potential problems

PGD has several potential problems. While embryo damage is uncommon, many embryos may not develop well in culture and will be unsuitable for transfer on day 5. Therefore, PGD should be considered only if at least six to eight mature oocytes are available, to ensure that some normal embryos will be available to transfer in the event of low fertilization, arrested embryo growth in culture, and a high percentage of genetic abnormali-

Assisted hatching is limited to older women or women who have had unsuccessful IVF attempts

ties.²⁵ This excludes many older women who could otherwise benefit from PGD since they generally produce fewer oocytes.

FISH may give unreliable information due to hybridization failure, mosaicism, or the inability to see all of the chromosomes on the metaphase spread. It also does not assess all of the chromosomes. The misdiagnosis rate with FISH is 5% to 10%.^{25,27} PGD for single gene analysis could be erroneous due to allele dropout from faulty DNA amplification or DNA contamination from extraneous sperm or cumulus cells. The misdiagnosis rate with PCR is approximately 1% to 3%.²⁷

In the future, whole genome amplification for comparative genomic hybridization or DNA chip microassays may avoid these problems and also provide more detailed information.²⁹ Currently, most centers performing PGD recommend prenatal genetic testing by amniocentesis or chorionic villus biopsy to exclude potential errors of PGD.³⁰

■ IN VITRO MATURATION OF OOCYTES

Oocytes in the ovary are arrested in meiotic prophase I until ovulation. Endogenous or exogenous FSH stimulates the follicles to reach maturation. The process of “maturing” allows fertilization of the oocyte to occur. The final maturation process is under the influence of LH and results in the completion of meiosis I and formation of the first polar body. Meiosis II then proceeds to metaphase II, the stage at which the oocytes are typically retrieved for conventional IVF. With IVM, the maturation process occurs in vitro.

The rationale for IVM

Traditional IVF, using gonadotropins to stimulate multiple oocytes to mature, is associated with significant risks such as multiple pregnancy and ovarian hyperstimulation syndrome, as well as the inconvenience and cost of multiple injections and monitoring. These factors are offset by obtaining a large number of oocytes, and subsequently embryos, which is associated with overall improved pregnancy rates and the possibility to cryopreserve additional embryos.

Since most spontaneous cycles would typically produce only one mature oocyte, IVF with unstimulated cycles had been met with

TABLE 1

Preimplantation genetic testing for single-gene defects

Autosomal dominant

Huntington disease
Marfan syndrome
Myotonic dystrophy

Autosomal recessive

Achondroplasia
Beta-thalassemia
Congenital adrenal hyperplasia
Cystic fibrosis
Fanconi anemia
Gaucher disease
Neurofibromatosis
Phenylketonuria
Sickle cell anemia
Tay-Sachs disease

X-linked

Duchenne muscular dystrophy
Fragile X syndrome
Hemophilia

limited success. The aspiration of numerous immature oocytes from unstimulated ovaries followed by IVM will improve these results while reducing the cost of IVF by eliminating gonadotropins and the requisite monitoring. This would make it much more feasible for couples to attempt numerous IVF cycles with a greater cumulative success rate.

The technique of IVM is not a novel idea and has been attempted for decades.³¹ However, success rates have been very poor until recently because of the unavailability of appropriate culture media as the specific requirements of glucose, amino acids, and vitamins had been largely unknown. Effective IVM media are now commercially available.

Current indications for IVM

IVM is indicated for the following:

- Patients with polycystic ovary syndrome
- Poor responders or patients wishing to avoid gonadotropins
- Oocyte donors
- Cancer patients who wish to preserve their fertility.

Polycystic ovary syndrome is the most common indication for this procedure. Patients with polycystic ovary syndrome are at higher risk of ovarian hyperstimulation syndrome.³² IVM prior to surgery, chemotherapy, or radiotherapy for cancer treatment that may render the patient sterile is the most expeditious way to preserve sterility. Conventional IVF would delay needed treatment by several weeks, and the high levels of estrogen seen with gonadotropin stimulation may be detrimental to patients with estrogen-dependent cancers, such as breast cancer. The in vitro matured oocytes may be fertilized by IVF and the embryos cryopreserved until the patient is in remission. Alternatively, the matured oocytes may be cryopreserved for patients without a male partner. Hopefully, all cycles may one day be performed without gonadotropin stimulation.

The technique

The procedure is initiated with a transvaginal ultrasound around day 6 to 8 of a spontaneous cycle. Ideally, 20 or more follicles should be present between both ovaries, which is typical for most patients with polycystic ovary syndrome. If the number of antral follicles is sufficient, human chorionic gonadotropin is given and the oocytes are aspirated 36 hours later by transvaginal ultrasound-guided needle aspiration under conscious sedation, as for conventional IVF. The immature oocytes obtained are incubated for 24 to 48 hours. Approximately 80% of the oocytes mature.³¹ The granulosa cells surrounding the mature oocyte are then removed and a single sperm is injected by ICSI. Fertilization rates are similar to conventional IVF and the embryos are cultured for 3 to 5 days before transfer. The luteal phase is supported by exogenous estradiol and progesterone.

Pregnancy rates with IVM

Pregnancy rates with IVM reported from a few leading centers worldwide are approximately 38% per cycle in women under age 35 and 21% for women between the ages of 35 and 40.³¹ These results are comparable to conventional IVF.

■ OOCYTE AND OVARIAN TISSUE CRYOPRESERVATION: STILL EXPERIMENTAL

Another awaited breakthrough in assisted reproductive technology is oocyte freezing. Sperm and preimplantation embryos from the pronuclear to the blastocyst stage have been successfully cryopreserved for many years. However, freezing unfertilized oocytes has been a much greater challenge, primarily because of fragility of the meiotic spindle. This technique is still experimental, but preliminary pregnancy rates in the most experienced laboratories are approaching those with cryopreserved embryos.

Potential benefits

Once it can be performed more efficiently with higher success rates, oocyte cryopreservation offers several solutions and new opportunities. For example, couples undergoing IVF could cryopreserve their extra oocytes, eliminating the ethical dilemma of what to do with unclaimed cryopreserved embryos in the lab. This will also enable the creation of donor oocyte banks similar to sperm banks: currently, recipients must accept the donors as they become available, and their menstrual cycles must be synchronized so that the recipient's endometrium is at the appropriate stage to receive transferred embryos. With oocyte cryopreservation, couples will be able to select a donor from a catalog, donors will not have to travel to the lab, and no cycle synchronization will be needed. Also, the cryopreserved oocytes can be quarantined for several months following negative HIV screening to ensure that the donor was not in the process of seroconversion.

The combination of IVM and oocyte freezing would eliminate the need for superovulation prior to oocyte retrieval and should greatly increase the number of women willing to become oocyte donors. Additionally, women in their 20s could cryopreserve their own oocytes, fulfill their career goals, then undergo IVF in their 40s with their young oocytes without compromising their fertility. These techniques could also be applied to women facing the prospect of ovarian failure

Combining IVM and oocyte cryopreservation creates new possibilities

due to radiation or chemotherapy. Another option for these patients is to cryopreserve ovarian tissue.

The technique

Oocytes are cryopreserved by a vitrification process, which avoids cellular damage from ice crystal formation. Following exposure to cryoprotectants, the oocytes are plunged directly into liquid nitrogen rather than undergoing a progressive cooling method first. Ovarian tissue cryopreservation begins with laparoscopic removal of the ovary, in whole or part, before starting therapy for cancer. Small (1-to 2-mm³) ovarian cortical strips containing the oocytes are exposed to a cryoprotectant, then frozen. Once the patient is in remission the tissue is transplanted back into the host (autotransplantation) into the ovarian bed or another site such as the arm or abdomen. The patient then undergoes superovulation for IVF.³³

Limitations

The main limitation with this transplantation technique is loss of a significant percentage of the follicular population to ischemia, since the tissue is transplanted without a vascular supply.³⁴ Only a few pregnancies after autotransplantation have been reported in the world literature.^{35,36} Ovarian tissue cryopreservation must be considered experimental, and optimal conditions for freezing, thawing, and transplanting are still being worked out.³⁶ An important concern with this technique is the potential to reintroduce a cancer nidus back into a patient who is in remission. Some tumors have a high probability of metastasis to the ovary.

FUTURE DIRECTIONS, EXCITING POSSIBILITIES

The future course of IVF is already set in motion. Success rates continue to improve as we gain greater insight into optimal culture conditions for gametes and embryos. This, together with PGD to select genetically normal embryos, may allow for high pregnancy rates with single embryo transfer, eliminating multiple-gestation pregnancies. Routine use of IVM will greatly reduce the cost and inconvenience of IVF as well as the most significant medical risk to the patient, ovarian hyperstimulation syndrome. Ovarian tissue cryopreservation may be just an interim procedure until IVM with oocyte cryopreservation can be performed with high efficiency.

The combination of IVM and oocyte cryopreservation also opens up exciting new possibilities that may influence the way we reproduce. One example is the ability to create oocyte banks similar to sperm banks. Oocyte donors would have their immature oocytes retrieved without the need for gonadotropin superovulation. The oocytes would undergo IVM and cryopreservation. This would make a large pool of oocytes available for recipients to select from and would eliminate the need to synchronize the donor and recipients' cycles. Even more revolutionary is the possibility that women may have unstimulated oocyte retrieval, IVM and oocyte cryopreservation in their 20s, establish their careers, and return for IVF with their cryopreserved oocytes in their 40s, and have the same potential for fertility as when the oocytes were cryopreserved. ■

Ovarian tissue cryopreservation is still considered experimental

REFERENCES

1. Muasher SJ, Abdallah RT, Hubayter ZR. Optimal stimulation protocols for in vitro fertilization. *Fertil Steril* 2006; 86:267–273.
2. Munne S, Alikani M, Tomkin G, Grifo J, Cohen J. Embryo morphology, developmental rates, and maternal age are correlated with chromosomal abnormalities. *Fertil Steril* 1995; 64:382–391.
3. Kolibianakis EM, Devroey P. Blastocyst culture: facts and fiction. *Reprod Biomed Online* 2002; 5:285–293.
4. Bungum M, Bungum L, Hamaidan P, Yding Andersen C. Day 3 versus day 5 embryo transfer: a prospective randomized study. *Reprod Biomed Online* 2003; 7:98–104.
5. Rienzi L, Ubaldi F, Iacobelli M, et al. Day 3 embryo transfer with combined evaluation at the pronuclear and cleavage stages compares favourably with day 5 blastocyst transfer. *Hum Reprod* 2002; 17:1852–1855.
6. Practice Committee of the Society for Assisted Reproductive Technology and the American Society for Reproductive Medicine. Guidelines on the number of embryos transferred. *Fertil Steril* 2004; 82:773–774.
7. 2004 Assisted Reproductive Technology Success Rates. www.cdc.gov/ART/ART2004/index.htm.
8. Palermo GD, Devroey P, Van Steirteghem A. Pregnancies after intracytoplasmic sperm injection of single spermatozoon into an oocyte. *Lancet* 1992; 340:17–18.
9. Silber SJ, Repping S. Transmission of male infertility to future generations: lessons from the Y chromosome. *Hum Reprod Update* 2002; 8:217–229.
10. Yuzpe AA, Liu Z, Fluker MR. Rescue intracytoplasmic sperm injection (ICSI)-salvaging in vitro fertilization (IVF) cycles after total or near-total fertilization failure. *Fertil Steril* 2000; 73:1115.
11. Devroey P, Van Steirteghem A. A review of ten years experience of ICSI. *Hum Reprod Update* 2004; 10:19–28.
12. van Rumste MM, Evers JL, Farquhar CM. ICSI versus conventional tech-

- niques for oocyte insemination during IVF in patients with non-male factor subfertility: a Cochrane review. *Hum Reprod* 2004; 19:223–227.
13. **Retzlaff MG, Hornstein MD.** Is intracytoplasmic sperm injection safe? *Fertil Steril* 2003; 80:851–859.
 14. **Faddy MJ, Silber SJ, Gosden RG.** Intra-cytoplasmic sperm injection and infertility. *Nature Genet* 2001; 29:131.
 15. **Lewis S, Klonoff-Cohen H.** What factors affect intracytoplasmic sperm injection outcomes? *Obstet Gynecol Surv* 2005; 60:111–123.
 16. **Lie RT, Lyngstadass A, Orstavik KH, Bakkeiteig LS, Jacobsen G, Tanbo T.** Birth defects in children conceived by ICSI compared with children conceived by other IVF-methods; a meta-analysis. *Int J Epidemiol* 2005; 34:696–701.
 17. **Leslie GI.** Mental development of children conceived using intracytoplasmic sperm injection. The current evidence. *Minerva Ginecol* 2004; 56:247–257.
 18. **Cohen J, Elsner CW, Kort H, et al.** Impairment of hatching process following IVF in the human and improvement of implantation by assisted hatching using micromanipulation. *Hum Reprod* 1990; 5:7–13.
 19. **Cohen J, Alikani M, Trowbridge J, Rosenwaks Z.** Implantation enhancement by selective assisted hatching using zona drilling of human embryos with poor prognosis. *Hum Reprod* 1992; 7:685–691.
 20. **Germond M, Primi MP, Senn A.** Hatching: how to select the clinical indications. *Ann NY Acad Sci* 2004; 1034:145–151.
 21. **al-Nuaim LA, Jenkins JM.** Assisted hatching in assisted reproduction. *Br J Obstet Gynaecol* 2002; 109:856–862.
 22. **Nakayama T, Fujiwara H, Yamada S, Tastumi K, Honda T, Fujii S.** Clinical application of a new assisted hatching method using a piezo-micromanipulator for morphologically low-quality embryos in poor-prognosis infertile patients. *Fertil Steril* 1999; 71:1014–1018.
 23. **Edirisinghe WR, Ahnonkitpanit V, Promviengchai S, et al.** A study failing to determine significant benefits from assisted hatching: patients selected for advanced age, zonal thickness of embryos, and previous failed attempts. *J Assist Reprod Genet* 1999; 16:294–301.
 24. **Practice Committee of the American Society for Reproductive Medicine.** The role of assisted hatching in in vitro fertilization: a review of the literature. *Fertil Sterility* 2004; 82 (suppl 1):S164–165.
 25. **Pehlivan T, Rubio C, Rodrigo L, Remohi J, Pellicer A, Simon C.** Preimplantation genetic diagnosis by fluorescence in situ hybridization: clinical possibilities and pitfalls. *J Soc Gynecol Invest* 2003; 10:315–322.
 26. **Rubio C, Pehlivan T, Rodrigo L, Simon C, Remohi J, Pellicer A.** Embryo aneuploidy screening for unexplained recurrent miscarriage: a minireview. *Am J Reprod Immunol* 2005; 53:159–165.
 27. **Sermon K, Van Steirteghem A, Liebaers I.** Preimplantation genetic diagnosis. *Lancet* 2004; 363:1633–1641.
 28. **Shahine LK, Cedars MI.** Preimplantation genetic diagnosis does not increase pregnancy rates in patients at risk for aneuploidy. *Fertil Steril* 2006; 85:51–56.
 29. **Wells D.** Advances in preimplantation genetic diagnosis. *Eur J Obstet Gynecol Reprod Biol* 2004; 115 (suppl 1):S97–101.
 30. **Ogilvie CM, Braude PR, Scriven PN.** Preimplantation genetic diagnosis—an overview. *J Histochem Cytochem* 2005; 53:255–260.
 31. **Rao GD, Tan SL.** In vitro maturation of oocytes. *Semin Reprod Med* 2005; 23:242–247.
 32. **Budev MM, Arroliga AC, Falcone T.** Ovarian hyperstimulation syndrome. *Crit Care Med* 2005; 33 (suppl):S301–S306.
 33. **Falcone T, Attaran M, Bedaiwy MA, Goldberg JM.** Ovarian function preservation in the cancer patient. *Fertil Steril* 2004; 81:243–257.
 34. **Jeremias E, Bedaiwy MA, Biscotti C, Falcone T.** Assessment of injury in cryopreserved ovarian tissue. *Fertil Steril* 2003; 79:651–653.
 35. **Donnez J, Dolmans MM, Demylle D, et al.** Live birth after orthotopic transplantation of cryopreserved ovarian tissue. *Lancet* 2004; 364:1405–1410.
 36. **Meirow D, Levron J, Eldar-Geva T, et al.** Monitoring the ovaries after autotransplantation of cryopreserved ovarian tissue: endocrine studies, in vitro fertilization cycles, and live birth. *Fertil Steril* 2007; 87:418.e7–e15.

ADDRESS: Jeffrey M. Goldberg, MD, Department of Obstetrics and Gynecology, A81, Cleveland Clinic, 9500 Euclid Avenue, Cleveland, OH 44195; e-mail goldbej@ccf.org