

**JAMES ROSNECK, MD**Department of Orthopaedic Surgery,
Cleveland Clinic**CARLOS A. HIGUERA, MD**Department of Orthopaedic Surgery,
Cleveland Clinic**NABIL TADROSS, MD**Department of General Internal Medicine,
Cleveland Clinic**VIKTOR KREBS, MD**Head, Section of Adult Reconstruction,
Department of Orthopaedic Surgery, Cleveland
Clinic**Wael K. Barsoum, MD***Vice-chairman, Department of Orthopaedic
Surgery, Cleveland Clinic

Managing knee osteoarthritis before and after arthroplasty

ABSTRACT

Primary care physicians play a key role in the diagnosis and the nonoperative management of knee osteoarthritis (OA), including monitoring for problems in patients who have undergone knee replacement surgery. This article reviews key clinical and radiographic findings of knee OA, options for conservative management, and signs and symptoms of complications after total knee arthroplasty.

KEY POINTS

Treatments such as unloader braces, high tibial osteotomy, distal varus femoral osteotomy, and unicompartmental knee replacement have a role in the management of end-stage knee OA in certain patients.

Knee arthroscopy does not alter the progression of knee OA, and its use is controversial, since trials comparing arthroscopic debridement, lavage, and a placebo procedure reveal no difference among the groups.

Improvements in minimally invasive approaches to total knee arthroplasty are yielding excellent outcomes.

TODAY THE SURGICAL TREATMENT of osteoarthritis (OA) includes more options than ever. With the aging of the population and the increasing demand for OA therapy, surgeons continue to refine procedures. Besides the gold-standard total knee arthroplasty (TKA), minimally invasive TKA and computer-assisted techniques are being perfected.

Internists play a key role in managing knee OA, from helping patients manage pain early in the disease to referring them for surgery when conservative therapy no longer helps. And even after surgery, primary care physicians help in the follow-up, helping to monitor patients for short-term and long-term complications.

This article reviews the key clinical and radiographic findings in OA, options for conservative treatment, and criteria for surgical referral. While we briefly discuss surgical options, we will also review the signs of complications in patients who have undergone knee joint replacement, such as thromboembolism, infection, and periprosthetic fracture.

KNEE OSTEOARTHRITIS: KEY FEATURES

Osteoarthritis is a chronic, often widespread form of arthritis that may affect all joint structures and is commonly manifested in the knee. Except for traumatic arthritis, which can occur at any age after an injury, the prevalence of primary (idiopathic) OA increases with age. Its onset is insidious but progressive, resulting in significant pain and disability, often leading to deterioration in function and loss of independence.

OA is a disease of aging cartilage. While

*Dr. Barsoum has indicated that he is a consultant to Stryker Orthopaedics and Exactech corporations, has received research support from Stryker Orthopaedics and TissueLink Medical corporation, and has received financial support from Exactech and TissueLink for device or instrument design.

its exact pathophysiology is not yet understood, OA clearly has many contributors, including a combination of risk factors such as genetics, microtrauma, increased cytokine activity, and obesity.

The diagnosis of OA is made both clinically and radiographically. Clinically, the patient with OA has activity-triggered pain that decreases with rest. Other signs and symptoms of OA include knee effusion, crepitation, subjective locking and sensation of unsteadiness, angular deformity resulting in gait abnormality secondary to decreased quadriceps strength, and joint inflexibility.¹⁻³ Joint contractures are often seen in severe end-stage OA. The ultimate and sometimes devastating result of OA is debilitating pain and loss of independent functioning, manifested by the inability to carry out activities of daily living.

The clinical manifestations of OA of the knee must be correlated with radiographic findings. The plain radiograph remains the primary objective diagnostic tool. There are four cardinal radiographic findings of OA:

- Asymmetric loss of cartilage resulting in joint space narrowing
- Subchondral bone cysts
- Osteophytosis
- Subchondral bone sclerosis.

Plain films can also be used to grade the severity of OA. It is now widely accepted that OA has four stages or grades, from 1 to 4 according to severity. Grade 1 is mild OA in which the joint space is preserved, whereas grade 4 is characterized by the loss of articular cartilage with bone-on-bone articulation. At this stage, valgus or varus angular deformity is not uncommon.

The clinical severity of OA, based on both radiographic evidence and clinical symptoms, dictates whether conservative or surgical management is appropriate (FIGURE 1).

■ WIDE RANGE OF CONSERVATIVE TREATMENTS

Conservative management should almost always be the first line of treatment for knee OA. It includes physical therapy, exercises for range of motion and strengthening, weight loss, analgesics, intra-articular injections, and orthotic devices.

Physical therapy and exercises to maintain range of motion and strength of the affected extremity may improve symptoms. Weight loss also helps by decreasing joint reaction forces in the knee.⁴ And in patients who eventually require knee replacement, optimal function and range of motion before surgery are important to achieving a successful surgical outcome.⁵ Overall good health and a lower body mass index also promote a good surgical outcome.⁵

■ CURRENT OPTIONS FOR ANALGESIA

Nonsteroidals and acetaminophen

Acetaminophen and nonsteroidal anti-inflammatory drugs (NSAIDs) can be used either continuously or as needed. Some of these drugs have well-known gastrointestinal adverse effects, but they remain a staple of early arthritis management.

Acetaminophen is effective at reducing the pain of arthritis,^{6,7} but some direct comparisons with NSAIDs show that NSAIDs are more effective, especially in the long term.⁸⁻¹⁰ On the other hand, the gastrointestinal, renal, and perhaps cardiovascular side effects of NSAIDs make chronic use inappropriate for certain patients.

Avoiding adverse effects

Traditional NSAIDs have gastrointestinal adverse effects such as dyspepsia, gastric ulceration, and bleeding due to the inhibition of platelet function. Current recommendations are to include a gastroprotective agent if prescribing an NSAID to a higher-risk patient.¹¹ One option is to use one of the selective inhibitors of cyclooxygenase enzyme 2 (COX-2), which have little effect on COX-1 and consequently fewer gastrointestinal side effects. These drugs also have no significant effect on platelet function, and therefore can be used perioperatively.

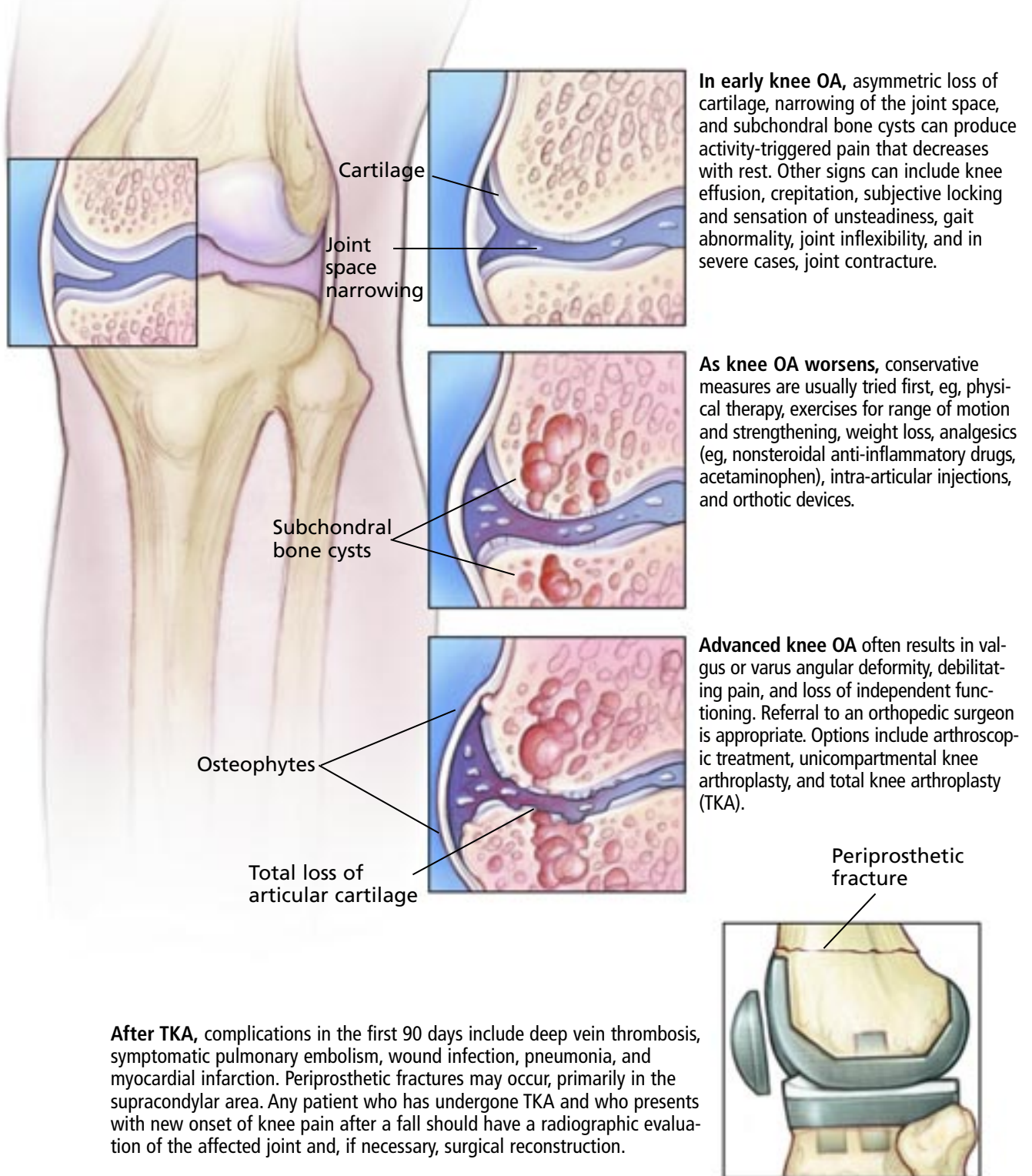
All NSAIDs may also cause renal side effects, especially in the elderly and in those with preexisting renal insufficiency. The degree of cardiovascular risk from chronic selective or nonselective NSAIDs remains controversial.

Tramadol and opioids

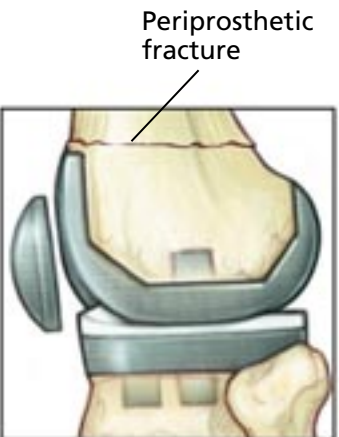
Other drugs that control pain in knee OA

Treatment goals: decrease pain and symptoms and postpone knee surgery

Clinical and radiographic features guide management of knee osteoarthritis (OA)



After TKA, complications in the first 90 days include deep vein thrombosis, symptomatic pulmonary embolism, wound infection, pneumonia, and myocardial infarction. Periprosthetic fractures may occur, primarily in the supracondylar area. Any patient who has undergone TKA and who presents with new onset of knee pain after a fall should have a radiographic evaluation of the affected joint and, if necessary, surgical reconstruction.



Medical Illustrator: Joseph Kanasz ©2007 CCF

FIGURE 1

include tramadol (Ultram) and opioid analgesics. These are useful during flare-ups if the pain does not respond to NSAIDs or acetaminophen. Short- and long-acting opioids can be used, preferably in fixed intervals, for less than 2 weeks at a time. Long-term use of opioid analgesics is appropriate in patients who are not good candidates for surgery and who have severe pain that does not respond to other drugs.¹²

■ TYPES OF INTRA-ARTICULAR INJECTION

Intra-articular injections may provide pain relief in knee OA. Multiple combinations of anesthetic and steroid agents have been used successfully and may provide modest relief.^{13,14}

A recent advance is the injection of hyaluronic acid material that provides a substitute for normal joint fluid. The goal of these injections is to enhance lubrication, decreasing friction of joint surfaces against one another.

A large meta-analysis indicated that hyaluronic acid injections are only slightly more effective than placebo,¹⁵ whereas other studies¹⁶ show them to be a useful addition to conservative management. Because of these conflicting results, use of these injections remains controversial.

■ WHEN TO TRY ORTHOTIC DEVICES

For slight varus or valgus deformity that occurs with unicompartmental degeneration in knee OA, use of an “unloader” brace can reduce the forces that are applied through the diseased compartment of the knee. However, clinical studies supporting the efficacy of unloader bracing are lacking.

Other approaches with the same goal include insertion of a medial or lateral heel wedge into the shoe. Lateral heel wedges are used mainly for symptoms related to OA of the medial compartment, while medial wedges may be used to treat symptoms of lateral compartment OA.¹⁷ If properly fitted, these inserts have shown a reduction in pain over a 2-year period.¹⁸

■ REFERRING THE PATIENT FOR SURGERY

If conservative measures fail to control symptoms and the patient has significant limita-

tions to activities of daily living, then referral to an orthopedic surgeon is appropriate. Surgical interventions for knee OA include arthroscopy, osteotomy, patellar resurfacing arthroplasty, unicompartmental knee arthroplasty, and total knee arthroplasty (TKA).

■ THE ROLE OF ARTHROSCOPY IS STILL CONTROVERSIAL

Knee arthroscopy does not alter the progression of knee OA, and its use is controversial, since trials comparing arthroscopic debridement, lavage, and a placebo procedure reveal no difference among the groups.¹⁹ Yet despite this, it is often used early in the treatment of OA, specifically for mechanical symptoms, and primarily for symptom relief. Carefully selected patients with symptoms that are primarily mechanical in nature—eg, presence of loose bodies, locking, or a specific mechanism of injury²⁰—may have some functional improvement after arthroscopy.

■ UNICOMPARTMENTAL KNEE ARTHROPLASTY

Unicompartmental knee arthroplasty in which just one femoral condyle is replaced has gained popularity over the last decade because it is less invasive than TKA and has a shorter recovery period. However, very few patients meet the strict selection criteria for this procedure. These criteria are as follows:

- Degenerative changes must be unicompartmental, and lack of involvement of the opposite femoral condyle must be confirmed radiographically.
- The patellofemoral articulation must have only minimal changes, and both the anterior and posterior cruciate ligament must be intact.
- Knee flexion must be greater than 90°, with a flexion contracture of less than 15°.
- The patient must have a sedentary lifestyle and weigh less than 275 lbs.

Patients with inflammatory arthritis and hemophilia are not candidates for this procedure.

A recent study following these guidelines revealed a 13-year prosthetic survival of 95%, with good or excellent results attained in 92% of knees 10 years after surgery.²¹ The

**Grade 4 OA:
loss of cartilage
with bone-on-
bone
articulation,
and possibly
valgus or varus
deformity**

most common reason for eventual conversion to TKA was subsequent degeneration in the opposite or patellofemoral compartments.²¹

■ TOTAL KNEE ARTHROPLASTY

If conservative treatments fail or are no longer appropriate, TKA is the best treatment we have for end-stage OA of the knee. Up to 20 years of experience with millions of patients show that TKA improves pain and function. In 1996, more than 607,000 knee and hip replacements were performed in the United States,²² and the number of TKA procedures is expected to increase an additional 85% by 2030.²³

TKA continues to be the best option for improving knee pain and function, with the ability to correct varus or valgus articular deformity in end-stage OA. It is the treatment of choice in patients over age 55 with progressive and painful OA in whom nonsurgical and less-invasive treatments have failed.

The increasing demand for TKA has placed high emphasis on improvements in technique, instrumentation, and operating room efficiency. Such changes have improved patient outcomes and decreased the complication rate.

The goals of TKA

TKA creates a kinematically stable, solidly fixed, and well-functioning knee, and success depends on good fixation techniques, soft-tissue balancing, and restoration of the mechanical axis. Lack of attention to any of these could lead to an imperfectly reconstructed knee that may require surgical revision.

Techniques of TKA

Although cementless fixation using porous coated pegs and stems has been used, cemented component fixation using methylmethacrylate is the most common today. It is debatable whether retention, sacrifice, or substitution of the posterior cruciate ligament leads to better outcomes with primary TKA.²⁴ The senior authors of this article (V.K., W.K.B.) retain the posterior cruciate ligament in most cases if it is intact at the time of surgery.

Some feel that cementless implants are

advantageous for young patients, but there is no clinical evidence of improved implant survival or function of cementless prosthetics.

■ MANAGING THE COMPLICATIONS OF TKA

While the rate of complications after TKA is low, complications that occur can be devastating or even lethal.

The most common complications within 90 days of TKA include symptomatic deep vein thrombosis (2.1%), pulmonary embolism (0.8%), wound infection (0.4%), pneumonia (1.4%), myocardial infarction (0.8%), and death (0.7%).²⁵

Deep vein thrombosis

Deep vein thrombosis is the most common complication after TKA and is thought to be multifactorial. Risk factors include age older than 40, prolonged immobilization, anesthesia and a surgical procedure involving the lower extremities, a history of cancer, a history of deep vein thrombosis, and obesity. Associated hemostatic abnormalities include antithrombin III deficiency, protein C or S deficiency, history of heparin-induced thrombocytopenia, dysfibrinogenemia, myeloproliferative disorder, or the presence of lupus anticoagulant.²⁶

Protocols for routine screening for thromboembolism after total joint replacement are controversial and vary across the United States. The protocol followed by the senior authors of this article (V.K., W.K.B.) includes duplex ultrasonography on postoperative day 2. Any detected thrombosis is treated with full anticoagulation, regardless of the symptoms. Fatal pulmonary embolism occurs in less than 0.5% of all cases of TKA,²⁷ and in less than 0.1% when prophylaxis is used.²⁸ However, as pulmonary embolism is considered to be in a continuum with deep vein thrombosis, it is treated with full anticoagulation as necessary.

The literature is filled with evidence to support the effectiveness of thromboprophylaxis in reducing the incidence of deep vein thrombosis and fatal pulmonary embolism.²⁹ Although controversy still exists over which agents are best at preventing and treating thromboembolism, the prevalence of thrombosis after treatment ranges from 35% to 50%

Hyaluronic acid joint injections: sometimes useful, but still controversial

TABLE 1

Causes of pain after total knee arthroplasty

Intra-articular causes

Infection
Instability
Loosening of the components of the prosthesis
Arthrofibrosis
Dysfunction or maltracking of the extensor mechanism

Extra-articular causes

Spinal disorder
Vascular claudication
Tendonitis
Anserine bursitis
Stress fracture
Periprosthetic fracture
Hip osteoarthritis/disease
Chronic regional pain syndrome

after TKA without prophylaxis.³⁰

Recommended prophylaxis. Thromboprophylaxis can be mechanical or pharmacologic. The predominant mechanical approach involves an external pneumatic compression device, which increases venous return, decreases stasis, and enhances fibrinolysis.³¹ Mechanical devices used alone have not proven to be more effective than pharmacologic prophylaxis alone; therefore, it is felt that a combination of the two gives the best protection.³¹

Drugs currently used for thromboprophylaxis include aspirin, warfarin (Coumadin), low-molecular-weight heparin (LMWH), and fondaparinux (Arixtra). Current thromboprophylaxis after TKA is based on the 2004 guidelines of the American College of Chest Physicians,³² which recommended prophylaxis for 7 to 14 days after surgery. The drugs to use are LMWH (30 mg every 12 hours), warfarin (international normalized ratio of 2.0 to 3.0), or fondaparinux 2.5 mg daily.³² The guidelines do not recommend aspirin,³² for several reasons: studies are few and methodologically flawed; a number of trials either found aspirin to be of no significant benefit or found it to be inferior; and aspirin is associated with a risk of bleeding. However, some authors report using aspirin for thrombopro-

phylaxis in their TKA patients, with a rate of fatal pulmonary embolism of less than 0.1%.²⁸ The risk of perioperative bleeding increases 1.8% to 5.2% with LMWH or warfarin, and this effect is dose-dependent.²⁸

Enoxaparin (Lovenox) is a highly effective thromboprophylactic agent, but its widespread use is limited by a documented increased incidence of bleeding complications.³³

The newest drug for thromboprophylaxis is fondaparinux, a synthetic and specific inhibitor of activated factor X (Xa). Its long half-life allows for once-a-day administration; however, its effectiveness and risk profile are still being studied.

Pain

The goal of joint replacement surgery is to restore an appropriate, pain-free level of function. However, some patients have pain after TKA. When determining the cause of the joint pain in a patient who has undergone TKA, the physician should consider whether the pain has been present since surgery, or if it developed after an initial pain-free interval, and if the cause is intra-articular or extra-articular (TABLE 1). A comprehensive history and a focused physical examination will help determine the cause,^{34,35} but obtaining radiographic anteroposterior and lateral views and a Merchant projection is the first step. Laboratory analysis (eg, complete blood cell count, erythrocyte sedimentation rate, C-reactive protein) is an adjuvant step to help distinguish septic and aseptic causes of pain.³⁵ Culture of joint fluid is the only absolute way to determine infection. Vigilance for infection must always remain high.

The incidence rate of anserine bursitis after TKA is approximately 5%.

Infection

Infection after TKA is potentially devastating. It is one of the leading causes of reoperation after joint arthroplasty.

To avoid deep periprosthetic infections, prophylactic antibiotics are given within 1 hour of skin incision and are continued for 24 hours after surgery. This approach has reduced the incidence of infection in primary joint replacement down to 1% to 4%.³⁶⁻³⁸

Complications of TKA are rare but may be serious and require watchfulness

The organism responsible for most cases of deep periprosthetic infection is *Staphylococcus aureus*, which is a component of the skin flora and can therefore be directly inoculated to the surgical site via the skin incision.³⁸ Patients commonly present with increased pain, swelling, and erythema of the surgical wound. Redness and drainage in the presence of systemic signs of fever, chills, and fatigue should alert the physician to potential infection at the implant site. Pain, often without systemic symptoms or signs, is the principal symptom of periprosthetic infection.

If infection is suspected, the joint should be aspirated with sterile technique before antibiotics are given. Joint fluid analysis with cell count and culture guide operative treatment. Successful treatment of deep periprosthetic infection is still a work in progress but involves comprehensive antibiotic coverage and debridement, revision of the prosthesis via a one-stage or two-stage reimplantation, or resection arthroplasty with or without concomitant arthrodesis.^{39,40}

Use of antibiotics alone is rarely recommended for deep-seated sepsis around the prosthesis and is typically reserved for wound infections that are superficial to the deep fascia.

For patients with deep periprosthetic infection within 2 to 4 weeks of knee replacement, or for patients with signs of acute infection in a prosthetic knee several years after TKA and with no previous infection, the approach now widely accepted in the United States is surgical debridement plus polyethylene (plastic) exchange, coupled with a 6-week course of intravenous antibiotic therapy.^{39,41} The objectives of this procedure are to remove the plastic, cleanse the joint and metal surfaces, and debride the affected synovium before glyocalyx formation on the metal components.

The success of this approach depends on several factors, which include susceptibility of the isolated organisms, stability of the implant, patient age and comorbidities, and the extent of soft-tissue injury. More than 70% of deep periprosthetic infections can be treated with this approach.³⁹ In very rare instances, leg amputation is necessary if repeated surgical revision fails to resolve

chronic recalcitrant infection.⁴²

Periprosthetic fractures

Periprosthetic fractures occur primarily in the supracondylar area due to stress risers (ie, in an area of bone that is weak because of the presence of a biomechanically stiffer substance) just proximal to the metal implants (FIGURE 1). This region is the most commonly affected area after a significant injury to the extremity in patients who have undergone TKA.⁴³ Any knee arthroplasty patient who presents with new onset of knee pain after a fall—or who was able to walk before the fall but now cannot—should have anteroposterior and lateral radiography of the affected joint and, depending on the severity, should be referred for examination by the orthopedic surgeon.

Depending on the fracture location and degree of displacement, bone quality, and stability of the fixed components, many treatment options are available to the surgeon. Poor surgical candidates with fractures around the knee after TKA may be treated conservatively, with the knowledge that the outcome will be a malaligned and stiff knee.⁴⁴

Open reduction and internal fixation is an option for patients who are good surgical candidates and who have displaced fractures but stably fixed components. These are reduced with fixed-angle devices such as locked condylar plates, especially in patients with osteoporotic bone, and with retrograde intramedullary nailing via a transarticular approach through an implant that has an open intercondylar notch. In cases of implants that are not well fixed, revision arthroplasty is the treatment of choice, with bone defects reconstructed with either allograft or augmenting metal wedges.^{43,44}

■ FUTURE DIRECTIONS: MINIMALLY INVASIVE TKA

Despite the success of current TKA procedures, surgical techniques continually evolve in an attempt to improve patient outcomes. This evolution includes improvements in both instrumentation and technique. Throughout surgical subspecialties, minimally invasive techniques have been the recent trend because

Surgical techniques continue to evolve, with goals of less pain and quicker return of function

they promise decreased patient pain, decreased hospital stay and costs, and quicker return of function. These goals, while attainable, must be tempered by good scientific research that helps maximize patient safety and outcome in an already successful procedure.

Minimally invasive TKA, as the name implies, involves using a limited incision (4–7 inches, or 2–3 inches less than with the standard technique) with special attention to preserving the continuity of and decreasing the tension on the quadriceps mechanism. Management of the soft tissue, more so than

incision length, has been hypothesized as the major contributing factor for improved early results. Early retrospective analyses have indicated positive outcomes with these techniques.^{45,46}

Another advance in the surgical treatment of TKA is computer-assisted navigation, which allows the surgeon to obtain near-perfect anatomic and mechanical femoral-tibial alignment of the prostheses.^{47,48} This is a key factor in ensuring implant longevity. However, this technology is expensive, and appropriate indications for its use have yet to be determined. ■

REFERENCES

1. Sudarsky L. Geriatrics: gait disorders in the elderly. *N Engl J Med* 1990; 322:1441–1446.
2. Slemenda C, Heilman DK, Brandt KD, et al. Reduced quadriceps strength relative to body weight: a risk factor for knee osteoarthritis in women? *Arthritis Rheum* 1998; 41:1951–1959.
3. Messier SP, Loeser RF, Hoover JL, Semble EL, Wise CM. Osteoarthritis of the knee: effects on gait, strength, and flexibility. *Arch Phys Med Rehabil* 1992; 73:29–36.
4. Focht BC, Rejeski WJ, Ambrosius WT, Katula JA, Messier SP. Exercise, self-efficacy, and mobility performance in overweight and obese older adults with knee osteoarthritis. *Arthritis Rheum* 2005; 53:659–665.
5. Beaupre LA, Lier D, Davies DM, Johnston DB. The effect of a pre-operative exercise and education program on functional recovery, health related quality of life, and health service utilization following primary total knee arthroplasty. *J Rheumatol* 2004; 31:1166–1173.
6. Shen H, Sprott H, Aeschlimann A, Gay RE, Michel BA, Gay S. Analgesic action of acetaminophen in symptomatic osteoarthritis of the knee. *Rheumatology (Oxford)* 2006; 45:765–770.
7. Wegman A, van der Windt D, van Tulder M, Stalman W, de Vries T. Nonsteroidal antiinflammatory drugs or acetaminophen for osteoarthritis of the hip or knee? A systematic review of evidence and guidelines. *J Rheumatol* 2004; 31:344–354.
8. Case JP, Baliunas AJ, Block JA. Lack of efficacy of acetaminophen in treating symptomatic knee osteoarthritis: a randomized, double-blind, placebo-controlled comparison trial with diclofenac sodium. *Arch Intern Med* 2003; 163:169–178.
9. Temple AR, Benson GD, Zinsenheim JR, Schweinle JE. Multicenter, randomized, double-blind, active-controlled, parallel-group trial of the long-term (6–12 months) safety of acetaminophen in adult patients with osteoarthritis. *Clin Ther* 2006; 28:222–235.
10. Schnitzer TJ, Weaver AL, Polis AB, Petruschke RA, Geba GP. Efficacy of rofecoxib, celecoxib, and acetaminophen in patients with osteoarthritis of the knee. A combined analysis of the VACT studies. *J Rheumatol* 2005; 32:1093–1105.
11. Archibeck MJ, White RE Jr. What's new in adult reconstructive knee surgery. *J Bone Joint Surg Am* 2005; 87:1656–1666.
12. Shojania KG, Esdaile JM, Greidanus N. *Orthopaedic Knowledge Update 8: Home Study Syllabus*. Rosemont, IL: American Academy of Orthopaedic Surgeons 2005:229–244.
13. Hanypsiak BT, Shaffer BS. Nonoperative treatment of unicompartmental arthritis of the knee. *Orthop Clin North Am* 2005; 36:401–411.
14. Arroll B, Goodyear-Smith F. Corticosteroid injections for osteoarthritis of the knee: meta-analysis. *BMJ* 2004; 328:869.
15. Lo GH, LaValley M, McAlindon T, Felson DT. Intra-articular hyaluronic acid in treatment of knee osteoarthritis: a meta-analysis. *JAMA* 2003; 290:3115–3121.
16. Wang CT, Lin J, Chang CJ, Lin YT, Hou SM. Therapeutic effects of hyaluronic acid on osteoarthritis of the knee. A meta-analysis of randomized controlled trials. *J Bone Joint Surg Am* 2004; 86-A:538–545.
17. Keating EM, Faris PM, Ritter MA, Kane J. Use of lateral heel and sole wedges in the treatment of medial osteoarthritis of the knee. *Orthop Rev* 1993; 22:921–924.
18. Toda Y, Tsukimura N. A 2-year follow-up of a study to compare the efficacy of lateral wedged insoles with subtalar strapping and in-shoe lateral wedged insoles in patients with varus deformity osteoarthritis of the knee. *Osteoarthritis Cartilage* 2006; 14:231–237.
19. Moseley JB, O'Malley K, Petersen NJ, et al. A controlled trial of arthroscopic surgery for osteoarthritis of the knee. *N Engl J Med* 2002; 347:81–88.
20. Hunt SA, Jazrawi LM, Sherman OH. Arthroscopic management of osteoarthritis of the knee. *J Am Acad Orthop Surg* 2002; 10:356–363.
21. Berger RA, Meneghini RM, Jacobs JJ, et al. Results of unicompartmental knee arthroplasty at a minimum of ten years of follow-up. *J Bone Joint Surg Am* 2005; 87A:999–1006.
22. **Healthcare Cost and Utilization Project**. Table 2: Statistics for 1996 HCUP Nationwide Inpatient Sample, by multi-level CCS procedure (principal procedure only). Available at: www.hcup-us.ahrq.gov/reports/natstats/his96/table2a.htm. Last accessed August 2, 2007.
23. National Center for Health Statistics in American Academy and American Association of Orthopaedic Surgeons Bulletin 1999; 47:14.
24. Tanzer M, Smith K, Burnett S. Posterior-stabilized versus cruciate-retaining total knee arthroplasty: balancing the gap. *J Arthroplasty* 2002; 17:813–819.
25. Mahomed NN, Barrett J, Katz JN, Baron JA, Wright J, Losina E. Epidemiology of total knee replacement in the United States Medicare population. *J Bone Joint Surg Am* 2005; 87:1222–1228.
26. Kearon C. Natural history of venous thromboembolism. *Circulation* 2003; 107(23 suppl 1):I22–I30.
27. Ansari S, Warwick D, Ackroyd CE, Newman JH. Incidence of fatal pulmonary embolism after 1,390 knee arthroplasties without routine prophylactic anticoagulation, except in high-risk cases. *J Arthroplasty* 1997; 12:599–602.
28. Lotke PA, Lonner JH. Deep venous thrombosis prophylaxis: better living through chemistry—in opposition. *J Arthroplasty* 2005; 20(4 suppl 2):15–17.
29. Freedman KB, Brookenthal KR, Fitzgerald RH Jr, Williams S, Lonner JH. A meta-analysis of thromboembolic prophylaxis following elective total hip arthroplasty. *J Bone Joint Surg Am* 2000; 82-A:929–938.

30. **Fujita S, Hirota S, Oda T, Kato Y, Tsukamoto Y, Fuji T.** Deep venous thrombosis after total hip or total knee arthroplasty in patients in Japan. *Clin Orthop Relat Res* 2000; 375:168–174.
31. **Woolson ST, Robinson RK, Khan NQ, Roqers BS, Maloney WJ.** Deep venous thrombosis prophylaxis for knee replacement: warfarin and pneumatic compression. *Am J Orthop* 1998; 27:299–304.
32. **Geerts WH, Pineo GF, Heit JA, et al.** Prevention of venous thromboembolism: the Seventh ACCP Conference on Antithrombotic and Thrombolytic Therapy. *Chest* 2004; 126(3 suppl):3385–4005.
33. **Fitzgerald RH Jr, Spiro TE, Trowbridge AA, et al.** Prevention of venous thromboembolic disease following primary total knee arthroplasty. A randomized, multicenter, open-label, parallel-group comparison of enoxaparin and warfarin. *J Bone Joint Surg Am* 2001; 83-A:900–906.
34. **Brown EC 3rd, Clarke HD, Scuderi GR.** The painful total knee arthroplasty: diagnosis and management. *Orthopedics* 2006; 29:129–136; quiz 137–138.
35. **Dennis DA.** Evaluation of painful total knee arthroplasty. *J Arthroplasty* 2004; 19(4 suppl 1):35–40.
36. **Tang WM, Chiu KY, Ng TP, Yau WP, Ching PT, Seto WH.** Efficacy of a single dose of cefazolin as a prophylactic antibiotic in primary arthroplasty. *J Arthroplasty* 2003; 18:714–718.
37. **de Lalla F.** Antibiotic prophylaxis in orthopedic prosthetic surgery. *J Chemother* 2001; 13 Spec No 1:48–53.
38. **Blom AW, Brown J, Taylor AH, Pattison G, Whitehouse S, Bannister GC.** Infection after total knee arthroplasty. *J Bone Joint Surg Br* 2004; 86:688–691.
39. **Insall JN, Thompson FM, Brause BD.** Two-stage reimplantation for the salvage of infected total knee arthroplasty. 1983. *J Bone Joint Surg Am* 2002; 84-A:490.
40. **McDonald DJ, Fitzgerald RH Jr, Ilstrup DM.** Two-stage reconstruction of a total hip arthroplasty because of infection. *J Bone Joint Surg Am* 1989; 71:828–834.
41. **Crockarell JR, Hanssen AD, Osmon DR, Morrey BF.** Treatment of infection with debridement and retention of the components following hip arthroplasty. *J Bone Joint Surg Am* 1998; 80:1306–1313.
42. **Sierra RJ, Trousdale RT, Pagnano MW.** Above-the-knee amputation after a total knee replacement: prevalence, etiology, and functional outcome. *J Bone Joint Surg Am* 2003; 85-A:1000–1004.
43. **Tharani R, Nakasone C, Vince KG.** Periprosthetic fractures after total knee arthroplasty. *J Arthroplasty* 2005; 20(4 suppl 2):27–32.
44. **Dennis DA.** Periprosthetic fractures following total knee arthroplasty. *Instr Course Lect* 2001; 50:379–389.
45. **Laskin RS, Beksac B, Phongjunakorn A, et al.** Minimally invasive total knee replacement through a mini-midvastus incision: an outcome study. *Clin Orthop Relat Res* 2004; 428:74–81.
46. **Haas SB, Cook S, Beksac B.** Minimally invasive total knee replacement through a mini midvastus approach: a comparative study. *Clin Orthop Relat Res* 2004; 428:68–73.
47. **Chauhan SK, Scott RG, Breidahl W, Beaver RJ.** Computer-assisted knee arthroplasty versus a conventional jig-based technique. A randomised, prospective trial. *J Bone Joint Surg Br* 2004; 86:372–377.
48. **Bathis H, Perlick L, Tingart M, Luring C, Zurakowski D, Grifka J.** Alignment in total knee arthroplasty. A comparison of computer-assisted surgery with the conventional technique. *J Bone Joint Surg Br* 2004; 86:682–687.

ADDRESS: Wael K. Barsoum, MD, Adult Reconstruction, Department of Orthopaedic Surgery, WL30, Cleveland Clinic, 30033 Clemens Road, Westlake, OH 44145; e-mail: barsouw@ccf.org.