

**PRAVIN KUMAR RAO, MD**Glickman Urological and Kidney Institute,
Cleveland Clinic**J. STEPHEN JONES, MD***Vice Chairman, Glickman Urological
and Kidney Institute, Cleveland Clinic;
Associate Professor of Surgery, Cleveland
Clinic Lerner College of Medicine of Case
Western Reserve University

How to evaluate ‘dipstick hematuria’: What to do before you refer

■ ABSTRACT

Although major health organizations do not support screening for hematuria by dipstick testing, millions of patients without symptoms are tested yearly. Since urinary dipstick tests for hematuria have a high false-positive rate, patients with positive dipstick results require microscopic urinalysis before the diagnosis of hematuria can be made. Primary care physicians can help protect patients from the anxiety, costs, and risks of an unnecessary urologic workup by adhering to the principles of early hematuria management.

■ KEY POINTS

Dipstick tests by themselves do not confirm that hematuria is present; thus, “dipstick hematuria” is a potential misnomer. Patients without symptoms who have a positive dipstick test and negative microscopic urinalysis are better described as having *dipstick pseudohematuria*, a clinically insignificant finding.

Significant hematuria is defined as three or more red blood cells per high-power field in a properly collected and centrifuged urine specimen; this is the definition that should dictate which patients require further urologic evaluation.

Since the evaluation for hematuria usually includes cystoscopy and imaging studies, it is crucial to confirm that hematuria is truly present before initiating an invasive and costly evaluation.

*Dr. Jones has disclosed that he has received honoraria from the Abbott, Cook, Endocare, and Pfizer corporations for teaching, speaking, consulting, and serving on advisory committees or review panels.

MANY PEOPLE have some amount of blood in their urine, but relatively few have a serious problem.

In a population-based study in Rochester, Minnesota, red blood cells were found in the urine of 13% of symptom-free adults.¹ In other studies, the figure ranged from 9% to 18%.²

Hematuria is sometimes detected during investigation of symptoms such as dysuria, urinary frequency, or flank pain. However, many referrals to urologists are made purely on the basis of the results of a dipstick urinalysis screening test in a patient without symptoms.

The United States Preventive Task Force³ discourages routine testing for hematuria to screen for bladder cancer in patients without symptoms, and the Canadian Task Force on the Periodic Health Examination⁴ and the American Urological Association (AUA)^{2,5} do not recommend it either. Nevertheless, approximately 40% of primary care physicians believe in it,⁶ although the number seems to be declining.⁷ A reason that dipstick testing is so popular is that it is an inexpensive and simple way to detect glucosuria and medical renal disease.^{8–11}

The risk of significant disease in a patient with microhematuria but without symptoms is low, and the evaluation for hematuria can be costly and invasive. For an individual patient with a hemoglobin-positive dipstick test, the finding should not be ignored, but the patient does not necessarily need a complete evaluation. It is important to determine which patients require urologic studies and consultation, nephrologic evaluation, or no intervention at all.

This review addresses issues related to hematuria for the primary care physician, clar-

TABLE 1

Risk factors for significant urologic disease

Abuse of analgesic drugs
 Age > 40 years
 Cyclophosphamide
 Exposure to pelvic radiation
 History of gross hematuria
 History of urinary tract infection
 Irritative voiding symptoms
 Occupational exposure to chemicals or dyes
 Smoking
 Urologic history

REPRINTED FROM GROSSFELD GD, LITWIN MS, WOLF JS, ET AL. EVALUATION OF ASYMPTOMATIC MICROSCOPIC HEMATURIA IN ADULTS: THE AMERICAN UROLOGICAL ASSOCIATION BEST PRACTICE POLICY—PART II: PATIENT EVALUATION, CYTOLOGY, VOIDED MARKERS, IMAGING CYSTOSCOPY, NEPHROLOGY EVALUATION, AND FOLLOW-UP. UROLOGY 2001; 57:604–610, WITH PERMISSION FROM ELSEVIER.

Nearly all patients with gross hematuria should be referred to a urologist

ifies some of the important definitions, builds on these terms to delineate which patients should be referred to a urologist, and provides simple recommendations about ancillary studies and their potential role before urologic consultation. Understanding this information will ultimately assure appropriate management of patients without symptoms who have positive dipstick screening tests, leading to decreased use of costly and invasive tests and more appropriate long-term follow-up.

■ BASIC DEFINITIONS

Gross (macroscopic) hematuria is blood in the urine that is visible without microscopy. This condition almost always warrants urologic evaluation.^{2,5}

Microscopic hematuria, or microhematuria, is the finding of red blood cells in the urine on microscopy. (In contrast, in dipstick hematuria—see below—blood cells may or may not be present in the urine.)

“Dipstick hematuria” and “dipstick microhematuria” are potential misnomers. The dipstick test for hematuria is a nondiagnostic screening test. A positive result is simply a color change due to oxidation of a test-strip reagent;

it does not confirm that blood cells are present. Factors that can cause a false-positive result on a dipstick test include hemoglobinuria, myoglobinuria, concentrated urine, menstrual blood in the urine sample, and rigorous exercise.¹² Thus, the diagnosis of hematuria cannot be made by dipstick alone. Unless red blood cells are seen microscopically, the term *microhematuria* is inappropriate.

Of note, if the specific gravity of the urine is very low (< 1.007), microscopy can fail to detect urinary red blood cells, owing to cell lysis.² This limitation can be overcome by restricting the patient’s fluid intake and then repeating the urinalysis.

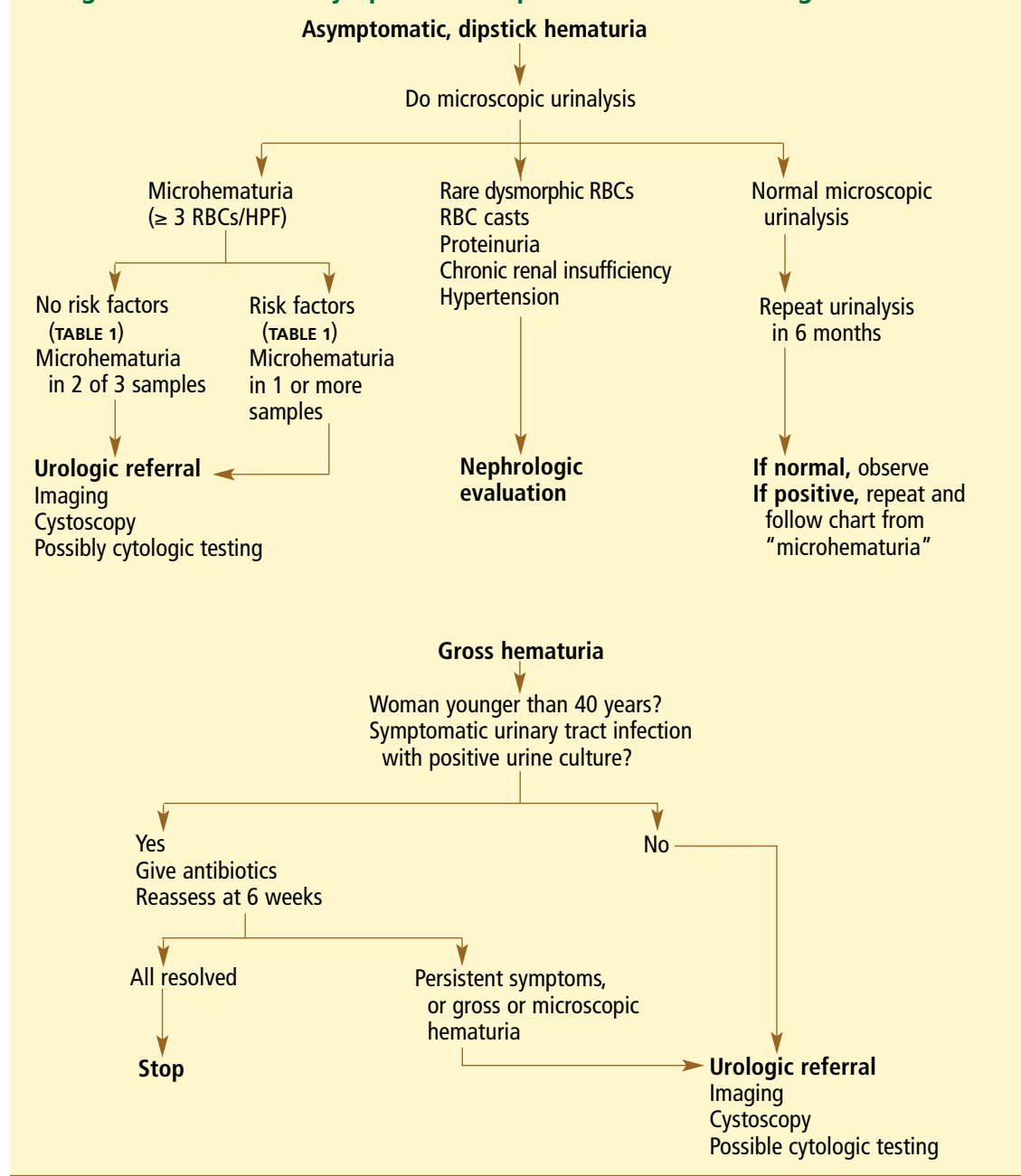
Many patients with a positive dipstick oxidation reaction are labeled as having dipstick hematuria although microscopic analysis would show that red blood cells are absent. Perhaps the term *dipstick pseudohematuria* would be more accurate. These patients will not benefit from a costly and invasive urologic workup, so it is crucial to distinguish them from patients with true microhematuria.

■ SIGNIFICANT HEMATURIA: ≥ 3 RBCs/HPF

Microhematuria is often intermittent, and many healthy patients occasionally have a few red blood cells in the urine.¹³ However, no cutoff point for the amount of hematuria can be used to rule out the possibility of cancer.¹⁴ To account for these complicating factors, the AUA Best Practice Policy Panel on Asymptomatic Hematuria considered the literature and expert opinions to define the amount of microhematuria warranting evaluation in patients with risk factors for significant urologic disease.^{2,5}

The AUA panel defined microhematuria as an average of three or more red blood cells per high-power microscopic field (RBCs/HPF) in two out of three properly collected and prepared specimens. Urine should be collected midstream after wiping the urethral meatus with a disinfectant and voiding the initial portion of urine into the toilet. For proper preparation of the urine sample, 10 mL of urine should be centrifuged at 2,000 rpm for 5 minutes and the supernatant discarded. The sediment should then be resuspended in 0.5 to 1.0 mL of remaining urine, and a drop of this suspension should be examined microscopically.

Diagnostic trees for asymptomatic dipstick hematuria and gross hematuria



Symptom-free patients with 'dipstick hematuria' without microscopic hematuria do not need urologic evaluation

FIGURE 1 Diagnostic tree for initial management of asymptomatic hematuria and gross hematuria.

If contamination is suggested (ie, if squamous epithelial cells, bacteria, or both are present), one should consider collecting a specimen through catheterization.^{2,5}

The AUA guidelines do not specify some of the details of management, such as the timing of subsequent microscopic urinalyses, but we

recommend that all urinalyses to establish whether significant hematuria is present be done within 3 to 6 months of the screening dipstick test. If a patient has no risk factors for cancer and has a negative result on the first microscopic urinalysis, the follow-up test can be performed in 1 year. **TABLE 1** shows risk factors for sig-

nificant urologic disease that warrant evaluation in patients with asymptomatic hematuria.⁵

Isolated urinary findings that might warrant evaluation by a nephrologist rather than a urologist include proteinuria, red cell casts, and dysmorphic red blood cells, especially if the serum creatinine level is elevated.^{2,5} Many medical renal conditions (eg, glomerulonephritis) and hemoglobinopathies (eg, sickle cell trait) can cause blood in the urine; when these conditions are accompanied by risk factors for urologic disease, urologic evaluation is indicated as well.

■ CLINICAL RELEVANCE OF HEMATURIA

Approximately 25% of cases of macroscopic hematuria are due to urologic cancers,^{14,15} and another 34% are due to other significant urologic diseases¹⁴—thus, the recommendation that patients with macroscopic hematuria be evaluated by a urologist. In contrast, in microhematuria, the rates of cancer are much lower, ranging between 1% and 10% in large studies.^{2,5}

The urine dipstick test has been found to be 65% to 99% specific for the presence of blood cells, free hemoglobin, or myoglobin.^{2,5} If the true specificity is closer to the lower figure and all patients with a positive dipstick test were referred to a urologist, this would mean the urologic workup would be unnecessary in up to 35% of them, because the dipstick result would be falsely positive.

But that is not all. Most causes of hemoglobinuria or myoglobinuria are of limited clinical significance, except for rare conditions that are usually clinically obvious, such as severe burn injury. Further, remember that from 9% to 18% of patients without symptoms have red blood cells in the urine.^{2,5} In theory, if everyone in the United States had a dipstick test, this would be positive in patients with hematuria as well as in those with hemoglobinuria, myoglobinuria, and other false-positives; if everyone with a positive dipstick result were then referred to a urologist, a substantial portion of the population would receive an unnecessary urologic referral.

Urologic referral and evaluation in these patients not only wastes money: if they undergo imaging studies, they are exposed to radiation and contrast media, with their associated risks, and if they undergo cystoscopy,

they face its attendant discomfort and risk of infection.

■ WHICH PATIENTS WITH HEMATURIA TO REFER TO A UROLOGIST

FIGURE 1 outlines the early management of gross hematuria and asymptomatic dipstick hematuria.

Gross hematuria

Red or tea-colored urine usually indicates gross hematuria. When there is any doubt—such as in the case of a color-blind patient—the presence of red blood cells can be confirmed or ruled out by a microscopic urinalysis.

Nearly all patients with an episode of gross hematuria should be referred to a urologist. The sole exception to this rule can be made when a woman younger than 40 years experiences gross hematuria in the classic setting of a culture-proven, symptomatic urinary tract infection (UTI) and her infection, symptoms, and hematuria all resolve completely with appropriate antibiotics.^{2,5} However, bleeding from cancer is classically intermittent. Therefore, one should not skip the urine culture and just prescribe antibiotics empirically: the patient might actually have cancer, but the supposed UTI may appear to resolve with antibiotic therapy. For the same reason, resolution of hematuria in any other setting does not obviate the need for referral.

Another scenario usually associated with a benign cause is bleeding after extreme physical activity—also known as “runner’s hematuria” or “march hematuria” (so named because it sometimes occurs in soldiers after a particularly grueling training march). Importantly, even in this situation, one should still be suspicious and probably refer the patient to a urologist: just because the patient has just run a marathon, it does not mean that he or she does not have cancer.

Depending on the character, timing, location, and many other characteristics of the patient’s bleeding, a variety of studies may or may not be necessary. For example, blood-spotting of the underpants might signify urethral bleeding, and imaging and cytologic studies might not be indicated. In view of the

Bleeding from urinary tract cancer is classically intermittent

variability in presentation and workup, we recommend that the proper workup for these patients be determined by a urologist.

Symptomatic microhematuria

Patients with true microhematuria (three or more RBCs/HPF) accompanied by bothersome or worrisome symptoms should be referred to a urologist. In a study in Scotland, Sultana et al¹⁶ found that cancer was present in 6 (5%) of 126 patients with microhematuria without symptoms compared with 13 (10.5%) of 124 patients with microhematuria and irritative voiding symptoms; the difference, however, was not statistically significant.

Microscopic urinalysis should be part of the evaluation for flank pain or certain urinary symptoms such as frequency, urgency, retention, or dysuria; results of this test at the time of symptoms can later help the urologist distinguish the cause of the symptoms or hematuria. In addition, in combination with dipstick analysis, microscopic analysis can help distinguish patients with UTI or medical renal disease. If the evaluation suggests that the hematuria and symptoms are due to a UTI, then the findings on a repeat microscopic analysis, performed after the infection has cleared, should be normal. If hematuria, defined as three or more RBCs/HPF, persists in two of three subsequent urinalyses, then the guidelines mandate diagnostic evaluation even if the urinalysis subsequently becomes negative.

Asymptomatic hematuria

In symptom-free patients with dipstick hematuria found on a screening examination, it is crucial to confirm and document true microhematuria. Per the AUA guidelines, microhematuria worthy of urologic workup is the presence of three or more RBCs/HPF on at least two out of three microscopic urinalyses.^{2,5} Patients with dipstick pseudohematuria do not meet this criterion and will not benefit from a costly and invasive evaluation. Conversely, patients with higher levels of microhematuria, who have any risk factors for cancer, or who are anxious about the test results might benefit from urologic consultation before a second urinalysis to confirm the first, positive finding.

Many patients younger than age 40 with asymptomatic microhematuria but no other risk factors for urinary tract cancer can be followed conservatively. Khadra et al¹⁴ reported that only 1 of 143 patients younger than 40 years with microhematuria had cancer. Similarly, Jones et al¹⁷ found, in a prospective study, that no man younger than 40 years with microscopic hematuria had cancer.

Of note: gross or microscopic blood in the urine, even in the setting of anticoagulation, is a marker of urinary tract pathology such as cancer, stones, or infection. Just as patients on anticoagulation therapy who develop gastrointestinal bleeding need a gastrointestinal evaluation, those with hematuria require a urologic evaluation.^{2,5}

STUDIES TO CONSIDER BEFORE CONSULTATION

In symptom-free patients, it is inappropriate to order laboratory or imaging tests on the basis of a dipstick test alone, without confirming that they actually have hematuria. When the blood is confirmed to be present by microscopic examination of centrifuged urine (as described above), benign causes such as UTI should be considered. If a patient does have a UTI with hematuria, urinalysis should be repeated once the infection has cleared up.

Imaging studies

For symptomatic microhematuria. Patients with acute symptoms of renal colic should undergo computed tomography (CT) in a “stone protocol” (without contrast, with 3- to 5-mm cuts of the abdomen and pelvis) to assess for urinary lithiasis. Pregnancy should always be ruled out before radiation exposure; renal ultrasonography is generally the first-choice imaging study for pregnant patients.

For asymptomatic microhematuria. Patients without the classic flank pain of urolithiasis should undergo more extensive studies. For patients at increased risk of cancer, such as heavy smokers, CT urography is the optimal imaging study and is the test least likely to necessitate other follow-up studies.^{18–20} Other imaging options, including ultrasonography and intravenous pyelography, incompletely assess the upper urinary tracts including both renal

CT urography is the preferred initial imaging study in the evaluation of hematuria

parenchyma and urothelial surfaces. CT urography has been shown to find more than 40% of hematuria-causing lesions missed by other studies.¹⁸ Because ordering alternative imaging first will often result in redundant studies, CT urography is the preferred initial imaging study in the evaluation of hematuria.

Before exposing a patient to contrast media, one should ascertain that he or she is not allergic to it. In addition, in patients at risk of contrast nephropathy (ie, those older than 60 years, with diabetes, or with preexisting medical renal disease), one should check the serum creatinine concentration. Magnetic resonance urography, a more expensive study, is as accurate as CT for diagnosing many urologic conditions, so it can be performed in lieu of CT urography in patients with renal insufficiency, iodine allergy, or any reason to avoid ionizing radiation. Some clinicians perform plain radiography of the kidneys, ureters, and bladder as well as ultrasonography in this setting, but determination of the appropriate alternative to CT urography, if required, is best left to the urologist.

Other tests

Cytologic testing of the urine can be valuable in patients with gross hematuria and in those with microhematuria who have risk factors for urinary tract cancer. Although its reported median sensitivity for malignancy is only 48%, a positive cytologic test is approximately 94% specific for malignancy.²¹ Other studies, such as the fluorescence in situ hybridization assay, and the nuclear matrix protein 22 test do not yet have a clear role in the diagnosis of urinary tract disease.²²

However, in general, we caution non-urologists not to order special tumor marker or cytologic tests, or to do so only with careful forethought. Although these studies occasionally detect occult cancer in patients at high risk, an “atypical” finding on cytology or a positive tumor marker test can lead to inappropriate referral and unnecessary biopsy or other tests.

■ WHEN NOT TO REFER A PATIENT WITH HEMATURIA TO A UROLOGIST

Symptom-free patients with a positive dipstick hemoglobin test should not immediately be

referred to a urologist: they should have a microscopic urinalysis first to determine whether they actually have microhematuria, unless microscopic laboratory services are unavailable. Only patients with documented true hematuria, as defined by the AUA guidelines, should be referred for urologic evaluation and diagnostic testing. Once a patient is referred for evaluation, the consultant is under clear pressure to perform a complete investigation to fulfill the expectations of the referring physician. Avoiding expensive unnecessary testing and referral in those without hematuria allows appropriate utilization of resources.

Patients with microhematuria associated with a UTI should have a repeat urinalysis after the UTI is successfully treated; if the hematuria clears with the infection, then the patient needs no further evaluation. Patients with dipstick pseudohematuria and significant proteinuria or a predominance of dysmorphic urinary blood cells might benefit from an evaluation by a nephrologist rather than a urologist.² This is especially true if the patient has an elevated serum creatinine level.

■ ECONOMIC RELEVANCE

In our tertiary care urology clinic, approximately 75% of patients who are referred to us because of microhematuria have not had a microscopic urinalysis before coming here. On further evaluation, up to 75% of these patients are found to have dipstick pseudohematuria that did not actually require consultation or evaluation.²³ It is possible that this occurs even more frequently in the general practice setting.

A Medicare level-4 urologic consultation for hematuria costs \$170; the cumulative cost of unwarranted referrals is undoubtedly substantial. Even more money is wasted on CT urography, cytology, and other testing performed before urologic consultation in patients ultimately found not to have true hematuria. The economic and iatrogenic risks of evaluation cannot be justified in patients who do not exhibit findings that can be considered abnormal as defined in this article.

Magnetic resonance urography can be used in patients who cannot undergo CT urography

CONCLUSION

It is important to distinguish whether hematuria is microscopic or macroscopic, whether there are associated symptoms, and whether a patient has risk factors for significant urologic disease. While dipstick tests are sensitive, they do not reliably diagnose microhematuria, which is the microscopically proven presence of urinary red blood cells. Positive dipstick tests should always be followed by microscopic urinalysis; failure to do so can result in the unfortunate and unnecessary evaluation of

dipstick pseudohematuria, a normal condition.

The AUA defines significant hematuria as three or more RBCs/HPF in two of three properly prepared specimens.² This should determine whether a symptom-free patient needs urologic referral and evaluation for hematuria.

By following these principles, primary care physicians have a valuable opportunity to direct medical care, increase the efficiency of our health care system, and protect patients from the anxiety, costs, and risks of an unnecessary urologic workup. ■

REFERENCES

1. Mohr DN, Offord KP, Owen RA, Melton LJ 3rd. Asymptomatic microhematuria and urologic disease. A population-based study. *JAMA* 1986; 256:224–229.
2. Grossfeld GD, Litwin MS, Wolf JS, et al. Evaluation of asymptomatic microscopic hematuria in adults: the American Urological Association best practice policy—part I: definition, detection, prevalence, and etiology. *Urology* 2001; 57:599–603.
3. US Preventive Services Task Force. Screening for Bladder Cancer, updated November 2004. Available at www.ahrq.gov/clinic/uspstf/uspstfblad.htm.
4. Logsetty S. Screening for bladder cancer. In: Canadian Task Force on the Periodic Health Examination. Canadian Guide to Clinical Preventive Health Care. Ottawa: Health Canada, 1994:826–836.
5. Grossfeld GD, Litwin MS, Wolf JS, et al. Evaluation of asymptomatic microscopic hematuria in adults: The American Urological Association Best Practice Policy—Part II: patient evaluation, cytology, voided markers, imaging cystoscopy, nephrology evaluation, and follow-up. *Urology* 2001; 57:604–610.
6. Prochazka AV, Lundahl K, Pearson W, Oboler SK, Anderson RJ. Support of evidence-based guidelines for the annual physical examination: a survey of primary care providers. *Arch Intern Med* 2005; 165:1347–1352.
7. Chacko KM, Feinberg LE. Laboratory screening at preventive health exams: trend of testing, 1978–2004. *Am J Prev Med* 2007; 32:59–62.
8. Mariani AJ, Luangphinit S, Loo S, Scottolini A, Hodges CV. Dipstick chemical urinalysis: an accurate cost-effective screening test. *J Urol* 1984; 132:64–66.
9. Murphy TE Jr. The urinalysis—inexpensive and informative. *J Inscr Med* 2004; 36:320–326.
10. Woolhandler S, Pels RJ, Bor DH, Himmelstein DU, Lawrence RS. Dipstick urinalysis screening of asymptomatic adults for urinary tract disorders. I. Hematuria and proteinuria. *JAMA* 1989; 262:1214–1219.
11. Pels RJ, Bor DH, Woolhandler S, Himmelstein DU, Lawrence RS. Dipstick urinalysis screening of asymptomatic adults for urinary tract disorders. II. Bacteriuria. *JAMA* 1989; 262:1221–1224.
12. Gerber GS, Brendler CB. Evaluation of the urologic patient: history, physical examination, and urinalysis. In: Wein AJ, Kavoussi LR, Novick AC, Partin AW, Peters CA, editors, *Campbell-Walsh Urology*. 9th ed. Saunders Elsevier: Philadelphia; 2007:81–110.
13. Cohen RA, Brown RS. Clinical practice. Microscopic hematuria. *N Engl J Med* 2003; 348:2330–2338.
14. Khadra MH, Pickard RS, Charlton M, Powell PH, Neal DE. A prospective analysis of 1,930 patients with hematuria to evaluate current diagnostic practice. *J Urol* 2000; 163:524–527.
15. Alishahi S, Byrne D, Goodman CM, Baxby K. Haematuria investigation based on a standard protocol: emphasis on the diagnosis of urological malignancy. *J R Coll Surg Edinb* 2002; 47:422–427.
16. Sultana SR, Goodman CM, Byrne DJ, Baxby K. Microscopic haematuria: urological investigation using a standard protocol. *Br J Urol* 1996; 78:691–696.
17. Jones DJ, Langstaff RJ, Holt SD, Morgans BT. The value of cystourethroscopy in the investigation of microscopic haematuria in adult males under 40 years. A prospective study of 100 patients. *Br J Urol* 1988; 62:541–545.
18. Lang EK, Thomas R, Davis R, et al. Multiphasic helical computerized tomography for the assessment of microscopic hematuria: a prospective study. *J Urol* 2004; 171:237–243.
19. Gray Sears CL, Ward JF, Sears ST, Puckett MF, Kane CJ, Amling CL. Prospective comparison of computerized tomography and excretory urography in the initial evaluation of asymptomatic microhematuria. *J Urol* 2002; 168:2457–2460.
20. Liu W, Mortelé KJ, Silverman SG. Incidental extraurinary findings at MDCT urography in patients with hematuria: prevalence and impact on imaging costs. *AJR Am J Roentgenol* 2005; 185:1051–1056.
21. van Rhijn BW, van der Poel HG, van der Kwast TH. Urine markers for bladder cancer surveillance: a systematic review. *Eur Urol* 2005; 47:736–748.
22. Black PC, Brown GA, Dinney CP. Molecular markers of urothelial cancer and their use in the monitoring of superficial urothelial cancer. *J Clin Oncol* 2006; 24:5528–5535.
23. Rao PR, Jones JS. Retrospective chart review of consultations for hematuria, 2004–2006. Unpublished data. Manuscript in progress.

ADDRESS: J. Stephen Jones, MD, Glickman Urological and Kidney Institute, A100, Cleveland Clinic, 9500 Euclid Avenue, Cleveland, OH 44195; e-mail jones7@ccf.org.