


ENRIQUE DIAZ-GUZMAN, MD

Department of Pulmonary, Allergy, and Critical Care Medicine, Pulmonary Institute, Cleveland Clinic

MARIE M. BUDEV, DO, MPH

Department of Pulmonary, Allergy, and Critical Care Medicine, Pulmonary Institute, Cleveland Clinic

Accuracy of the physical examination in evaluating pleural effusion

■ ABSTRACT

A careful physical examination is a valuable and noninvasive means of assessing pleural effusion and should be routinely performed in every patient in whom this condition is suspected. Although physical examination is less accurate than ultrasonography or computed tomography in detecting a pleural effusion, the sensitivity and specificity of the different physical signs of pleural effusion may be comparable to those of conventional chest radiography.

■ KEY POINTS

The potential causes of pleural effusion are many and include congestive heart failure, pneumonia, cancer, and pulmonary embolism.

Cardinal symptoms of pleural effusion are cough, chest pain, and dyspnea, but these are not very sensitive or specific.

Common signs of pleural effusion are asymmetric chest expansion, asymmetric tactile fremitus, dullness to percussion, absent or diminished breath sounds, and rubs. The larger the effusion, the more sensitive these signs are.

Some have advocated auscultatory percussion (tapping on the manubrium while listening on the patient's back) as being more sensitive than conventional percussion for detecting the dullness to percussion of pleural effusion.

IN DETECTING AND EVALUATING pleural effusion, technology has not replaced clinical skills. Yet, despite centuries of lore, data are limited on the role of the physical examination and on its accuracy compared with other noninvasive tests such as conventional chest radiography or ultrasonography.

The following is an overview of the value of the clinical history and physical examination in detecting pleural effusion and a brief review of the available information regarding its accuracy compared with other diagnostic methods.

■ POTENTIAL CAUSES ARE MANY

The pleurae consist of two membranes that protect the lungs, allow them to move, contribute to their shape, and prevent the alveoli at the pleural surface from becoming overdistended. Between the visceral pleura (covering the lung) and the parietal pleura (covering the diaphragm and the chest wall) is the pleural space.

In healthy adults, the pleural space contains an estimated 5 to 10 mL of pleural fluid (0.1 mg/kg body weight).¹ Pleural effusion is an accumulation of an abnormal amount of fluid in the pleural space.

Although the potential causes are many, the most common are congestive heart failure, pneumonia (40% of patients hospitalized with pneumonia have pleural effusion),^{2,3} cancer, and pulmonary embolism.⁴

Because many diseases affecting different organs can cause a pleural effusion, we cannot overemphasize the importance of a thorough history and physical examination to uncover clues that will help identify its cause and narrow the diagnostic workup. For example, significant weight loss and cachexia could be due

TABLE 1

Common physical signs of pleural effusion

| SIGN | SENSITIVITY | SPECIFICITY | POSITIVE PREDICTIVE VALUE | NEGATIVE PREDICTIVE VALUE |
|---|-------------|----------------------|---------------------------|---------------------------|
| Asymmetry of expansion ¹⁰ | 0.74 | 0.91 | 0.68 | 0.93 |
| Asymmetry of tactile fremitus ¹⁰ | 0.82 | 0.86 | 0.59 | 0.95 |
| Dullness to percussion* | | | | |
| Comparative technique ^{10,11} | 0.53–0.89 | 0.71 ^{0.81} | 0.55 | 0.97 |
| Auscultatory technique ^{10,12–14} | 0.19–0.95 | 0.85–1.0 | 0.32–0.5 | 0.75–0.89 |
| Absent breath sounds ^{10,15} | 0.42–0.88 | 0.83–0.90 | 0.57 | 0.96 |
| Pleural rub ¹⁰ | 0.05 | 0.99 | 0.5 | 0.89 |

*See text, FIGURES 3–5

Pneumonia, heart failure, and cancer are common causes of pleural effusions

to cancer, and joint, skin, or eye symptoms could be due to a connective tissue disorder.

A thorough review of the patient's medications is mandatory, since several medications (eg, amiodarone [Cordarone], methotrexate [Rheumatrex, Trexall], and nitrofurantoin [Macrobid]) can be associated with exudative effusions. In addition, the patient's occupational history must be ascertained, since exposure to asbestos can raise the suspicion of a malignant disease of the pleura such as mesothelioma.

■ **SYMPTOMS ARE NEITHER SENSITIVE NOR SPECIFIC**

The symptoms of pleural effusion are neither sensitive nor specific, and many patients have manifestations of the underlying process but not of the effusion itself. The most common symptoms directly related to effusion are cough, dyspnea, and pleuritic chest pain.⁵

Cough. Many patients with a pleural effusion have a dry, nonproductive cough, a consequence of inflammation of the pleurae or compression of the bronchial walls. Although this symptom is rarely helpful in diagnosing a pleural effusion, if accompanied by purulent sputum it suggests pneumonia, and if complicated by hemoptysis it suggests cancer or pulmonary embolism.

Dyspnea is a consequence of a combination of a restrictive lung defect, a ventilation-perfusion mismatch, and a decrease in cardiac output. Although large pleural effusions

reduce lung volume and are generally associated with dyspnea, the symptoms may be out of proportion to the size of the effusion, and patients with small to moderate effusions may also have shortness of breath if their baseline lung function is poor.²

Chest pain accompanying a pleural effusion suggests inflammation of the parietal pleura,⁶ but could be due to cancer in the chest wall and ribs—or to a benign disease of the thoracic wall such as rib fracture or costochondritis.

Pain of pleural origin can remain localized to the adjacent area of the chest, but sometimes it is referred to other areas. If the diaphragmatic pleura is involved, the pain is in many cases referred to the ipsilateral shoulder.⁵ Pain may also be referred to the abdomen.

Pleuritic chest pain is described as being worse with deep inspiration or when lying down. It is common in patients with pulmonary embolism, parapneumonic effusion, or viral pleurisy, but it can also occur in patients with pneumothorax or pericarditis. A dull, aching chest pain may be due to an underlying pleural malignancy.⁷

■ **PHYSICAL EXAMINATION: LONG TRADITION, FEW DATA**

Our knowledge of the role of physical examination in detecting pleural effusion is still based mostly on expert opinion and on small case series.^{8,9}

TABLE 2

Anecdotal physical signs of pleural effusion

| SIGN | DESCRIPTION |
|--|---|
| Skodaic resonance ¹⁴ | Area of hyperresonance above a pleural effusion |
| Succussion splash ¹⁶ | Splashing sound produced by violently shaking patients with hydropneumothorax |
| Grocco triangle ¹⁵ | Right-angle triangle of dullness found over the posterior region of the chest opposite a large pleural effusion |
| Garland triangle ¹¹ | Small area of resonance next to the spine found in patients with large unilateral pleural effusions |

TABLE 3

Findings of pleural effusion according to size

| FINDING | SIZE OF EFFUSION | | |
|--|------------------|------------------------|--------------------------------------|
| | < 300 mL | 300–1,500 mL | > 1,500 mL |
| Tachypnea | No | Present | Significant |
| Chest expansion | Normal | Decreased ^a | Significantly decreased ^a |
| Tactile fremitus | Normal | Decreased | Absent |
| Breath sounds | Vesicular | Decreased | Absent or bronchial |
| Contralateral tracheal or mediastinal shift^b | Absent | Absent | Present |
| Bulging intercostal spaces | No | Sometimes | Present |
| Egophony^c | No | Yes | Yes |

^aOn the affected side or, in cases of bilateral effusions, both hemithoraces

^bMediastinal shift opposite to the side of the effusion, typically detected on chest radiography

^cAt the upper part of the effusion

ADAPTED FROM CLINICS IN CHEST MEDICINE 1985; 6(1): 34. JAY SJ, DIAGNOSTIC PROCEDURES FOR PLEURAL DISEASE. COPYRIGHT ELSEVIER 1985.

Dyspnea may be out of proportion to the size of the pleural effusion

TABLE 1 lists the most common physical signs of pleural effusion^{10–15}; TABLE 2 lists some less common (anecdotal) signs.^{11,14–16} The sensitivities and specificities of the different signs in detecting pleural effusion have not been extensively studied. The limited data suggest that clinical acumen is less accurate than ultrasonography of the chest, but certain reports found it about as accurate as standard chest radiography.

Diacon et al¹⁷ assessed the accuracy of clinical examination and ultrasonography for selecting pleural puncture sites in 67 patients. Compared with ultrasonography as the gold standard, clinical examination had a sensitivity of 76%, a specificity of 60%, a positive predictive value of 85%, and a neg-

ative predictive value of 45%.

Patterson et al¹¹ prospectively compared physical examination (including auscultation, percussion, and tactile fremitus) with bedside ultrasonography and found that physical examination had a lower sensitivity (53% vs 80%, respectively) but a similar specificity (71%).

Bigger effusions are easier to detect

The physical findings are related to the volume of fluid in the pleural effusion and its effects on the chest wall, diaphragm, and lungs. Physical findings are generally normal if less than 300 mL of fluid is present, whereas large effusions (> 1,500 mL) can be associated with significant asymmetry of chest expansion and bulging of intercostal spaces.

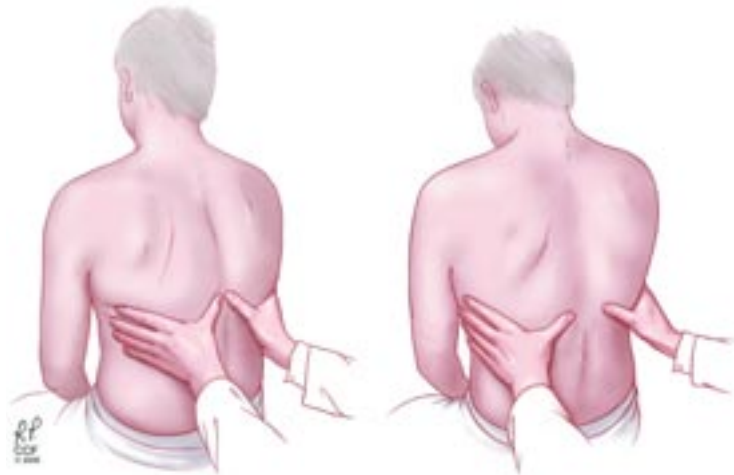

FIGURE 1. Palpation to detect asymmetry of chest expansion, a sign of pleural effusion.

TABLE 3 shows some of the common physical findings, depending on the amount of pleural fluid present.

Inspection

Although inspection of the chest is not very helpful in detecting a pleural effusion, it can provide other relevant information such as the respiratory rate and the breathing position adopted by the patient (patients with a large pleural effusion may have orthopnea); it can also reveal abnormalities in the shape of the thorax such as the increased anteroposterior diameter (“barrel shape”) seen in patients with chronic obstructive pulmonary disease.¹⁸

In addition, by inspection we can assess the expansion of the thorax. The utility of inspecting chest expansion to detect lung restriction was first noted by Laennec¹⁹ in 1821. A simple method of evaluating chest expansion is to place a measuring tape around the chest at the level of the nipples to compare the circumference at end-inspiration and at end-expiration.²⁰ In the absence of emphysema, the difference should be at least 2 inches. An expansion of 1.5 inches or less is considered abnormal.²¹ More relevant to pleural effusion than the amount of overall chest expansion is whether the expansion is symmetrical, which we can assess by palpation.

Palpation

Signs of pleural effusion that can be detected by palpation include asymmetric chest expansion and asymmetric tactile fremitus.

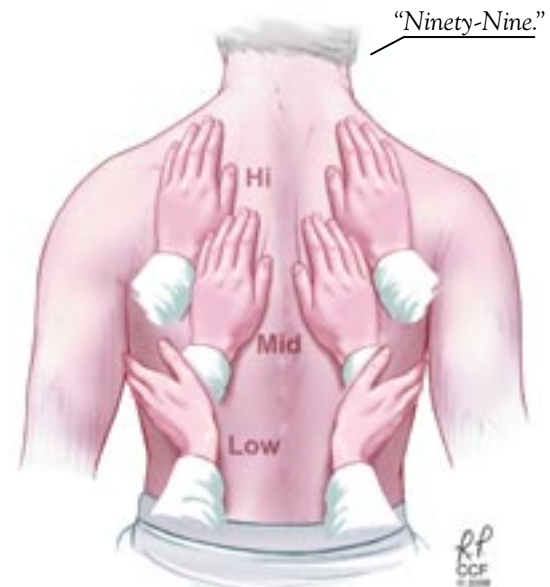


FIGURE 2. Tactile fremitus—the examiner asks the patient to say specific words repeatedly (eg, “ninety-nine”).

sion and asymmetric tactile fremitus.

Chest expansion can be evaluated by placing your hands on the patient’s back with your thumbs pointed towards the spine and asking the patient to breathe (FIGURE 1). In a recent study by Kalantri et al¹⁰ in 278 patients (of whom 57% had pleural effusions), asymmetric chest expansion had a sensitivity of 74% and a specificity of 91%. Furthermore, when the pretest probability of disease based on other clinical findings was applied, symmetrical chest expansion was associated with a very low probability (8%) of pleural effusion.

Tactile fremitus is defined as the vibration felt by the clinician’s hand resting on the chest wall of a patient (FIGURE 2).²² To elicit the sign, the clinician asks the patient to say specific words repeatedly (eg, “ninety-nine”). Asymmetry of tactile fremitus can be due to air, fluid, or tumors, and thus this sign is not specific for pleural effusion. Little information is available about its accuracy, although in the study by Kalantri et al,¹⁰ its sensitivity was 82%, its specificity was 86%, and its positive predictive value was low at 59%.

Other signs. Palpation of the chest can also help in detecting underlying disease of the thorax sometimes associated with pleurisy or pleural effusions. Chest wall tumors or skin abscesses may be related to underlying emphyse-

Small effusions can cause significant dyspnea if underlying lung disease is present

ma, localized tenderness may be associated with rib fractures or costochondritis, and crepitus may be due to subcutaneous emphysema.

Percussion

The chest can be percussed directly with the tips of the fingers of one hand or indirectly by placing a third finger against the surface to be percussed. There are two main techniques used to detect pleural effusions: comparative percussion and auscultatory percussion.

The comparative percussion technique involves comparing the sounds (dullness or hyperresonance) on the right vs the left hemithorax. Dullness may indicate pleural effusion (FIGURE 3). This is the technique introduced in the 18th century by Auenbrugger and Forbes,²³ who proposed that dullness is always present in a pleural effusion, although it may be difficult to detect if the effusion is bilateral.²⁴

Since other conditions such as consolidation of the lung and atelectasis can also be associated with dullness to percussion, some authors advocate percussion in the lateral supine position to detect a shift in the dullness that would indicate movement of fluid in the chest.²⁵

The sensitivity of comparative chest percussion and its accuracy related to the size of the effusion are unknown. Kalantri et al¹⁰ found that dullness to percussion had a positive predictive value of only 55% but a negative predictive value of 97%, suggesting that the absence of the sign is very helpful in ruling out an effusion.

According to classic textbook descriptions,²⁶ percussive sounds penetrate a maximum of 6 cm (2 cm of body wall thickness and 4 cm of lung), and at least 500 mL of fluid must be present in order to be able to detect an effusion by physical examination.^{2,8} Most of these descriptions are based on original studies done in cadavers more than 100 years ago.

The auscultatory percussion technique was first described by Laennec and used to delineate the size of several organs by placing the stethoscope directly above the structure to be outlined, followed by percussion from the periphery towards the organ of interest. The original technique was subsequently modified for the examination of the chest by Guarino.²⁷

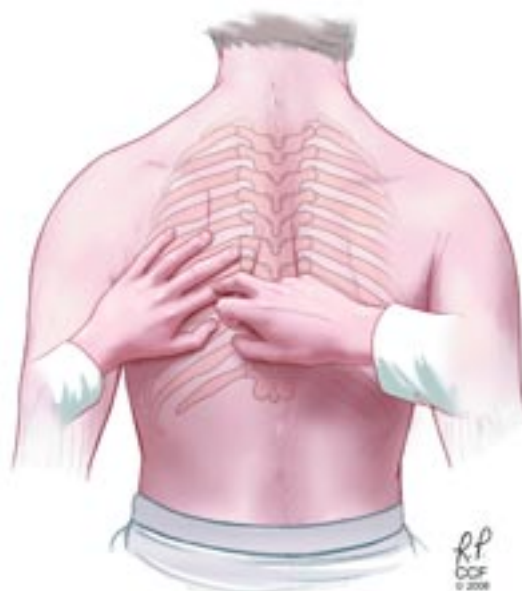

FIGURE 3. Chest percussion—the examiner taps the patient’s chest on alternating sides to detect the characteristic dullness of pleural effusion.

This method consists of tapping lightly the manubrium sterni with the distal phalanx of the index or middle finger while listening over the posterior chest wall with a stethoscope (FIGURE 4). The patient must be in the sitting or standing position with the arms resting at the sides or on the thighs. Percussion is applied with equal intensity over the manubrium sterni while the physician auscultates each posterior hemithorax from top to bottom, comparing the sounds on the two sides and trying to identify dullness to percussion.

In the original description, percussion was limited to the manubrium in an attempt to avoid other solid structures (such as the left ventricle) that would interfere with the transmission of the sounds.²⁷ The authors modified this technique for the detection of pleural effusion (FIGURE 5): with the patient sitting up and his or her back facing the examiner, a stethoscope is placed approximately 3 cm below the last rib in the mid-scapular line. The physician then proceeds to percuss with his or her free hand (by finger flicking or the pulp of a finger) along three or more parallel lines from the apex of each hemithorax perpendicularly downward toward the base to

Pleuritic chest pain is worse with deep inspiration or when lying down

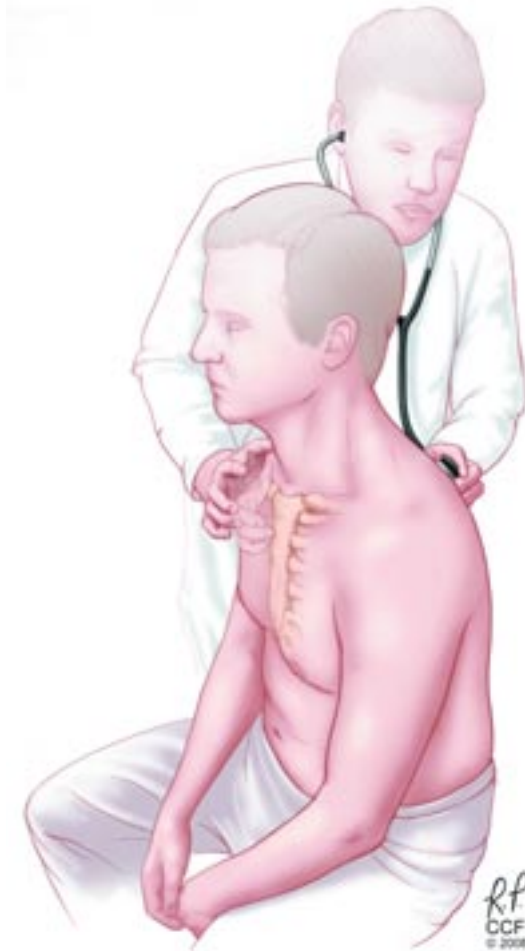

FIGURE 4. Auscultatory percussion: the examiner taps on the patient's manubrium while listening with a stethoscope to the patient's back.

identify dullness to percussion.¹²

Although auscultatory percussion was used initially to try to detect lung lesions, masses and consolidations, Guarino and Guarino¹² found this technique to be highly effective in detecting pleural effusion. In a prospective blinded study in 118 patients, this method was highly (95%) sensitive and 100% specific in detecting pleural effusion, even in patients with obesity, pneumonia, or other pleural abnormalities. Of note, their findings suggested that auscultatory percussion can detect as little as 50 mL of pleural fluid.

Bohadana et al¹³ compared auscultatory and conventional percussion with chest radiographic findings in 281 patients. They found that auscultatory percussion was 100% sensi-

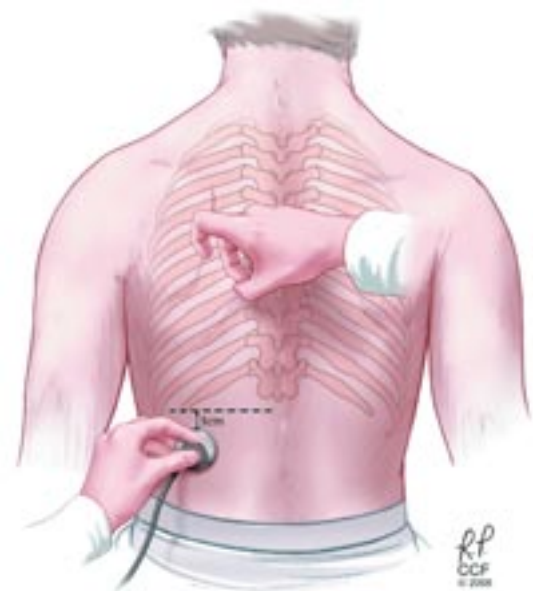


FIGURE 5. Guarino's second method of auscultatory percussion.

tive for detecting large pleural effusions.

However, when Bourke et al¹⁴ compared conventional and auscultatory percussion in 21 patients with abnormal radiographs, both methods had low sensitivity (15.4% vs 19.2%) but high specificity (97.3% vs 85.1%, respectively). It is important to mention that in this series only a few patients had a pleural effusion.

McDermott et al¹⁶ compared conventional and auscultatory percussion in detecting pleural effusion in 14 hospitalized patients, using ultrasonography instead of chest radiography as the gold standard for comparison. The findings on auscultatory percussion correlated better with the findings on ultrasonography than did those on conventional percussion. The authors gave no information about sensitivity or specificity.

Kalantri et al¹⁰ found that auscultatory percussion had a sensitivity of 58% and a specificity of 85%.

Auscultation

Originally described by Laennec (who invented the stethoscope),¹⁹ auscultation is perhaps the physical examination technique most used to detect pleural effusion.

Lichtenstein et al¹⁵ performed a study of auscultation in critically ill patients and found

In critically ill patients, auscultation was as sensitive as radiography

it to have a very low sensitivity (42%) but a higher specificity (90%), with an overall diagnostic accuracy of 60%. Of note, compared with chest radiography, auscultatory findings had similar sensitivity but higher accuracy.

Absent or diminished breath sounds strongly suggest an effusion.¹⁹

Egophonism. Laennec also described egophonism as a pathognomonic sign associated with a moderate degree of effusion. The word egophony comes from the Greek “ego,” which means goat; it is used to describe the change in the pronounced sound of E to A. The mechanism responsible for finding this sign in massive pleural effusions is probably upward displacement and compression or consolidation of the lung at the top of the effusion.

However, if the effusion is small, the consolidation will not be large enough to produce this sign. Similarly, other lung con-

ditions associated with large consolidations may produce egophonism without a pleural effusion. Little is known about the predictive value of this sign, and significant interobserver variability needs to be taken into account.²⁸

Pleural rub. Pleural effusions that result from any disease that causes direct inflammation of the pleurae can be associated with a pleural rub. This sound, classically described as rubbing of uncoiled leather, is pathognomonic of pleural disease but not of pleural effusion. In fact, a pleural rub will disappear once an effusion develops. Little is known about the accuracy of this finding; in the study by Kalantri et al it had a very low sensitivity (5%) but a very high specificity (99%).¹⁰ The differential diagnosis includes pleuritis, pneumonia, mesothelioma, and tumors that metastasize to the pleura. ■

■ REFERENCES

- Noppen M, De Waele M, Li R, et al. Volume and cellular content of normal pleural fluid in humans examined by pleural lavage. *Am J Respir Crit Care Med* 2000; 162:1023–1026.
- Bouros D. *Pleural Disease*. New York: Marcel Dekker, 2004.
- Light RW. Parapneumonic effusions and empyema. *Proc Am Thorac Soc* 2006; 3:75–80.
- Light RW. Clinical practice. Pleural effusion. *N Engl J Med* 2002; 346:1971–1977.
- Light RW. *Pleural Diseases*, 5th ed. Philadelphia: Lippincott Williams & Wilkins, 2007.
- Moore KL, Dalley AF, Agur AMR. *Clinically Oriented Anatomy*. 5th ed. Philadelphia: Lippincott Williams & Wilkins, 2006.
- Marel M, Stastny B, Melinova L, Svandova E, Light RW. Diagnosis of pleural effusions. Experience with clinical studies, 1986 to 1990. *Chest* 1995; 107:1598–1603.
- Leopold SS, Hopkins HU. *Leopold's Principles and Methods of Physical Diagnosis*, 3d ed. Philadelphia: W.B. Saunders, 1965.
- Norris GW, Landis HRM, Montgomery CM, Krumbhaar EB. *Diseases of the Chest and the Principles of Physical Diagnosis*, 4th ed, rev. Philadelphia, W.B. Saunders, 1929.
- Kalantri S, Joshi R, Lokhande T, et al. Accuracy and reliability of physical signs in the diagnosis of pleural effusion. *Respir Med* 2007; 101:431–438.
- Patterson LA, Costantino TG, Satz WA. Diagnosing pleural effusion: a prospective comparison of physical examination with bedside ultrasonography [abstract]. *Ann Emerg Med* 2004; 44:S112.
- Guarino JR, Guarino JC. Auscultatory percussion: a simple method to detect pleural effusion. *J Gen Intern Med* 1994; 9:71–74.
- Bohadana AB, Coimbra FT, Santiago JR. Detection of lung abnormalities by auscultatory percussion: a comparative study with conventional percussion. *Respiration* 1986; 50:218–225.
- Bourke S, Nunes D, Stafford F, Hurley G, Graham I. Percussion of the chest re-visited: a comparison of the diagnostic value of auscultatory and conventional chest percussion. *Ir J Med Sci* 1989; 158:82–84.
- Lichtenstein D, Goldstein I, Mourgeon E, Cluzel P, Grenier P, Rouby JJ. Comparative diagnostic performances of auscultation, chest radiography, and lung ultrasonography in acute respiratory distress syndrome. *Anesthesiology* 2004; 100:9–15.
- McDermott TD, McCarthy M, Chestnut T, Schumann L. A comparison of conventional percussion and auscultation percussion in the detection of pleural effusions of hospitalized patients. *J Am Acad Nurse Pract* 1997; 9:483–486.
- Diacon AH, Brutsche MH, Soler M. Accuracy of pleural puncture sites: a prospective comparison of clinical examination with ultrasound. *Chest* 2003; 123:436–441.
- Pierce JA, Ebert RV. The barrel deformity of the chest, the senile lung and obstructive pulmonary emphysema. *Am J Med* 1958; 25:13–22.
- Laennec RTH. *A Treatise On the Disease[s] of the Chest*. New York: Library of the New York Academy of Medicine and Hafner Publishing Company, 1962.
- Bockenbauer SE, Chen H, Julliard KN, Weedon J. Measuring thoracic excursion: reliability of the cloth tape measure technique. *J Am Osteopath Assoc* 2007; 107:191–196.
- Fries JF. The reactive enthesopathies. *Dis Mon* 1985; 31(1):1–46.
- McGee SR. *Evidence-based physical diagnosis*. Philadelphia: W.B. Saunders, 2001.
- Auenbrugger L, Forbes J. On percussion of the chest: being a translation of Auenbrugger's original treatise entitled “Inventum novum ex percussione thoracis humani, ut signo abstrusus interni pectoris morbos detegendi” (Vienna, 1761). Baltimore: The Johns Hopkins Press, 1936.
- Auenbrugger L, Neuburger M. *Inventum Novum*. London: Reprinted for Dawsons of Pall Mall, 1966.
- Gilbert VE. Shifting percussion dullness of the chest: a sign of pleural effusion. *South Med J* 1997; 90:1255–1256.
- Weil A. *Handbuch und Atlas der topographischen Percussion nebst einer Darstellung der Lehre vom Percussionsschall*. Leipzig: Vogel, 1880.
- Guarino JR. Auscultatory percussion, a new aid in the examination of the chest. *J Kansas Med Soc* 1974; 75:193–194.
- Sapira JD. About egophony. *Chest* 1995; 108:865–867.

ADDRESS: Marie M. Budev, DO, MPH, Department of Pulmonary and Critical Care Medicine, A90, Cleveland Clinic, 9500 Euclid Avenue, Cleveland, OH 44195; e-mail budevmm@ccf.org.