

TABLE OF CONTENTS

FROM THE EDITOR

Identifying and classifying myocardial infarctions 150

In this issue of the *Journal*, Drs. Shaun Senter and Gary Francis discuss the power of electrocardiographic changes and creatine kinase-MB and troponin elevations in diagnosing acute myocardial infarction. These are not perfect tests.

B.F. MANDELL

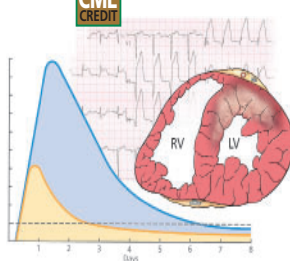
THE CLINICAL PICTURE.....

Unilateral cotton wool spots: An important clue 155

The patient has sudden loss of vision in one eye and unilateral cotton wool spots on funduscopy. What is the cause?

T. THIYAGARAJAN, H. ELKAMBERGY, V. MAHAJAN, AND P. KUMARAGURU

CME CREDIT REVIEW



A new, precise definition of acute myocardial infarction 159

The updated definition includes subtypes of acute MI, imaging studies supporting the diagnosis, and biomarker thresholds after percutaneous coronary intervention and coronary artery bypass grafting.

S. SENTER AND G.S. FRANCIS

CME CREDIT REVIEW

Psychiatric symptoms of dementia: Treatable, but no silver bullet 167

Your 84-year-old patient's son is distraught. "I know Mom has dementia, but I don't understand why she cannot relax. Please give her a pill."

W. SCHWAB, B. MESSINGER-RAPPORT, AND K. FRANCO

CME CREDIT IMAGING IN PRACTICE

The radiologic workup of a palpable breast mass 175

The discovery of a breast mass is a common occurrence, and it is distressing for any woman. The choice of initial imaging study is most often guided by the patient's age.

L. STEIN AND M. CHELLMAN-JEFFERS

CONTINUED ON PAGE 148

CLEVELAND CLINIC JOURNAL OF MEDICINE

EDITORIAL STAFF

BRIAN F. MANDELL, MD, PhD *Editor-in-Chief*
PHILLIP E. CANUTO *Executive Editor*
RAY BORAZANIAN *Managing Editor*
DAVID A. HUDDLESTON *Manuscript Editor*
JOSEPH A. PANGRACE *Medical Art Director*
AMY SLUGG MOORE *Patient Education Editor*

PUBLISHING OPERATIONS

PETER G. STUDER *Executive Publisher*
KRISTI THOMSEN *Exec. Editor, Special Assignments*
BRUCE M. MARICH *Production Manager*
IRIS TRIVILINO *Department Coordinator*
LAURIE WEISS *Accountant (Billing)*

CUSTOM PROGRAMS

GLENN R. CAMPBELL *Executive Editor*
KATHY DUNASKY *Production Manager*

ASSOCIATE EDITORS

ALEJANDRO C. ARROLIGA, MD
ARMAN T. ASKARI, MD
DANIEL J. BROTMAN, MD
WILLIAM D. CAREY, MD
RUTH M. FARRELL, MD, MA
GARY FRANCIS, MD
KATHLEEN FRANCO-BRONSON, MD
STEVEN M. GORDON, MD
BRIAN GRIFFIN, MD
AMIR JAFFER, MD
MANDY C. LEONARD, PharmD
ANGELO A. LICATA, MD, PhD
ATUL C. MEHTA, MD
FRANKLIN A. MICHOTA, MD
ROBERT M. PALMER, MD
HATAYA POONYAGARIYAGORN, MD
BERNARD J. SILVER, MD
RACHEL M. TALIERCIO, DO
ALEXANDRA VILLA-FORTE, MD, MPH

DONALD G. VIDT, MD
WILLIAM S. WILKE, MD
MARC WILLIAMS, MD

EDITORS EMERITI

JOHN D. CLOUGH, MD
HERBERT P. WIEDEMANN, MD
JAMES S. TAYLOR, MD

CLEVELAND CLINIC

DELOS M. COSGROVE, MD
President and Chief Executive Officer

CLEVELAND CLINIC

EDUCATION INSTITUTE
BRIAN F. MANDELL, MD, PhD
Acting Chairman
PHILLIP R. GARD
Administrator

REPRINTS: Laurie Weiss 216-444-2661 E-mail ccjm@ccf.org

Cleveland Clinic Journal of Medicine [ISSN 0891-1150 (print), ISSN 1939-2869 (online)] is published monthly by Cleveland Clinic from editorial offices at 9500 Euclid Avenue, Cleveland, OH 44195. Periodicals postage paid at Cleveland, OH, and at additional mailing offices. POSTMASTER: Send address changes to the *Cleveland Clinic Journal of Medicine*, NA32, 9500 Euclid Avenue, Cleveland, OH 44195.

STATEMENTS AND OPINIONS expressed in the *Cleveland Clinic Journal of Medicine* are those of the authors and not necessarily of Cleveland Clinic or its Board of Trustees.

SUBSCRIPTION RATES: U.S. and possessions: personal \$115; institutional \$143; single copy/back issue \$20. Foreign: \$160; single copy/back issue \$20. Institutional (multiple-reader rate) applies to libraries, schools, hospitals, and federal, commercial, and private institutions and organizations. Individual subscriptions must be in the names of, billed to, and paid by individuals.

SUBSCRIPTIONS, EDITORIAL, BILLING/ACCOUNTING, AND PRODUCTION: (same address as above) • Phone (216) 444-2661 • Fax (216) 444-9385 • E-mail ccjm@ccf.org • Web site www.ccjm.org

ADVERTISING: Joseph Dennehy, Director, Sales and Marketing, 120 Castle Ridge Rd, Manhasset, NY 11030 • Phone (516) 365-8640 • Fax (516) 365-0587 • E-mail jjoedenney@verizon.net

AUTHORIZATION TO PHOTOCOPY items for internal or personal use is granted by the *Cleveland Clinic Journal of Medicine* [ISSN 0891-1150 (print), ISSN 1939-2869 (online)], published by Cleveland Clinic, provided that the appropriate fee is paid directly to Copyright Clearance Center, 222 Rosewood Drive, Danvers, MA 01923 USA 978-750-8400. Prior to photocopying items for educational classroom use, please contact Copyright Clearance Center, Inc., at the address above. For permission to reprint material, please fax your request with complete information to the Reproduction department at CCC, fax (978) 750-4470. For further information visit CCC online at www.copyright.com. To order bulk reprints, see above.

DISCLAIMER: The information in this educational activity is provided for general medical education purposes only and is not meant to substitute for the independent medical judgment of a physician relative to diagnostic and treatment options of a specific patient's medical condition. The viewpoints expressed in this CME activity are those of the authors. They do not represent an endorsement by The Cleveland Clinic Foundation. In no event will The Cleveland Clinic Foundation be liable for any decision made or action taken in reliance upon the information provided through this CME activity.

COPYRIGHT © 2009 THE CLEVELAND CLINIC FOUNDATION. ALL RIGHTS RESERVED. PRINTED IN U.S.A.

AMM

BPA
WORLDWIDE

CONTINUED FROM PAGE 146



REVIEW

**Optic neuritis and risk of MS:
Differential diagnosis and management** **181**

Optic neuritis, a demyelinating inflammatory condition that causes acute vision loss, is associated with multiple sclerosis. Recognizing its classic clinical manifestations early is important so that diagnostic testing and treatment can be started.

B.J. OSBORNE AND N.J. VOLPE

IM BOARD REVIEW

A 43-year-old woman with chest pressure **191**

She has acute chest discomfort, a 25-pack-year smoking history, and a family history of myocardial infarction and deep vein thrombosis. What is the cause of her symptoms?

D. MICKELSON, E.N. MADY, AND K. TENG

CARDIOVASCULAR BOARD REVIEW

**A 37-year-old man with chest pain,
ECG changes, and elevated cardiac enzymes** **199**

He has had chest pain and dyspnea for the past few months, but now they are worse. What is the most likely cause?

A. AGHEL AND R.A. KRASUSKI

DEPARTMENTS

Letters to the editor **152**

Hyperthyroidism or thyrotoxicosis?

Shingles vaccine

CME calendar **205**

About our CME Self-test Online **206**

To receive CME credit, read the selected articles in this issue and then go online to take the test. It should take about 1 hour and 30 minutes to complete this activity. Release date: March 1, 2009. Expiration date: February 28, 2010.

UPCOMING FEATURES

■ **How do omega-3 fatty acids improve heart health?**

■ **Advance care planning:
Beyond the living will**

■ **How much does pregabalin help in fibromyalgia?**

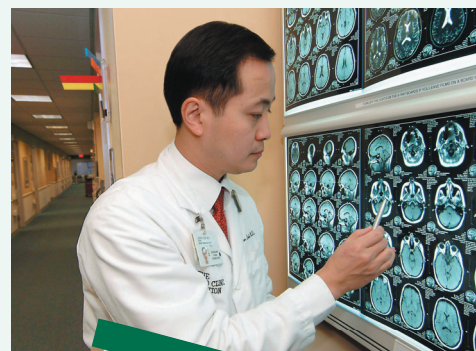■ **What is the value of measuring serum ammonia in hepatic encephalopathy?**

■ **Diseases from pet birds**

■ **Small-fiber neuropathy:
A burning problem**

■ **When to image a suspected rib fracture**

■ **A 72-year-old man with a purpuric rash**



DEDICATED TO LIFELONG LEARNING
**CLEVELAND
CLINIC
JOURNAL OF
MEDICINE**