

THE CLINICAL PICTURE

THANIGAIAR SU THIYAGARAJAN, MD
Department of Internal Medicine, St. Vincent Mercy
Medical Center, Toledo, OH

HUSSAM ELKAMBERGY, MD
St. Vincent Mercy Medical Center,
Toledo, OH

VIJAY MAHAJAN, MD
Program Director, Department of Internal
Medicine, St. Vincent Mercy Medical
Center, Toledo, OH

PRIYA KUMARAGURU, MD
St. Vincent Mercy Medical Center,
Toledo, OH

The Clinical Picture

Unilateral cotton wool spots: An important clue

A 54-YEAR-OLD MAN PRESENTS with sudden visual loss in the left eye. The left eye and left periorbital area have been painful for the past 5 days.

Funduscopy examination of the left eye reveals multiple cotton wool spots in the peripapillary area (FIGURE 1). The visual acuity is 20/200. The right eye appears normal, with normal vision.

Duplex ultrasonography of the carotid arteries shows total occlusion of the left internal carotid artery. Fluorescein angiography of the fundus reveals focal hyperfluorescence with delayed arteriovenous transit time in the left eye.

Q: Which of the following diagnoses is the most likely at this point in the evaluation?

- Hypertensive retinopathy
- Diabetic retinopathy
- Human immunodeficiency virus (HIV) retinopathy
- Retinal involvement of systemic autoimmune disease
- Ocular ischemic syndrome

A: The ocular symptoms of hypertension, diabetes mellitus, HIV infection, and other autoimmune diseases usually present bilaterally, and funduscopy examination often reveals other signs such as vessel tortuosity, venous dilation, microaneurysms, retinal hemorrhages, hard exudates, and new vessel formation, in addition to cotton wool spots. In this patient, the lack of these signs and the unilateral cotton wool spots combined with the delay in arteriovenous transit time on fluorescein angiography point to ocular ischemic syndrome.

Ocular ischemic syndrome is the result of hypoperfusion of the globe caused by obstruction of the carotid or the ophthalmic artery,¹ most commonly from atherosclerosis. Retinal hypoperfusion is also caused by arteritis, external compression, dissection of the artery,² and, rarely, cardiac failure.

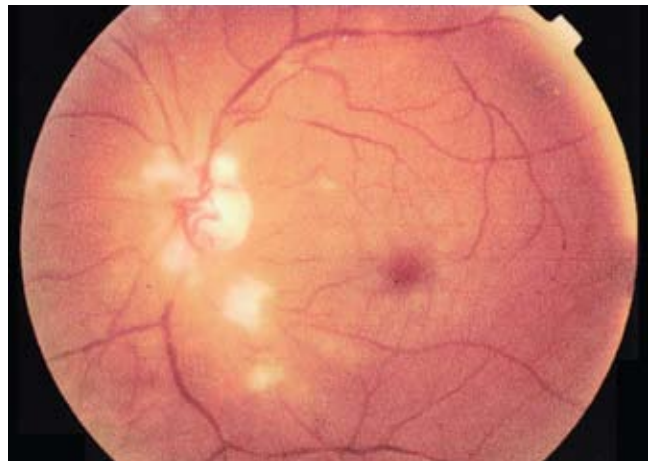


FIGURE 1. Multiple cotton wool spots in the peripapillary area in the left eye.

■ USUAL SIGNS AND SYMPTOMS

Usually, the patient presents with visual loss that has progressed gradually over a period of weeks or months and is associated with dull aching in the eye or orbit (“ocular angina”).³ Cotton wool spots on funduscopy examination represent retinal nerve fiber layer infarcts, a sign of retinal hypoperfusion. Delays in the choroidal filling time and the arteriole-to-venule transit time on fluorescein angiography confirm the diagnosis.

Strong clue to underlying disease

Ocular ischemic syndrome is an important clue to underlying macrovascular atherosclerotic disease: 50% of patients with ocular ischemic syndrome have ischemic heart disease, 25% have a history of stroke, and 20% have severe peripheral vascular disease. Ocular complications of the syndrome are rubeosis iridis, neovascular glaucoma, and neovascularization of the optic disc and retina. Prompt diagnosis is very important because the death rate at 5 years is 40%.⁴

doi:10.3949/ccjm.76a.08036

Recommended workup

The recommended workup is a thorough history and physical examination to identify underlying systemic disease such as diabetes, hypertension, or collagen vascular disease. When carotid artery disease is suspected, a noninvasive vascular workup with carotid duplex ultrasonography is mandatory to confirm carotid arterial disease, to establish its cause, and to assess the severity of the lesion.

CURRENT TREATMENT OPTIONS

Treatment focuses on the control of systemic risk factors and follow-up to monitor for systemic and ocular complications. The combination of aspirin and extended-release dipyridamole (Aggrenox) is currently considered the most effective antiplatelet strategy, as it reduces the risk of stroke by 37% compared with 25% with aspirin alone.⁵

Carotid endarterectomy has been shown to benefit symptomatic patients with nondisabling stroke, amaurosis fugax, and a hemispheric transient ischemic attack and who have carotid stenosis of 70% to 99%. The North American Symptomatic Carotid En-

arterectomy Trial found a 2-year stroke rate of 9% in such patients who underwent endarterectomy vs 26% in those treated with antiplatelet therapy alone.^{6,7} Some improvement in visual outcomes was also noted, but the data so far are not conclusive.⁶

Bypass procedures such as anastomosis of the superficial temporal artery to the middle cerebral artery have been tried in patients with 100% obstruction of the carotid artery in whom a thrombus has propagated distally, thus precluding endarterectomy.

We continue to monitor our patient for the development of ocular complications. The development of retinal neovascularization may warrant panretinal photocoagulation with or without anterior retinal cryoablation. Panretinal photocoagulation decreases the retinal demand for oxygen and decreases the release of angiogenic factors, thereby arresting the growth of neovascularization and preventing complications such as vitreous hemorrhage and tractional retinal detachment. Although no studies have analyzed the benefit of panretinal photocoagulation in patients with ocular ischemia, its long-term benefit has been well documented in diabetic patients.⁸ ■

Ocular ischemic syndrome is a clue to serious, underlying atherosclerosis

REFERENCES

1. **Chen CS, Miller NR.** Ocular ischemic syndrome: review of clinical presentations, etiology, investigation, and management. *Compr Ophthalmol Update* 2007; 8:17–28.
2. **Hussain N, Falali S, Kaul S.** Carotid artery disease and ocular vascular disorders. *Indian J Ophthalmol* 2001; 49:5–14.
3. **Brown GC, Magargal LE.** The ocular ischemic syndrome. Clinical, fluorescein angiographic and carotid angiographic features. *Int Ophthalmol* 1988; 11:239–251.
4. **Sivalingham A, Brown GC, Magaragal LE, Menduke H.** The ocular ischemic syndrome, II; mortality and systemic morbidity. *Int Ophthalmol* 1989; 13:187–191.
5. **Diener HC, Cundha L, Forbes C, Sivenius J, Smets P, Lowenthal A.** European Stroke Prevention Study 2: dipyridamole and acetylsalicylic acid in the secondary prevention of stroke. *J Neurol Sci* 1996; 143:1–13.
6. **Barnett HJ, Taylor DW, Eliasziw M, et al.** Benefit of carotid endarterectomy in patients with symptomatic moderate or severe stenosis. *N Engl J Med* 1998; 339:1415–1425.
7. **Wolintz RJ.** Carotid endarterectomy for ophthalmic manifestations: is it ever indicated? *J Neuroophthalmol* 2005; 25:299–302.
8. **Chew EY, Ferris FL 3rd, Csaky KG, et al.** The long-term effects of laser photocoagulation treatment in patients with diabetic retinopathy: the Early Treatment Diabetic Retinopathy Follow-up Study. *Ophthalmology* 2003; 110:1683–1689.

ADDRESS: Thanigaiarsu Thiyagarajan, MD, Department of Internal Medicine, St. Vincent Mercy Medical Center, 2213 Cherry Street, Toledo, OH 43608; e-mail thanigaiarsu@gmail.com.