



EDUCATIONAL OBJECTIVE: Readers will include ischemic colitis in the differential diagnosis when assessing patients with abdominal pain or bloody stools

KAREEM ELDER, MD

Department of Internal Medicine,
Collinwood Health Center,
Cleveland, OH

BRET A. LASHNER, MD

Department of Gastroenterology and
Hepatology, Cleveland Clinic

FIRAS AL SOLAIMAN, MD

Department of Cardiovascular Medi-
cine, Cleveland Clinic

Clinical approach to colonic ischemia

ABSTRACT

Typical clinical manifestations of colonic ischemia include rapid onset of mild abdominal pain and tenderness over the affected bowel, followed by a mild amount of hematochezia within a day of the onset of pain. Most patients have transient, nongangrenous ischemia, but some have severe ischemia.

KEY POINTS

The incidence of colonic ischemia is difficult to ascertain, as most cases are transient and either not reported or misdiagnosed.

Most cases are in the elderly.

The clinical presentation is not specific, as other conditions also present with abdominal pain and hematochezia.

The most common mechanisms are hypotension and hypovolemia caused by dehydration or bleeding that results in systemic hypoperfusion.

Endoscopy has become the diagnostic procedure of choice.

Although most patients can be treated conservatively with intravenous fluids, bowel rest, and antibiotics, some develop peritonitis or clinically deteriorate and require surgery.

ISCHEMIC COLITIS is one of the diagnoses that should be considered when patients present with abdominal pain, diarrhea, and intestinal bleeding (others are infectious colitis, inflammatory bowel disease, diverticulitis, and colon cancer). Its incidence is difficult to determine, as many mild cases are transient and are either not reported or misdiagnosed. However, it is the most common type of intestinal ischemia¹ and is responsible for an estimated 1 in 2,000 hospital admissions.²

In this review, we review the main causes of and risk factors for colonic ischemia and discuss how to diagnose and treat it.

BLOOD SUPPLY IS TENUOUS IN 'WATERSHED' AREAS

The superior and inferior mesenteric arteries have an extensive network of collateral blood vessels at both the base and border of the mesentery, called the arch of Riolan and the marginal artery of Drummond, respectively.

During systemic hypotension, ischemic injury most often occurs at "watershed" areas, where the collateral arteries are small and narrow. These involve the terminal branches of the superior mesenteric artery supplying the splenic flexure and those of the inferior mesenteric artery supplying the rectosigmoid junction. (FIGURE 1).^{3,4} Although any area of the colon can be affected, approximately 75% of cases involve the left colon, and nearly 25% involve the splenic flexure.⁵

MANY POSSIBLE CAUSES AND FACTORS

Colonic ischemia is caused by a diminution of the colonic blood supply that is so severe that

TABLE 1

Causes of ischemic colitis

Systemic hypoperfusion

- Cardiac failure
- Septic shock
- Hemorrhagic shock
- Pancreatitis
- Hypovolemia
 - Diuretics
 - Hemodialysis
 - Long-distance running
- Major cardiovascular surgery
 - Coronary artery bypass grafting
 - Aorta repair
- Snake venom
- Anaphylaxis

Thrombosis or embolism

- Congenital hypercoagulable state
 - Factor V Leiden mutation
 - Prothrombin G20210A mutation
 - Protein C or S deficiency
 - Antithrombin III deficiency
- Acquired hypercoagulable state
 - Antiphospholipid syndrome
 - Anticardiolipin antibodies
 - Lupus anticoagulant
 - Disseminated intravascular coagulation
 - Oral contraceptive pills
 - Paroxysmal nocturnal hemoglobinuria
- Arterial emboli (cardiac)
- Cholesterol emboli

Small-vessel disease

- Atherosclerosis
- Diabetes
- Hypertension
- Hyperlipidemia
- Vasculitis
 - Systemic lupus erythematosus
 - Polyarteritis nodosa
 - Wegener granulomatosis
- Rheumatoid arthritis
- Radiation
- Amyloidosis

Iatrogenic

- Surgical
 - Colectomy with inferior mesenteric artery ligation
 - Endoscopic retrograde cholangiopancreatography-related mesenteric hematoma
- Drugs
 - Alosetron (Lotronex)
 - Antihypertensive drugs
 - Digoxin
 - Cocaine
 - Interferon-ribavirin
 - Nonsteroidal anti-inflammatory drugs
 - Pseudoephedrine
 - Psychotropic drugs
 - Vasopressors

Right-sided ischemic colitis tends to be more severe than left-sided ischemic colitis

metabolic demands are not met. This diminution is most often the result of a decrease in systemic perfusion or an anatomic occlusion. Although it can be associated with many medical and surgical conditions (TABLE 1), a specific cause cannot be determined in most cases.

Age. Ischemic colitis most often occurs in elderly people; the average age is 70 years.⁶ Binns and Isaacson⁷ suggest that age-related tortuosity of the colonic arteries increases vascular resistance and contributes to colonic ischemia in elderly patients.

Hypotension and hypovolemia are the most common mechanisms of colonic ischemia. Hypotension can be due to sepsis or impaired left ventricular function, and hypovolemia can be caused by dehydration or bleeding. These result in systemic hypoperfusion, triggering a mesenteric vasoconstrictive

reflex. Once the hypoperfusion resolves and blood flow to the ulcerated portions resumes, bleeding develops from reperfusion injury.⁸

Cardiac thromboembolism can also contribute to colonic ischemia. Hourmand-Ollivier et al⁹ found a cardiac source of embolism in almost one-third of patients who had ischemic colitis, suggesting the need for routine screening with electrocardiography, Holter monitoring, and transthoracic echocardiography.

Myocardial infarction. Cappell¹⁰ found, upon colonoscopic examination, that about 14% of patients who developed hematochezia after a myocardial infarction had ischemic colitis. These patients had more complications and a worse in-hospital prognosis than did patients who had ischemic colitis due to other causes.¹¹

Why some areas of the colon are prone to ischemia

The colon is protected from ischemia by a collateral blood supply via the marginal artery of Drummond, a system of arcades connecting the major arteries. The anatomy is highly variable, however, and certain areas are more vulnerable in some people.

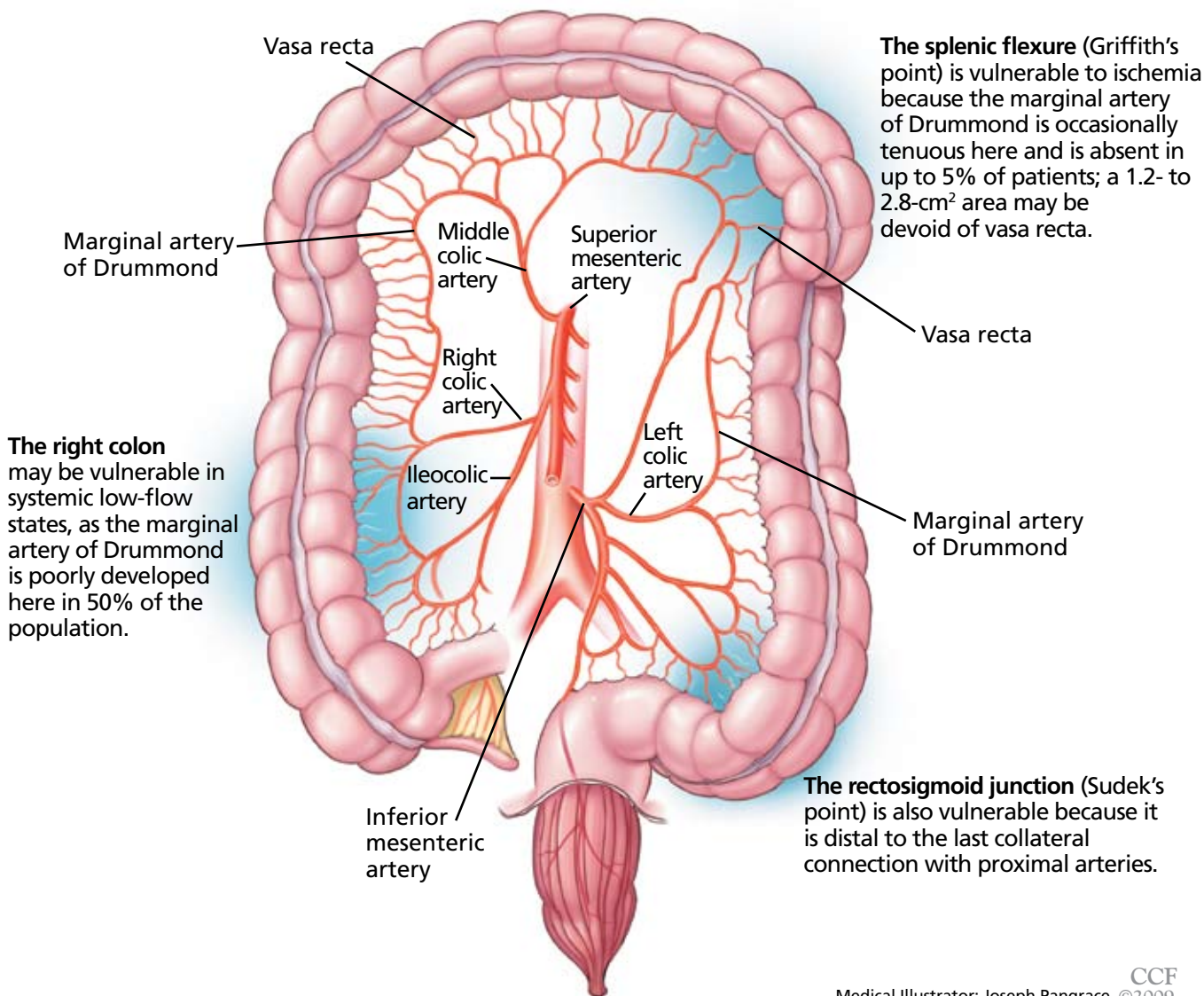


FIGURE 1. The arteries supplying the large intestine. In spite of an extensive network of collateral arteries, the watershed areas between major arteries are vulnerable to hypoperfusion.

FROM BAIXAULI J, KIRAN RP, DELANEY CP. INVESTIGATION AND MANAGEMENT OF ISCHEMIC COLITIS. CLEVE CLIN J MED 2003; 70:920-934.

Major vascular surgical procedures can disrupt the colonic blood supply, and in two case series,^{12,13} up to 7% of patients who underwent endoscopy after open aortoiliac reconstructive surgery had evidence of ischemic colitis. In other series,^{14,15} the segment most often affected was the distal left colon, and the

cause was iatrogenic ligation of the inferior mesenteric artery or intraoperative hypoperfusion in patients with chronic occlusion of this artery. Endovascular repair of aortoiliac aneurysm also carries a risk of ischemic colitis, though this risk is smaller (< 2%).¹⁶

Hypercoagulable states. The role of ac-

quired or hereditary hypercoagulable states in colonic ischemia has not been extensively investigated and remains poorly understood.

Conditions that increase clotting can cause thrombotic occlusion of small vessels that supply the colon, leading to ischemia. In small retrospective studies and case reports,¹⁷⁻²⁶ 28% to 74% of patients who had ischemic colitis had abnormal results on tests for protein C deficiency, protein S deficiency, antithrombin III deficiency, antiphospholipid antibodies, the factor V Leiden mutation, and the prothrombin G20210A mutation. However, in what percentage of cases the abnormality actually caused the ischemic colitis remains unknown.

Arnott et al²⁷ reported that 9 of 24 patients with ischemic colitis had abnormal results on testing for hypercoagulable conditions. Three patients had mildly persistent elevation in anticardiolipin antibodies, but none had the factor V Leiden mutation or a deficiency of protein C, protein S, or antithrombin.

Koutroubakis et al²⁰ reported significantly higher prevalences of antiphospholipid antibodies and heterogeneity for the factor V Leiden mutation in 35 patients with a history of ischemic colitis than in 18 patients with diverticulitis and 52 healthy controls (19.4% vs 0 and 1.9%, 22.2% vs 0 and 3.8%, respectively). Overall, 26 (72%) of 36 patients had at least one abnormal hypercoagulable test result.

Most patients with ischemic colitis are relatively old (over 60 years), and many have multiple concomitant vascular risk factors, suggesting that many factors contribute to ischemic colitis and that thrombophilia is not necessarily the direct cause. Hypercoagulable states may play a more important role in young, healthy patients who present with chronic or recurrent colonic ischemia.

Because no large clinical trials have been done and data are scarce and limited to case reports and small retrospective studies, a hypercoagulable evaluation is reserved for younger patients and those with recurrent, unexplained ischemic colitis.

Even if we detect thrombophilia, nobody yet knows what the appropriate medical treatment should be. Although some cases of ischemic colitis with associated thrombophilia have been successfully treated with anticoagulants,^{28,29} the benefit of diagnosing

and treating a hypercoagulable state in ischemic colitis is still unproven. Therefore, oral anticoagulation should be used only in those in whom a hypercoagulable state is the most likely cause of severe or recurrent colonic ischemia.

There are no official guidelines on the duration of anticoagulation in such patients, but we treat for 6 months and consider indefinite treatment if the ischemic colitis recurs.

Medications that should always be considered as possible culprits include:

- Alosetron (Lotronex), which was temporarily withdrawn by the US Food and Drug Administration because of its association with ischemic colitis when prescribed to treat diarrhea-predominant irritable bowel syndrome.³⁰ It was later reinstated, with some restrictions.
- Digitalis
- Diuretics
- Estrogens
- Danazol (Danocrine)
- Nonsteroidal anti-inflammatory drugs
- Tegaserod (Zelnorm)
- Paclitaxel (Abraxane)
- Carboplatin (Paraplatin)
- Sumatriptan (Imitrex)
- Simvastatin (Zocor)
- Interferon-ribavirin³¹
- Pseudoephedrine (eg, Sudafed).³²

Endoscopic retrograde cholangiopancreatography can cause ischemic colitis if the rare life-threatening complication of mesenteric hematoma occurs.³³

Chronic constipation can lead to colonic ischemia by increasing intraluminal pressure, which hinders blood flow and reduces the arteriovenous oxygen gradient in the colonic wall.^{34,35}

Long-distance running can cause sustained bouts of ischemia, likely due to shunting of blood away from the splanchnic circulation, along with dehydration and electrolyte abnormalities. Affected runners present with lower abdominal pain and hematochezia. The colitis usually resolves without sequelae with rehydration and electrolyte correction.³⁶

Vasospasm has been described as a cause of ischemia. During systemic hypoperfusion, vasoactive substances shunt blood from the gut to the brain through mesenteric vasocon-

A cause is not determined in most cases

striction.³⁷ This phenomenon can occur in dehydration-induced hypotension, heart failure, septic shock, or exposure to drugs such as antihypertensive medications, digoxin, or cocaine. Necrosis of the villous layer and transmural infarctions can occur with uninterrupted ischemia lasting more than 8 hours.³⁸

Snake venom. The bite of *Agkistrodon blomhoffii brevicaudus*, a pit viper found in China and Korea, was recently reported to cause transient ischemic colitis due to disseminated intravascular coagulation. The condition resolved in about 10 days after treatment with polyvalent antivenom solution, transfusion of platelets and fresh frozen plasma, and empirically chosen antibiotics, ie, ampicillin-sulbactam (Unasyn) and metronidazole (Flagyl).³⁹

■ CLINICAL MANIFESTATIONS

As stated above, ischemic colitis should be included in the differential diagnosis when assessing patients with abdominal pain, diarrhea, or bloody stools.

Typical presentation

The typical presentation of acute colonic ischemia includes:

- Rapid onset of mild abdominal pain
- Tenderness over the affected bowel area, usually on the left side near the splenic flexure or the rectosigmoid junction
- Mild to moderate hematochezia beginning within 1 day of the onset of abdominal pain. The bleeding is often not profuse and does not cause hemodynamic instability or require transfusion.⁴⁰

Differentiate from mesenteric ischemia

It is important to differentiate between ischemic colitis and mesenteric ischemia, which is more serious and affects the small bowel.

Most patients with acute mesenteric ischemia complain of sudden onset of severe abdominal pain out of proportion to the tenderness on physical examination, they appear profoundly ill, and they do not have bloody stools until the late stages. They need urgent mesenteric angiography or another fast imaging test.⁴

In contrast, many patients with chronic mesenteric ischemia (or “abdominal angina”)

report recurrent severe postprandial abdominal pain, leading to fear of food and weight loss.

Varies in severity

The severity of ischemic colitis varies widely, with hypoperfusion affecting as little as a single segment or as much as the entire colon. Over three-fourths of cases are the milder, nongangrenous form, which is temporary and rarely causes long-term complications such as persistent segmental colitis or strictures.⁴¹ In contrast, gangrenous colonic ischemia, which accounts for about 15% of cases, can be life-threatening.

Colonic ischemia can be categorized according to its severity and clinical presentation⁴²:

- Reversible colonopathy (submucosal or intramural hemorrhage)
- Transient colitis (45% of cases were reversible or transient in a 1978 report by Boley et al⁴³)
- Chronic colitis (19% of cases)
- Stricture (13%)
- Gangrene (19%)
- Fulminant universal colitis.

The resulting ischemic injury can range from superficial mucosal damage to mural or even full-thickness transmural infarction.⁴⁴

Although most cases involve the left colon, about one-fourth involve the right. Right-sided colonic ischemia tends to be more severe: about 60% of patients require surgery (five times more than with colitis of other regions), and the death rate is twice as high (close to 23%).⁴⁵

■ DIAGNOSIS DEPENDS ON SUSPICION

The diagnosis of colonic ischemia largely depends on clinical suspicion, especially since many other conditions (eg, infectious colitis, inflammatory bowel disease, diverticulitis, colon cancer) present with abdominal pain, diarrhea, and hematochezia. One study showed that a clinical presentation of lower abdominal pain or bleeding, or both, was 100% predictive of ischemic colitis when accompanied by four or more of the following risk factors: age over 60, hemodialysis, hypertension, hypoalbuminemia, diabetes mellitus, or drug-induced constipation.⁴⁶

The role of hypercoagulable states in ischemic colitis is still unclear

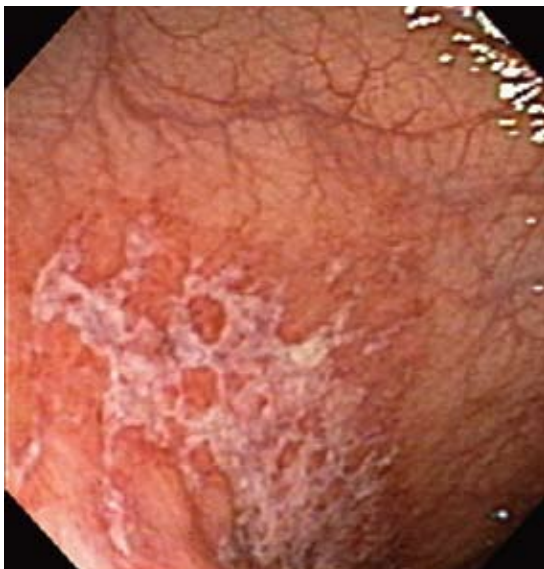

FIGURE 2. Mildly active ischemic colitis with a large superficial ulcer in the watershed area of the splenic flexure.

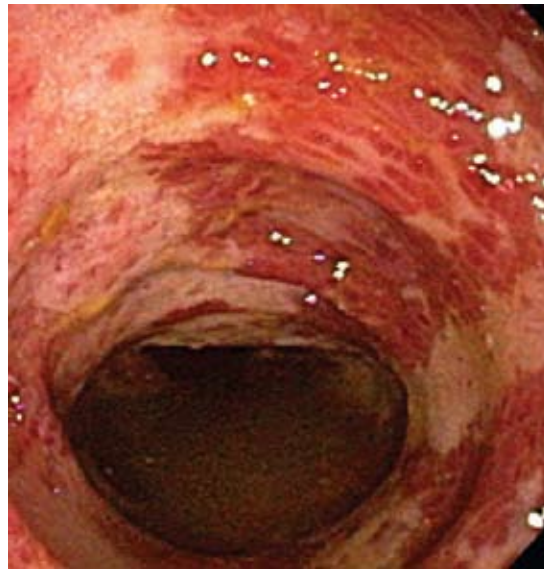

FIGURE 3. Severely active ischemic colitis with extensive ulceration and submucosal hemorrhage distributed segmentally in the distal transverse colon and descending colon.

Drugs should always be considered as possible culprits

Stool studies can identify organisms

Invasive infections with *Salmonella*, *Shigella*, and *Campylobacter* species and *Escherichia coli* O157:H7 should be identified early with stool studies if the patient presents as an outpatient or has been hospitalized less than 72 hours. Parasites such as *Entamoeba histolytica* and *Angiostrongylus costaricensis* and viruses such as cytomegalovirus should be considered in the differential diagnosis, as they can cause ischemic colitis.^{41,47} *Clostridium difficile* should be excluded in those exposed to antibiotics.

Blood tests may indicate tissue injury

Although no laboratory marker is specific for ischemic colitis, elevated serum levels of lactate, lactate dehydrogenase, creatine kinase, or amylase may indicate tissue injury. The combination of abdominal pain, a white blood cell count greater than $20 \times 10^9/L$, and metabolic acidosis suggests intestinal ischemia and infarction.

Endoscopy is the test of choice

Endoscopy has become the diagnostic test of choice in establishing the diagnosis of ischemic colitis, although computed tomography (CT) can provide suggestive findings and exclude other illnesses. Colonoscopy has almost completely replaced radiography with barium-enema contrast as a diagnostic tool because it

is more sensitive for detecting mucosal changes, it directly visualizes the mucosa, and it can be used to obtain biopsy specimens.⁴⁸

Colonoscopy is performed without bowel preparation to prevent hypoperfusion caused by dehydrating cathartics. In addition, the scope should not be advanced beyond the affected area, and minimal air insufflation should be used to prevent perforation.

Endoscopic findings can help differentiate ischemic colitis from other, clinically similar diseases. For instance, unlike irritable bowel disease, ischemic colitis tends to affect a discrete segment with a clear delineation between affected and normal mucosa, it spares the rectum, the mucosa heals rapidly as seen on serial colonoscopic examinations, and a single linear ulcer, termed the “single-stripe” sign, runs along the longitudinal axis of the colon.^{49,50}

In early and mild disease (FIGURE 2), the mucosa is pale and edematous with petechiae, and the single-stripe sign is present.

As ischemia progresses, hemorrhagic nodules appear (visible as “thumbprinting” on barium enema radiographs), usually in the company of erythematous mucosa with dispersed ulcerations and submucosal hemorrhage (FIGURE 3). Severe ischemia causing gangrene usually manifests as cyanotic mucosal nodules and hemorrhagic ulcerations.⁵¹⁻⁵³

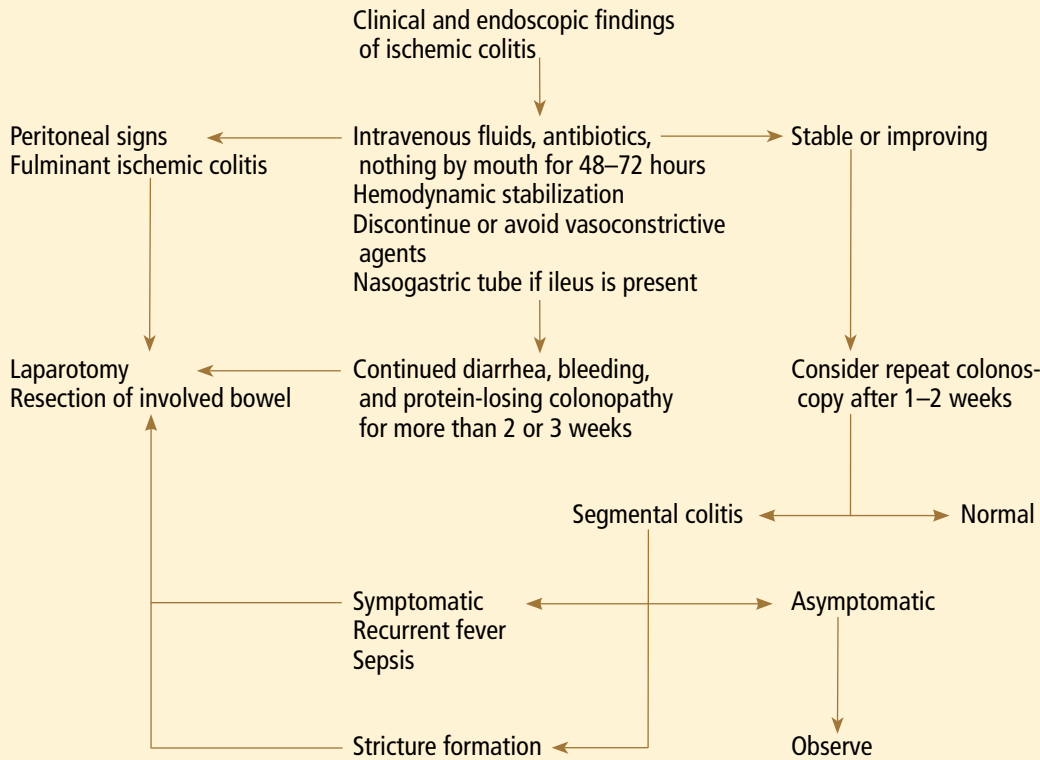


FIGURE 4. Management of colonic ischemia.

BASED ON BRANDT LS, BOLEY SJ. AGA TECHNICAL REVIEW ON INTESTINAL ISCHEMIA. AMERICAN GASTROENTEROLOGICAL ASSOCIATION. GASTROENTEROLOGY 2000; 118:954-968.

Endoscopy has become the diagnostic procedure of choice for ischemic colitis

Biopsy features are not specific, as findings of hemorrhage, capillary thrombosis, granulation tissue with crypt abscesses, and pseudopolyps can also be seen in other conditions, such as Crohn disease.^{54,55}

Imaging studies are not specific

Imaging studies are often used, but the findings lack specificity.

Plain abdominal radiography can help only in advanced ischemia, in which distention or pneumatosis can be seen.

CT with contrast can reveal thickening of the colon wall in a segmental pattern in ischemic colitis, but this finding also can be present in infectious and Crohn colitis. CT findings of colonic ischemia also include pericolic streakiness and free fluid. Pneumatosis coli often signifies infarcted bowel.⁵⁶ However, CT findings can be completely normal in mild cases or if done early in the course.

Angiography in severe cases

Since colonic ischemia is most often transient, mesenteric angiography is not indicated in mild cases. Angiography is only considered in more severe cases, especially when only the right colon is involved, the diagnosis of colonic ischemia has not yet been determined, and acute mesenteric ischemia needs to be excluded. A focal lesion is often seen in mesenteric ischemia, but not often in colonic ischemia.

Looking for the underlying cause

Once the diagnosis of ischemic colitis is made, an effort should be made to identify the cause (TABLE 1). The initial step can be to remove or treat reversible causes such as medications or infections. As mentioned earlier, electrocardiography, Holter monitoring, and transthoracic echocardiography should be considered in patients with ischemic colitis to rule out cardiac embolic sources.⁹ A hypercoagulable

workup can be done, but only in young patients without other clear causes or patients with recurrent events.

■ CONSERVATIVE TREATMENT IS ENOUGH FOR MOST

Conservative therapy with intravenous fluids, hemodynamic stabilization, discontinuation or avoidance of vasoconstrictive agents, bowel rest, and empiric antibiotics is effective in most cases (FIGURE 4).

Empirically chosen broad-spectrum antibiotics that cover both aerobic and anaerobic coliform bacteria are reserved for patients with moderate to severe colitis to minimize bacterial translocation and sepsis.

Whenever symptomatic ileus is present, a nasogastric tube should be placed to alleviate vomiting and abdominal discomfort.

Antiplatelet agents have not been evaluated in treating ischemic colitis and are generally not used. As mentioned earlier, anticoagulation has been used in patients who have been proven to have hypercoagulable conditions,^{28,29} but its benefit is not yet proven. Currently, if the coagulation profile is abnormal, anticoagulation should be used only in cases of recurrent colonic ischemia or in young patients with severe cases in the absence of a clear cause. Anticoagulation should also be used in confirmed cases of cardiac embolization.

Surgery for some

Exploratory laparotomy with possible subtotal or segmental colectomy may be needed in acute, subacute, or chronic settings.⁴² Acute indications include peritoneal signs, massive bleeding, and fulminant ischemic colitis. Sub-

acute indications are lack of resolution, with symptoms that persist for more than 2 or 3 weeks, or malnutrition or hypoalbuminemia due to protein-losing colonopathy. Colon stricture can be chronic and becomes an indication for surgery only when symptomatic, as some strictures resolve with time (months to years).

Right hemicolectomy and primary anastomosis of viable remaining colon is performed for right-sided colonic ischemia and necrosis, while left-sided colonic ischemia is managed with a proximal stoma and distal mucous fistula, or Hartmann procedure. Re-anastomosis and ostomy closure are usually done after 4 to 6 months.⁵⁷ However, resection and primary anastomosis can also be an option for patients with isolated ischemia of the sigmoid colon.⁵⁸ Transendoscopic dilation or stenting of short strictures can be an alternative to surgery, although experience with this is limited.^{59,60}

■ THE PROGNOSIS IS USUALLY GOOD

The prognosis depends on the extent of injury and comorbidities. Transient, self-limited ischemia involving the mucosa and submucosa has a good prognosis, while fulminant ischemia with transmural infarction carries a poor one, as it can progress to necrosis and death.

Although up to 85% of cases of ischemic colitis managed conservatively improve within 1 or 2 days and resolve completely within 1 or 2 weeks, close to one-fifth of patients develop peritonitis or deteriorate clinically and require surgery.^{61,62} Surgical resection is required when irreversible ischemic injury and chronic colitis develop, as both can lead to bacteremia and sepsis, colonic stricture, persistent abdominal pain and bloody diarrhea, and protein-losing enteropathy.⁴⁰ ■

With conservative therapy, up to 85% of patients improve within a few days

■ REFERENCES

- Higgins PD, Davis KJ, Laine L. Systematic review: the epidemiology of ischaemic colitis. *Aliment Pharmacol Ther* 2004; 19:729–738.
- Feldman M, Friedman LS, Sleisenger MH, eds. Sleisenger and Fordtran's Gastrointestinal and Liver Disease: Pathophysiology, Diagnosis, Management. 7th ed. Philadelphia, PA: Saunders; 2002.
- Gandhi SK, Hanson MM, Vernava AM, Kaminski DL, Longo WE. Ischemic colitis. *Dis Colon Rectum* 1996; 39:88–100.
- Greenwald DA, Brandt LJ, Reinus JF. Ischemic bowel disease in the elderly. *Gastroenterol Clin North Am* 2001; 30:445–473.
- Reeders JW, Tytgat GN, Rosenbusch G, et al. Ischaemic colitis. The Hague: Martinus Nijhoff, 1984;17.
- Brandt L, Boley S, Goldberg L, Mitsudo S, Berman A. Colitis in the elderly. A reappraisal. *Am J Gastroenterol* 1981; 76:239–245.
- Binns JC, Isaacson P. Age-related changes in the colonic blood supply: their relevance to ischaemic colitis. *Gut* 1978; 19:384–390.
- Zimmerman BJ, Granger DN. Reperfusion injury. *Surg Clin North Am* 1992; 72:65–83.
- Hourmand-Ollivier I, Bouin M, Saloux E, et al. Cardiac sources of embolism should be routinely screened in ischemic colitis. *Am J Gastroenterol* 2003; 98:1573–1577.
- Cappell MS. Safety and efficacy of colonoscopy after myocardial infarction: an analysis of 100 study patients and 100 control patients at two tertiary cardiac referral hospitals. *Gastrointest Endosc* 2004; 60:901–909.
- Cappell MS, Mahajan D, Kurupath V. Characterization of ischemic colitis associated with myocardial infarction: an analysis of 23 patients. *Am J Med* 2006; 119:527.e1–e9.

12. **Hagihara PF, Ernst CB, Griffen WO.** Incidence of ischemic colitis following abdominal aortic reconstruction. *Surg Gynecol Obstet* 1979; 149:571–573.
13. **Brewster DC, Franklin DP, Cambria RP, et al.** Intestinal ischemia complicating abdominal aortic surgery. *Surgery* 1991; 109:447–454.
14. **Piotrowski JJ, Ripepi AJ, Yuhaz JP, Alexander JJ, Brandt CP.** Colonic ischemia: the Achilles heel of ruptured aortic aneurysm repair. *Am Surg* 1996; 62:557–560.
15. **Ernst CB.** Colonic ischemia following aortic reconstruction. In: Rutherford RB, editor. *Vascular Surgery*. 4th ed. Philadelphia, PA: WB Saunders; 1995:1312–1320.
16. **Geroghty PS, Sanchez LA, Rubin BG, et al.** Overt ischemic colitis after endovascular repair of aortoiliac aneurysm. *J Vasc Surg* 2004; 40:413–418.
17. **Klestzick HN, McPhedran P, Cipolla D, Berry WA, DiCorato M, Denowitz J.** The antiphospholipid syndrome and ischemic colitis. *Gastroenterologist* 1995; 3:249–256.
18. **Knot EA, ten Cate JW, Bruin T, Iburg AH, Tytgat GN.** Antithrombin III metabolism in two colitis patients with acquired antithrombin III deficiency. *Gastroenterology* 1985; 89:421–425.
19. **Maloisel F.** Role of coagulation disorders in mesenteric ischemia. *J Chir (Paris)* 1996; 133:442–447.
20. **Koutroubakis IE, Sfiridakis A, Theodoropoulou A, Kouroumalis EA.** Role of acquired and hereditary thrombotic risk factors in colon ischemia of ambulatory patients. *Gastroenterology* 2001; 121:561–565.
21. **Midian-Singh R, Polen A, Durishin C, Crock RD, Whittier FC, Fahmy N.** Ischemic colitis revisited: a prospective study identifying hypercoagulability as a risk factor. *South Med J* 2004; 97:120–123.
22. **Blanc P, Bories P, Donadio D, et al.** Ischemic colitis and recurrent venous thrombosis caused by familial protein S deficiency. *Gastroenterol Clin Biol* 1989; 13:945.
23. **Verger P, Blanc C, Feydy P, Boey S.** Ischemic colitis caused by protein S deficiency. *Presse Med* 1996; 25:1350.
24. **Ludwig D, Stahl M, David-Walek T, et al.** Ischemic colitis, pulmonary embolism, and atrial thrombosis in a patient with inherited resistance to activated protein C. *Dig Dis Sci* 1998; 43:1362–1367.
25. **Yee NS, Guerry D 4th, Lichtenstein GR.** Ischemic colitis associated with factor V Leiden mutation. *Ann Intern Med* 2000; 132:595–596.
26. **Balian A, Veyradier A, Naveau S, et al.** Prothrombin 20210G/A mutation in two patients with mesenteric ischemia. *Dig Dis Sci* 1999; 44:1910–1913.
27. **Arnott ID, Ghosh S, Ferguson A.** The spectrum of ischaemic colitis. *Eur J Gastroenterol Hepatol* 1999; 11:295–303.
28. **Chin BW, Greenberg D, Wilson RB, Meredith CG.** A case of ischemic colitis associated with factor V Leiden mutation: successful treatment with anticoagulation. *Gastrointest Endosc* 2007; 66:416–418.
29. **Heyn J, Buhmann S, Ladurner R, et al.** Recurrent ischemic colitis in a patient with Leiden factor V mutation and systemic lupus erythematosus with antiphospholipid syndrome. *Eur J Med Res* 2008; 13:182–184.
30. **Chang L, Chey WD, Harris L, Olden K, Surawicz C, Schoenfeld P.** Incidence of ischemic colitis and serious complications of constipation among patients using alosetron: systematic review of clinical trials and post-marketing surveillance data. *Am J Gastroenterol* 2006; 101:1069–1079.
31. **Punnam SR, Pothula VR, Gourineni N, Punnam A, Ranganathan V.** Interferon-ribavirin-associated ischemic colitis. *J Clin Gastroenterol* 2008; 42:323–325.
32. **Dowd J, Bailey D, Moussa K, Nair S, Doyle R, Culpepper-Morgan JA.** Ischemic colitis associated with pseudoephedrine: four cases. *Am J Gastroenterol* 1999; 94:2430–2434.
33. **Kingsley DD, Schermer CR, Jamal MM.** Rare complications of endoscopic retrograde cholangiopancreatography: two case reports. *JSL* 2001; 5:171–173.
34. **Boley SJ, Agrawal GP, Warren AR, et al.** Pathophysiologic effects of bowel distension on intestinal blood flow. *Am J Surg* 1969; 117:228–234.
35. **Reinus JF, Brandt LJ, Boley SJ.** Ischemic diseases of the bowel. *Gastroenterol Clin North Am* 1990; 19:319–343.
36. **Moses, FM.** Exercise-associated intestinal ischemia. *Curr Sports Med Rep* 2005; 4:91–95.
37. **Rosenblum JD, Boyle CM, Schwartz LB.** The mesenteric circulation. Anatomy and physiology. *Surg Clin North Am* 1997; 77:289–306.
38. **Haglund U, Bulkley GB, Granger DN.** On the pathophysiology of intestinal ischemic injury. Clinical review. *Acta Chir Scand* 1987; 153:321–324.
39. **Kim MK, Cho YS, Kim HK, Kim JS, Kim SS, Chae HS.** Transient ischemic colitis after a pit viper bite (*Agkistrodon blomhoffii brevicaudus*). *J Clin Gastroenterol* 2008; 42:111–112.
40. **Cappell MS.** Intestinal (mesenteric) vasculopathy. II. Ischemic colitis and chronic mesenteric ischemia. *Gastroenterol Clin North Am* 1998; 27:827–860.
41. **Greenwald DA, Brandt LJ.** Colonic ischemia. *J Clin Gastroenterol* 1998; 27:122–128.
42. **Brandt LJ, Boley SJ.** AGA technical review on intestinal ischemia. American Gastrointestinal Association. *Gastroenterology* 2000; 118:954–968.
43. **Boley SJ, Brandt LJ, Veith FJ.** Ischemic disorders of the intestines. *Curr Probl Surg* 1978; 15:1–85.
44. **Schuler JG, Hudlin MM.** Cecal necrosis: infrequent variant of ischemic colitis. Report of five cases. *Dis Colon Rectum* 2000; 43:708–712.
45. **Sotiriadis J, Brandt LJ, Behin DS, Southern WN.** Ischemic colitis has a worse prognosis when isolated to the right side of the colon. *Am J Gastroenterol* 2007; 102:2247–2252.
46. **Park CJ, Jang MK, Shin WG, et al.** Can we predict the development of ischemic colitis among patients with lower abdominal pain? *Dis Colon Rectum* 2007; 50:232–238.
47. **Su C, Brandt LJ, Sigal SH, et al.** The immunohistological diagnosis of *E. coli* O157:H7 colitis: possible association with colonic ischemia. *Am J Gastroenterol* 1998; 93:1055–1059.
48. **Scowcroft CW, Sanowski RA, Kozarek RA.** Colonoscopy in ischemic colitis. *Gastrointest Endosc* 1981; 27:156–161.
49. **Rogers AI, David S.** Intestinal blood flow and diseases of vascular impairment. In: Haubrich WS, Schaffner F, Berk JE, editors. *Gastroenterology*. 5th ed. Philadelphia: WB Saunders; 1995:1212–1234.
50. **Zuckerman GR, Prakash C, Merriman RB, Sawhney MS, DeSchryver-Keckemeti K, Clouse RE.** The colon single-stripe sign and its relationship to ischemic colitis. *Am J Gastroenterol* 2003; 98:2018–2022.
51. **Green BT, Tendler DA.** Ischemic colitis: a clinical review. *South Med J* 2005; 98:217–222.
52. **Baixaui J, Kiran RP, Delaney CP.** Investigation and management of ischemic colitis. *Cleve Clin J Med* 2003; 70:920–930.
53. **Habu Y, Tahashi Y, Kiyota K, et al.** Reevaluation of clinical features of ischemic colitis: analysis of 68 consecutive cases diagnosed by early colonoscopy. *Scand J Gastroenterol* 1996; 31:881–886.
54. **Mitsudo S, Brandt LJ.** Pathology of intestinal ischemia. *Surg Clin North Am* 1992; 72:43–63.
55. **Price AB.** Ischaemic colitis. *Curr Top Pathol* 1990; 81:229–246.
56. **Balthazar EJ, Yen BC, Gordon RB.** Ischemic colitis: CT evaluation of 54 cases. *Radiology* 1999; 211:381–388.
57. **Mosdell DM, Doberneck RC.** Morbidity and mortality of ostomy closure. *Am J Surg* 1991; 162:633–636.
58. **Iqbal T, Zarin M, Iqbal A, et al.** Results of primary closure in the management of gangrenous and viable sigmoid volvulus. *Pak J Surg* 2007; 23:118–121.
59. **Oz MC, Forde KA.** Endoscopic alternatives in the management of colonic strictures. *Surgery* 1990; 108:513–519.
60. **Profilis S, Bifulco V, Meloni GB, Demelas L, Niolu P, Manzoni MA.** A case of ischemic stenosis of the colon-sigmoid treated with self-expandable uncoated metallic prosthesis. *Radiol Med* 1996; 91:665–667.
61. **Brandt LJ, Boley SJ.** Colonic ischemia. *Surg Clin North Am* 1992; 72:203–229.
62. **Boley SJ.** 1989 David H. Sun lecture. Colonic ischemia—25 years later. *Am J Gastroenterol* 1990; 85:931–934.

ADDRESS: *Firas Al Solaiman, MD, Department of Vascular Medicine, J3-5, Cleveland Clinic, 9500 Euclid Avenue, Cleveland, OH 44195; e-mail alsolaf@ccf.org.*