

ELIF KUPELI, MD

Department of Pulmonary Diseases,
Baskent University School of Medicine,
Ankara, Turkey

GAYE ULUBAY

Department of Pulmonary Diseases,
Baskent University School of Medicine,
Ankara, Turkey

The Clinical Picture

Bony bridge of a bifid rib

This finding merits a thorough physical examination to rule out a genetic syndrome

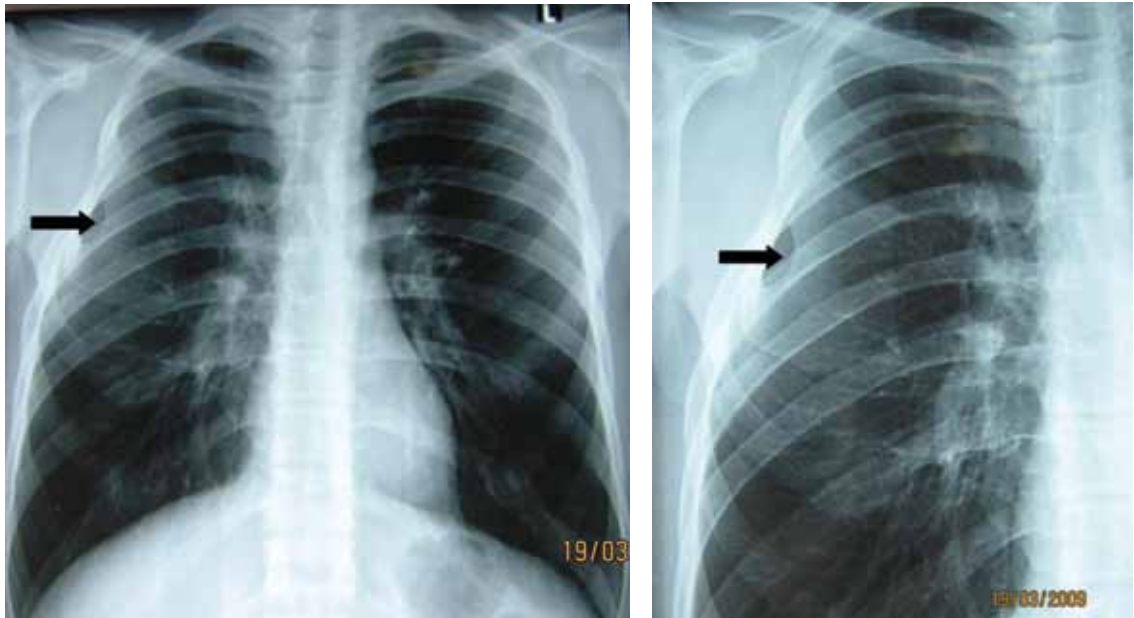


FIGURE 1. The anteroposterior chest x-ray (left) shows a 1-cm-wide bony bridge (arrow) between the third and the fourth ribs, anteriorly and on the right. The anomaly is also visible in a close-up view (right) of the right rib cage (arrow).

A 21-YEAR-OLD MAN has had cough and hemoptysis for 3 days. For the past 3 years he has smoked one pack of cigarettes a day. His medical history is unremarkable, and he has had no chest trauma or thoracic surgery.

The physical examination is normal. Chest radiography reveals a 1-cm-wide bony bridge between the third and the fourth ribs, anteriorly and on the right (**FIGURE 1**), but no signs of trauma, rib fracture, or callus formation. Computed tomography to evaluate the hemoptysis shows no evidence of trauma or fracture.

The patient says he was born full-term, and he has never been aware of any congenital anomalies.

doi:10.3949/ccjm.76a.09066

Q: Which is the most likely diagnosis?

- ☐ Fractured rib
- ☐ Poland syndrome
- ☐ Paget disease
- ☐ Bifid rib

A: Bifid rib, a congenital anomaly, is the correct answer (see below).

Fractured rib. The patient has no history of chest trauma or thoracic surgery, nor any evidence on chest x-ray to suggest a fractured rib. Also, he has no evidence of osteoporosis to suspect a spontaneous rib fracture. His hemoptysis is most likely due to acute bronchitis.

Poland syndrome is a unilateral deficiency of the pectoralis muscle, variably associ-

ated with ipsilateral thoracic and upper limb anomalies. Bilateral hypoplasia or aplasia of the pectoralis muscle and upper-limb defects in association with variable thoracic muscles, chest wall deformities, and lower-limb defects has been infrequently reported in the literature. The diagnosis is usually based on the physical examination (asymmetric chest) or on chest x-ray (unilateral hyperlucent lung).¹ This is not the case in our patient.

Paget disease is a chronic, abnormal bone-remodeling process that leads to enlarged, less-dense, brittle bones. The spine, femur, pelvis, skull, clavicle, and humerus are most commonly affected. In the United States, the prevalence is 3% to 4% in people over age 40. Black Americans have a higher prevalence rate than black Africans, and the disease is rare in Asians.

Pain is the most common symptom, but Paget disease is usually asymptomatic. Paget disease can lead to insufficiency fractures, pathologic fractures, secondary arthritis, and nerve impingement in the spine or the base of the skull. Sarcomatous degeneration of the affected bone has been reported, but is rare.

Radiographic findings are often diagnostic. The skull and long bones typically show evidence of osteolysis from the epiphysis and advancing along the diaphysis. Radiographic findings in the sclerotic phase typically involve the axial skeleton and include trabecular coarsening and distortion and cortical thickening.

Rib abnormalities may be observed; these may either be isolated or may be a sign of multisystem malformations. However, in our patient, the radiographic finding of a bony bridge does not fit the description of Paget disease.²

■ BIFID RIB

The overall prevalence of bifid rib is estimated at 0.15% to 3.4% (mean 2%), and it accounts for up to 20% of all congenital rib anomalies.³ It is usually unilateral. Wattanasirichaigoon et al⁴ described patterns of rib defects in 47 cases, with bifid rib accounting for 28% of cases.

As with Paget disease, rib anomalies may occur in isolation or in association with multisystem malformations. Since the ribs originate from the mesoderm, it is not surprising that the costal defects are associated with malformations in other organs of the same origin, such as the heart and the kidneys.³ Bifid ribs are also seen in several genetic disorders such as Gorlin-Goltz (ie, basal cell nevus) syndrome, which affects multiple organs including bones, skin, eye, and neural system.⁵ Occasionally, it is encountered as a part of Jobs syndrome (ie, high levels of immunoglobulin E and recurrent infections),⁶ and Kindler syndrome, a rare genodermatosis.⁷

The literature contains little information about the clinical significance of bifid rib. Patients should undergo a thorough physical examination, including oral and cutaneous evaluation, to rule out a genetic syndrome. Physical findings such as palmar pits, subcutaneous calcifications, or odontogenic cyst warrant a more intensive radiologic and genetic investigation.⁵ If the physical examination is normal and if the patient is asymptomatic, additional clinical or radiologic investigation is of low yield. And as in our patient, the anomaly may go unnoticed on computed tomography of the chest. ■

■ REFERENCES

1. Allam SR, Yadav R, Meziane M, Mehta AC. A middle-aged man with asymptomatic chest wall asymmetry. *Cleve Clin J Med* 2006; 73:754–756.
2. Hung HC, Ou HY, Huang JS, Chuang MC, Wu TJ. Tumor-associated hypercalcemia in a patient with Paget's disease. *Kaohsiung J Med Sci* 2008; 24:152–156.
3. Charles I, Scott J. Pectoral girdle, spine, ribs, and pelvic girdle. In: Stevenson RE, Hall JG, Goodmann RM, eds. *Human Malformations and Related Anomalies*, vol 2. Oxford University Press: New York, 1993:655–697.
4. Wattanasirichaigoon D, Prasad C, Schneider G, Evans JA, Korf BR. Rib defects in patterns of multiple malformations: a retrospective review and phenotypic analysis of 47 cases. *Am J Med Genet A* 2003; 122A:63–69.
5. Rai S, Gauba K. Jaw cyst-basal cell nevus-bifid rib syndrome: a case report. *J Indian Soc Pedod Prev Dent* 2007; 25:137–139.
6. Freeman AF, Holland SM. The hyper-IgE syndromes. *Immunol Allergy Clin North Am* 2008; 28:277–291.
7. Sharma RC, Mahajan V, Sharma NL, Sharma AK. Kindler syndrome. *Int J Dermatol* 2003; 42:727–732.

ADDRESS: Elif Kupeli, MD, Baskent University School of Medicine, Department of Pulmonary Diseases, Fevzi Cakmak Cad, 5 Sokak, No 48, 06490, Beşevler, Ankara, Turkey; e-mail elifkupeli@yahoo.com.