

# Imaging for autonomic dysfunction

## ■ ABSTRACT

Direct visualization of heart-brain interactions is the goal when assessing autonomic nervous system function. Cortical topology relevant to neuroimaging consists of the cingulate, insula, and amygdala, all of which share proximity to the basal ganglia. Significant cardiac effects stemming from brain injury are well known, including alteration of cardiac rhythms, cardiac variability, and blood pressure regulation; in some instances, these effects may correlate with neuroimaging, depending on the region of the brain involved. It is difficult to achieve visualization of areas within the brainstem that govern autonomic responses, although investigators have identified brain correlates of autonomic function with the use of functional magnetic resonance imaging and electrocardiographic data obtained simultaneously. The potential utility of brain imaging in sick patients may be limited because of challenges such as the magnetic resonance imaging environment and blunted autonomic responses, but continued investigation is warranted.

**T**he autonomic nervous system (ANS), composed of the sympathetic and parasympathetic nervous systems, governs our adaptation to changing environments such as physical threats or changes in temperature. It has been difficult to elucidate this process in humans, however, because of limitations in neuroimaging caused by artifacts from cardiorespiratory sources. This article reviews structural and functional imaging that can provide insights into the ANS.

## ■ STRUCTURAL IMAGING

For purposes of imaging, it is helpful to visualize the neural anatomy at a primitive level. If we imagine the neural tube bisected and flayed open, and the folds smoothed out, we would see a simplified topology of the

brain, revealing the forebrain (cerebral cortex, thalamus, and hypothalamus), midbrain, hindbrain (pons, medulla, cerebellum), and spinal cord. As the brain develops and appears more complicated, these simple underlying relationships are preserved. Of particular note are the relationships of the cingulate, insula, and amygdala, all of which share proximity to the basal ganglia and the gateways into and out of the brain. These regions control and influence the ANS, many of which are visible on a single coronal view, including the cingulate cortex, prefrontal cortex, insular cortex, amygdala, and hypothalamus (**Figure 1**). However, the smaller individual hypothalamic and brainstem nuclei are typically not visible on conventional magnetic resonance imaging (MRI).

Similar to cortical and subcortical pathology (or stimulation) in areas of the brain that manifest as non-autonomic symptoms such as weakness, paresthesias, or seizures, pathology or stimulation in ANS areas of the brain manifest as autonomic symptoms. For example (**Table**), electrical stimulation of the right insular cortex of animals and humans causes ANS manifestations in the form of changes in heart rate and blood pressure, whereas left-sided stimulation of the insular cortex causes a decrease in heart rate and depressor responses. Stimulation of the basolateral amygdalian nucleus increases blood pressure and decreases heart rate; stimulation of the rostral amygdalian nucleus results in depressor effects and variable changes in heart rate. Stimulation of the cingulated gyrus and some other regions within the prefrontal cortex causes decreases in heart rate and blood pressure.

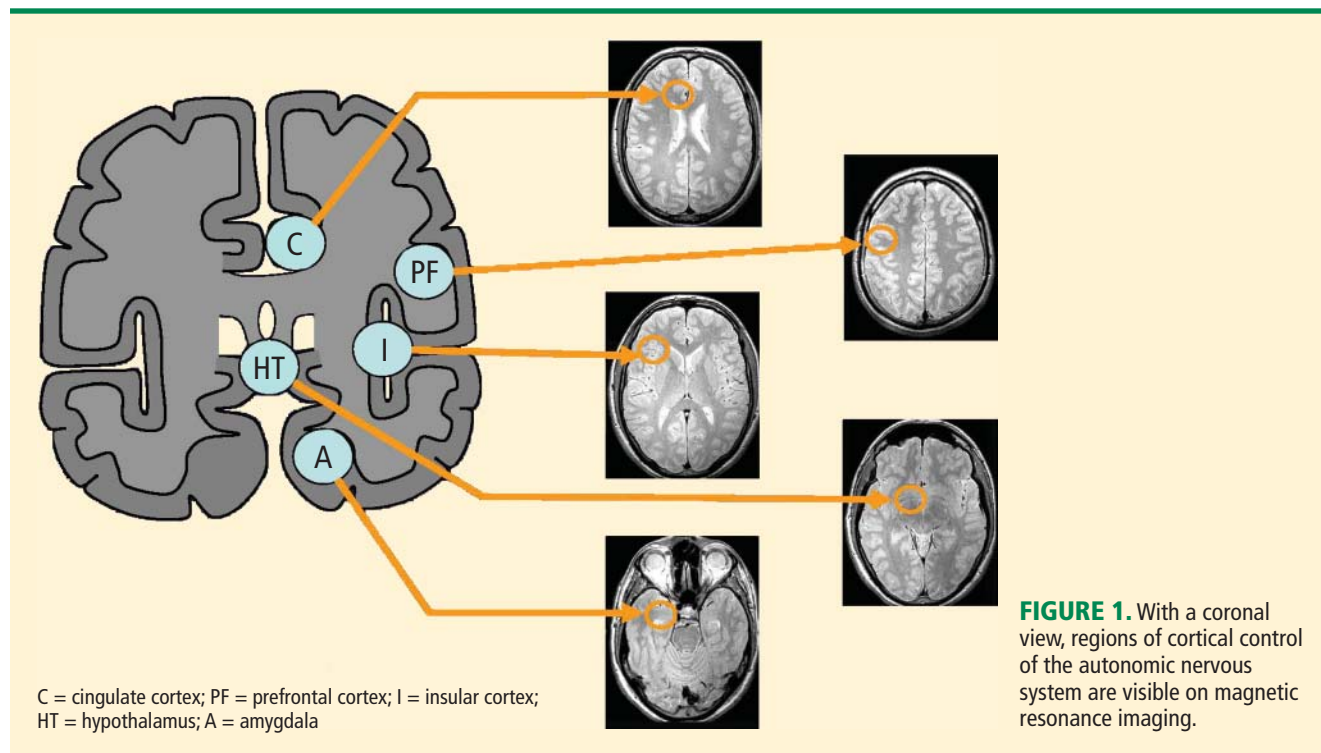
The two main subcortical areas of interest for imaging are the lateral hypothalamic area and the paraventricular nucleus, but visualization is difficult. The hypothalamus occupies a volumetric area of the brain no larger than 20 voxels; individual substructures of the hypothalamus therefore cannot easily be viewed by conventional imaging. The larger voxel size of functional MRI (fMRI) mean that fMRI of the hypothalamus can display 1 voxel at most.

Most brainstem nuclei are motor nuclei that affect autonomic responses, either sympathetic or parasympathetic. These nuclei are difficult to visual-

Dr. Jones reported that he has no financial relationships that pose a potential conflict of interest with this article.

This article was developed from an audio transcript of Dr. Jones' lecture at the 2010 Heart-Brain Summit. The transcript was formatted and edited by the Cleveland Clinic Journal of Medicine staff for clarity and conciseness, and was then reviewed, revised, and approved by Dr. Jones.

doi:10.3949/ccjm.78.s1.12



ize on conventional MRI for two reasons: the nuclei are small, and may be the size of only 1 to 2 voxels. More important, MRI contrast between these nuclei and surrounding parenchyma is minimal because these structures “blend in” with the surrounding brain and are difficult to visualize singly. Examples of these major brainstem *sympathetic* nuclei are the periaqueductal gray substance, parabrachial nuclei, solitary nucleus, and the hypothalamospinal tract; examples of the major brainstem *parasympathetic* nuclei are the dorsal nucleus of the vagus nerve and the nucleus ambiguus.

The areas of the ANS under cortical control are more integrative, with influence from higher cognitive function—for example, the panic or fear associated with public speaking. Regions of subcortical control involve the basal ganglia and hypothalamus, which regulate primitive, subconscious activity, such as “fight or flight” response, pain reaction, and fear of snakes, all of which affect multiple motor nuclei. Several specific sympathetic and parasympathetic motor nuclei directly affect heart rate and blood pressure and act as relay stations for sensory impulses that reach the cerebral cortex.

#### ■ NEUROLOGIC PROCESSES AND CARDIAC EFFECTS

Significant cardiac effects stemming from brain injury are well known, including alteration of cardiac rhythms, cardiac variability, and blood pressure

regulation. Neurologic diseases such as parkinsonism, multiple sclerosis (MS), stroke, epilepsy, and tumors can have cardiac effects, although structural abnormalities on conventional MRI may be lacking. One notable exception is multiple systems atrophy, which can have strong autonomic symptoms and has a characteristic MRI finding called “hot cross buns” (Figure 2). An example is a subtype formally known as Shy-Drager syndrome.

MS is classically a disease of white matter, although it can also affect gray matter. Autonomic dysfunction is common, affecting as many as 50% of MS patients with symptoms that include orthostatic dizziness, bladder disturbances, temperature instability, gastrointestinal disturbances, and sweating.<sup>1-4</sup> The effect of autonomic dysfunction on disease activity is unclear. Multiple brainstem lesions are evident on MRI, and may be linked to cardiac autonomic dysfunction. The variability of MS contributes to the difficulty of using imaging to identify culprit lesions.

Stroke causes autonomic dysfunction, with the specific manifestations dependent on the region of the brain involved. In cases of right middle cerebral artery infarct affecting the right insula, an increased incidence of cardiac arrhythmias, cardiac death, and catecholamine production ensues.<sup>5-7</sup> Medullary infarcts have been shown to produce significant auto-

autonomic dysfunction.<sup>8,9</sup>

Ictal and interictal cardiac manifestations in epilepsy often precede seizure onset.<sup>1</sup> Common cardiac changes are ictal tachycardia or ictal bradycardia, or both, with no clear relationship to the location or type of seizure. Evidence suggests that heart rate variability changes in epilepsy result from interictal autonomic alterations, including sympathetic or parasympathetic dominance. Investigation of baroreflex responses with temporal lobe epilepsy has uncovered decreased baroreflex sensitivity. There is no reliable correlation between sympathetic or parasympathetic upregulation or downregulation and brain MRI findings, however.

Autonomic dysfunction in the form of orthostatic hypotension has been documented in patients with mass effect from tumors, for example posterior fossa epidermoid tumors, wherein tumor resection results in improved autonomic function.<sup>10</sup>

## FUNCTIONAL BRAIN IMAGING IN GENERAL

Direct visualization of heart-brain interactions is the goal when assessing ANS function. Positron emission tomography (PET) produces quantitative images, but spatial and temporal resolutions are vastly superior with fMRI.<sup>11</sup> Further, radiation exposure is low with fMRI, allowing for safe repeat imaging.

Ogawa et al<sup>12</sup> first demonstrated that in vivo images of brain microvasculature are affected by blood oxygen level, and that blood oxygenation reduced vascular signal loss. Therefore, blood oxygenation level-dependent (BOLD) contrast added to MRI could complement PET-like measurements in the study of regional brain activity.

The relationship between neural activity and cerebral blood flow is indirect. Functional MRI has been used to locate the brain regions that are involved in simple tasks; for example, bilateral finger tapping results in increased cerebral blood flow that is detected by fMRI after a delay of several seconds. The increase in cerebral blood flow causes decreased intravascular deoxyhemoglobin which causes decreased extravascular susceptibility signal loss, which all together result in a net enhancement of the MRI signal. The signal-to-noise ratio is very low, with a signal change on the order of 1% to 3%.

Bilateral finger tapping with intermittent periods of rest is associated with a pattern of increasing and decreasing intensity of fMRI signals in involved brain regions that reflect the periods of activity and rest. This technique has been used to locate brain voxels with similar patterns of activity, enabling the creation of familiar

**TABLE**

**Autonomic nervous system responses to cortical pathology<sup>1</sup>**

Cortical region	Effect of electrical stimulation	
	Heart rate	Blood pressure
Cingulate	—	—
Prefrontal	—	—
Insula		
Right	+	+
Left	—	—
Amygdala	±	±
Hypothalamus		
Lateral	—	—
Ventromedial	+	+

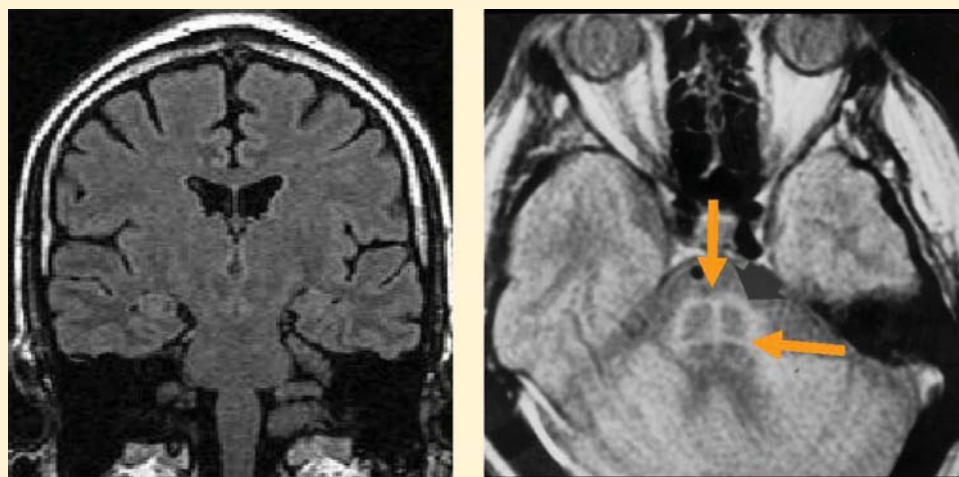
— = decrease; + = increase

color brain mapping. A challenge posed by autonomic fMRI in such brain mapping is that fMRI is susceptible to artifacts (**Figure 3**). For example, a movement of the head as little as 1 mm inside the MRI scanner—a distance comparable to the size of autonomic structures—can produce a motion artifact (false activation of brain regions) that can affect statistical significance. In addition, many ANS regions of the brain are near osseous structures (for example the brainstem and skull base) that cause signal distortion and loss.

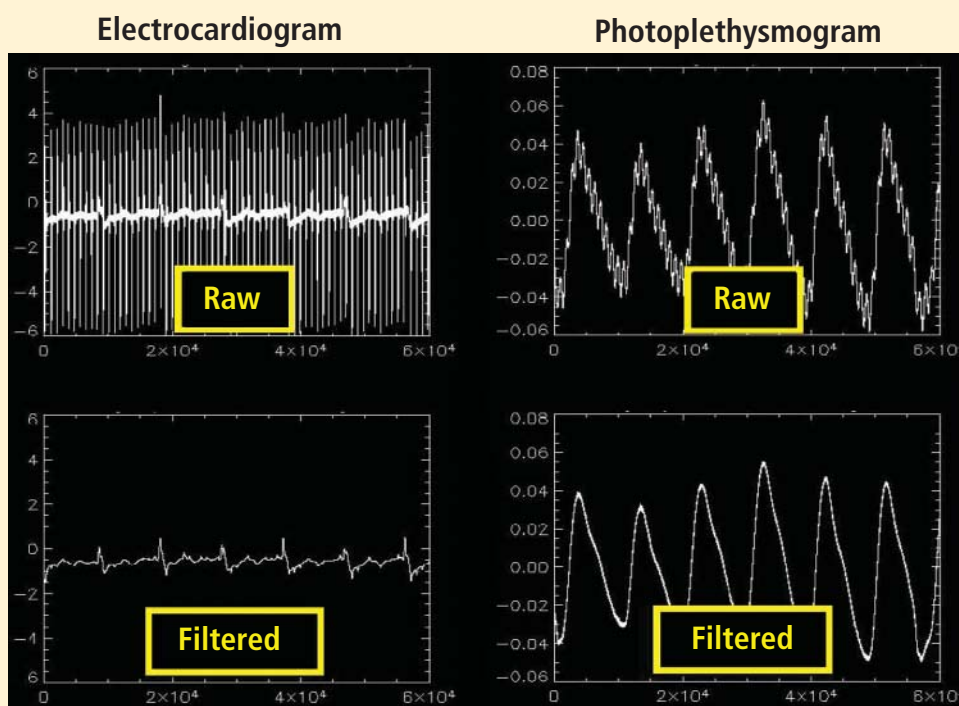
## REQUIREMENTS FOR AUTONOMIC fMRI

The tasks chosen to visualize brain control of autonomic function must naturally elicit an autonomic response. The difficulty is that untrained persons have little or no volitional control over autonomic functions, so the task and its analysis must be designed carefully and be MRI-compatible. Any motion will degrade the image; further, the capacity for the MRI environment to corrupt the measurements can limit the potential tasks for measurement.

Possible stimuli for eliciting a sympathetic response include pain, fear, anticipation, anxiety, concentration or memory, cold pressor, Stroop test, breathing tests, and maximal hand grip. Examples of parasympathetic stimuli are the Valsalva maneuver and paced breathing. The responses to stimuli (ie, heart rate, heart rate variability, blood pressure, galvanic skin response, papillary response) must be monitored to compare the data obtained from fMRI. MRI-compatible equipment is now available for measuring many of these responses.



**FIGURE 2.** Magnetic resonance imaging in a patient with Shy-Drager (left) is normal; a “hot cross buns” sign may be evident in patients with multiple-system atrophy (right).



**FIGURE 3.** Examples of magnetic resonance imaging susceptibility to motion artifacts before and after filtering in an electrocardiogram and a photoplethysmogram.

### Identifying areas activated during tasks

Functional neuroimaging with PET and fMRI has shown consistently that the anterior cingulate is activated during multiple tasks designed to elicit an autonomic response (gambling anticipation, emotional response to faces, Stroop test).<sup>11</sup>

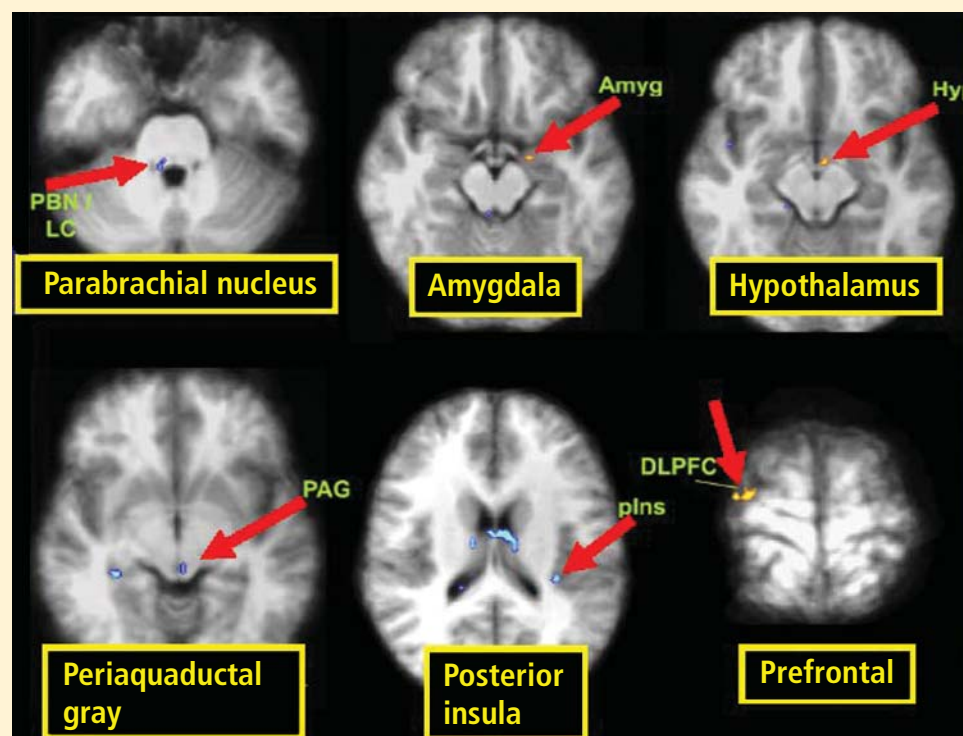
In a study designed to test autonomic interoceptive awareness, subjects underwent fMRI while they were asked to judge the timing of their heartbeats to

auditory tones that were either synchronized with their heartbeat or delayed by 500 msec.<sup>13</sup> Areas of enhanced activity during the task were the right insular cortex, anterior cingulate, parietal lobes, and operculum.

### Characterizing brainstem sites

It is difficult to achieve visualization of areas within the brainstem that govern autonomic responses. These





**FIGURE 4.** Despite the difficulty of visualizing brainstem areas that govern autonomic response, functional magnetic resonance imaging and electrocardiographic data demonstrated brainstem regions that correlated with autonomic involvement during a handgrip task.<sup>16</sup>

Reprinted from *NeuroImage* (Napadow V, et al. Brain correlates of autonomic modulation: combining heart rate variability with fMRI. *NeuroImage* 2008; 42:169–177), Copyright © 2008, with permission from Elsevier. <http://www.sciencedirect.com/science/journal/10538119>

regions are small and motion artifacts are common because of brainstem movement with the cardiac pulse. With fMRI, Topolovec et al<sup>14</sup> were able to characterize brainstem sites involved in autonomic control, demonstrating activation of the nucleus of the solitary tract and parabrachial nucleus.

Using fMRI and electrocardiographic data obtained simultaneously, Napadow et al<sup>15</sup> attempted to assess brain correlates of autonomic function in subjects performing an MRI-compatible handgrip task. Brainstem regions that co-localized with expected areas of autonomic involvement were the parabrachial nucleus, amygdala, hypothalamus, periaqueductal gray area, posterior insula, and prefrontal cortex (**Figure 4**).

A review of four fMRI studies of stressor-evoked blood pressure reactivity demonstrated activation in corticolimbic areas, including the cingulate cortex, insula, amygdala, and cortical and subcortical areas that are involved in hemodynamic and metabolic support for stress-related behavioral responses.<sup>16</sup>

## FUNCTIONAL BRAIN IMAGING IN DISEASE STATES

There are few studies of functional brain imaging in patients with disease because of the challenges involved. The studies are difficult to perform on sick

patients because of the unfriendly MRI environment, with strict requirements for attention and participation. Furthermore, autonomic responses may be blunted, making physiologic comparisons difficult. In addition, there is evidence that BOLD may be intrinsically impaired in disease states. Unlike fMRI studies to locate brain regions involved in simple tasks such as finger tapping, which can be performed in a single subject, detecting changes in autonomic responses in disease states requires averaging over studies of multiple patients.

Woo et al<sup>17</sup> used fMRI to compare brain regions of activation in six patients with heart failure and 16 controls upon a forehead cold pressor challenge. Increases in heart rate were measured in the patients with heart failure with application of the cold stimulus. Larger neural fMRI signal responses in patients with heart failure were observed in 14 brain regions, whereas reduced fMRI activity was observed in 15 other brain regions in the heart failure patients. Based on the results, the investigators suggested that heart failure may be associated with altered sympathetic and parasympathetic activity, and that these dysfunctions might contribute to the progression of heart failure.

Gianaros et al<sup>18</sup> found fMRI evidence for a correla-

tion between carotid artery intima-media thickness, a surrogate measure for carotid artery or coronary artery disease, and altered ANS reaction to fear using a fearful faces paradigm.

## CONCLUSION

Functional MRI of heart-brain interactions has strong potential for normal subjects, in whom the BOLD effect is small, within the limits of motion and susceptibility artifacts. Typically, such applications require averaging results over multiple subjects. Its potential utility in disease states is less significant because of the additional limitations of MRI with sick patients (the MRI environment, blunting of autonomic response in disease, possible impairment of BOLD), but continued investigation is warranted.

## REFERENCES

1. Sevcencu C, Struijk JJ. Autonomic alterations and cardiac changes in epilepsy. *Epilepsia* 2010; 51:725–737.
2. Kodounis A, Stamboulis E, Constantinidis TS, Liolios A. Measurement of autonomic dysregulation in multiple sclerosis. *Acta Neurol Scand* 2005; 112:403–408.
3. Flachenecker P, Wolf A, Krauser M, Hartung HP, Reiners K. Cardiovascular autonomic dysfunction in multiple sclerosis: correlation with orthostatic intolerance. *J Neurol* 1999; 246:578–586.
4. Kulcu DG, Akbas B, Citci B, Cihangiroglu M. Autonomic dysreflexia in a man with multiple sclerosis. *J Spinal Cord Med* 2009; 32:198–203.
5. Abboud H, Berroir S, Labreuche J, Orjuele K, Amarenco O. Insular involvement in brain infarction increases risk for cardiac arrhythmia and death. *Ann Neurol* 2006; 59:691–699.
6. Tokgozlu SL, Batur MK, Topcuoglu MA, Saribas O, Kes S, Oto A. Effects of stroke localization on cardiac autonomic balance and sudden death. *Stroke* 1999; 30:1301–1311.
7. Strittmatter M, Meyer S, Fischer C, Georg T, Schmitz B. Location-dependent patterns in cardio-autonomic dysfunction in ischaemic stroke. *Eur Neurol* 2003; 50:30–38.
8. Lassman AB, Mayer SA. Paroxysmal apnea and vasomotor instability following medullary infarction. *Arch Neurol* 2005; 62:1286–1288.
9. Deluca C, Tinazzi M, Bovi P, Rizzuto N, Moretto G. Limb ataxia and proximal intracranial territory brain infarcts: clinical and topographical correlations. *J Neurol Neurosurg Psychiatry* 2007; 78:832–835.
10. Gómez-Esteban JC, Berganzo K, Tijero B, Barcena J, Zarranz JJ. Orthostatic hypotension associated with an epidermoid tumor of the IV ventricle. *J Neurol* 2009; 256:1357–1359.
11. Critchley HD. Neural mechanisms of autonomic, affective, and cognitive integration. *J Comp Neurol* 2005; 493:154–166.
12. Ogawa S, Lee TM, Kay AR, Tank DW. Brain magnetic resonance imaging with contrast dependent on blood oxygenation. *Proc Natl Acad Sci USA* 1990; 87:9868–9872.
13. Critchley HD. The human cortex responds to an interoceptive challenge. *Proc Natl Acad Sci USA* 2004; 101:6333–6334.
14. Topolovec JC, Gati JS, Menon RS, Shoemaker JK, Cechetto DE. Human cardiovascular and gustatory brainstem sites observed by functional magnetic resonance imaging. *J Comp Neurol* 2004; 471:446–461.
15. Napadow V, Dhond R, Conti G, Makris N, Brown EN, Barbieri R. Brain correlates of autonomic modulation: combining heart rate variability with fMRI. *Neuroimage* 2008; 42:169–177.
16. Gianaros PJ, Sheu LK. A review of neuroimaging studies of stressor-evoked blood pressure reactivity: emerging evidence for a brain-body pathway to coronary heart disease risk. *Neuroimage* 2009; 47:922–936.
17. Woo MA, Macey PM, Keens PT, et al. Functional abnormalities in brain areas that mediate autonomic nervous system control in advanced heart failure. *J Card Fail* 2005; 11:437–446.
18. Gianaros PJ, Hariri AR, Sheu LK, et al. Preclinical atherosclerosis covaries with individual differences in reactivity and functional connectivity of the amygdala. *Biol Psych* 2009; 65:943–950.

**Correspondence:** Stephen E. Jones, MD, PhD, Department of Neuroradiology, Cleveland Clinic, 9500 Euclid Avenue, U15, Cleveland, OH 44195; [jones19@ccf.org](mailto:jones19@ccf.org)