

# TOTAL GASTRECTOMY

## *Report of a Case*

T. E. JONES, M.D.

The following case is reported to point out several features. First, the tardiness with which these patients present themselves. This patient had gastric symptoms for a year before the diagnosis was made, a situation which has a distinct bearing upon operability and curability. Second, total gastrectomy is a feasible operation in selected cases, as many reports in the past ten years have indicated. This patient had sixteen months of comfortable productive life, whereas, I am sure, ten years ago total gastrectomy would have been considered impractical. Third, this case demonstrates that without any anti-anemic therapy the patient was able to maintain an active life and a stationary weight with a normal blood volume and cell counts.

## CASE REPORT

A man, 44 years of age, was admitted to the hospital in April, 1940. He complained of a dull, gnawing epigastric discomfort of one year's duration, which occurred immediately after meals and was not relieved by food or antacids. There had never been any nausea or vomiting. The bowel habits were normal and no tarry stools had been noted. The patient had lost 20 pounds in weight since the onset of his illness, which he attributed to a gradual loss of appetite.

Physical examination revealed no abnormalities. The patient weighed 206 pounds, and appeared to be in good general health. No abdominal masses, organs, or clavicular nodes were palpable. Examination of the rectum was negative. The red blood cells numbered 4,900,000, and the hemoglobin was 91 per cent.

A roentgenogram of the stomach demonstrated a constant narrow channel in the pars media with some rigidity of the walls and an obliteration of the normal mucosal markings (Fig. 1). The stomach emptied rapidly, peristalsis passed normally through the distal third of the stomach, and the duodenal bulb filled well.

An exploratory operation was done on the upper abdomen. The middle third of the stomach was involved by an extensive infiltrating neoplasm which was confined chiefly to the posterior wall and the lesser curvature. The lesion was mobile. Several glands were thought to be palpable in the gastrohepatic omentum, but there was no gross evidence of glandular metastasis. The liver was normal and there was no evidence of metastasis to the rectovesical pouch. The entire stomach was resected. A loop of jejunum was brought through the transverse mesocolon and anastomosed to the esophagus with three rows of silk sutures. A Levine tube was passed into the proximal jejunal loop,

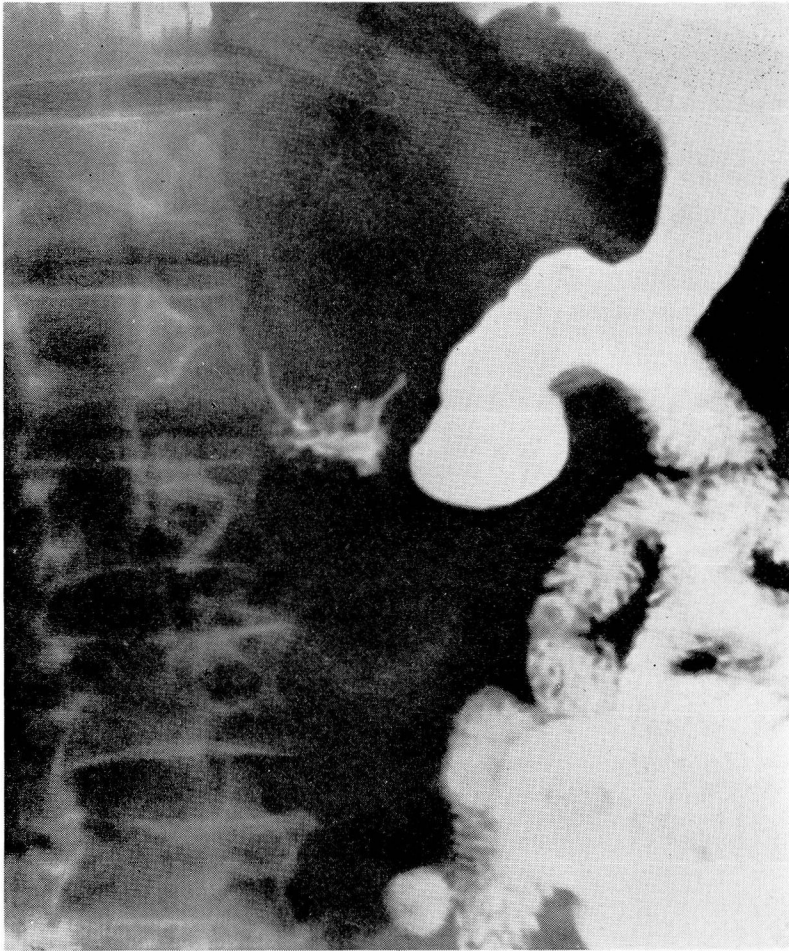


FIGURE 1: Roentgenogram of the stomach showing a constant narrow channel in the pars media with some rigidity of the walls and an obliteration of normal mucosal markings.

and an entero-enterostomy was made distal to the anastomosis and below the transverse mesocolon.

The postoperative course was uneventful, except for a mild lobar atelectasis. The patient was discharged from the hospital on the twenty-first postoperative day.

Pathologic examination of the stomach showed no evidence of involvement of the peritoneal surface and no ulceration of the mucosa. The rugae were hypertrophied and the entire stomach wall was thickened and nodular, particularly in the middle third. Microscopic examination showed a highly undifferentiated neoplasm with no tendency to form glands. There was no evidence of metastasis to regional lymph nodes removed with the stomach.

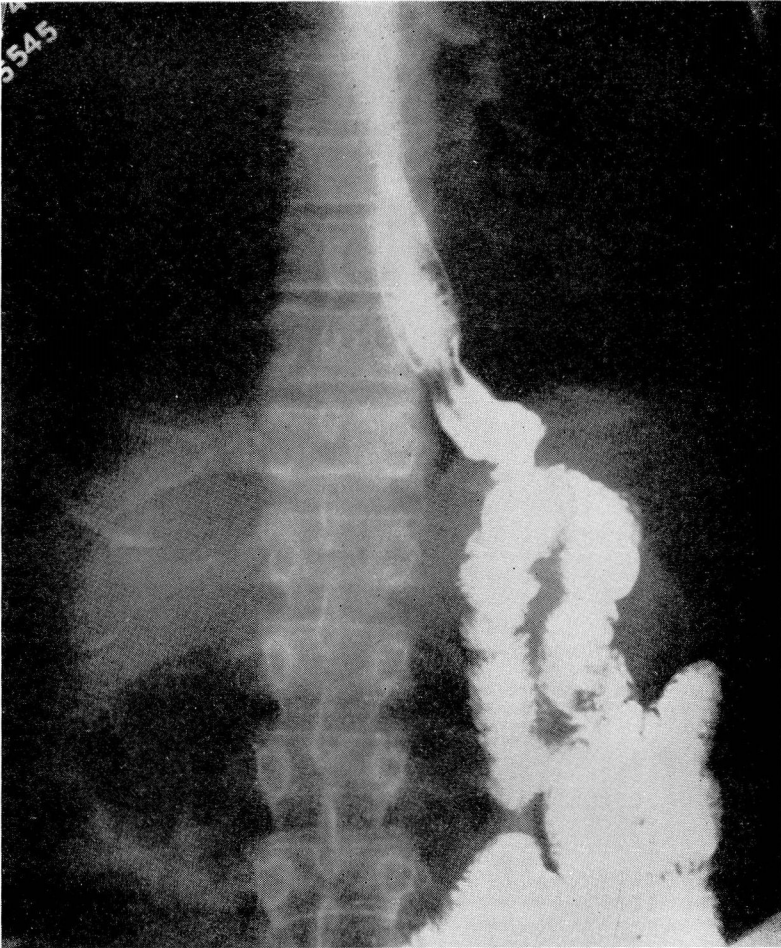


FIGURE 2: Roentgenogram after a barium meal, showing the stoma to be functioning well.

This patient was well for sixteen months and worked daily as an electrician until a few days before his second admission in September, 1941. He had had almost no difficulty with his diet, and within the first month postoperatively he was able to eat three full meals a day without restrictions. A constant weight of 170 pounds had been maintained. The red blood cell count, hemoglobin, and color and volume indices of the blood remained within normal limits without anti-anemic therapy.

In September, 1941, at our request, the patient returned for radiologic examination. His general health was good. A barium meal showed the stoma to be functioning well (Fig. 2). The day after this examination the patient complained of abdominal

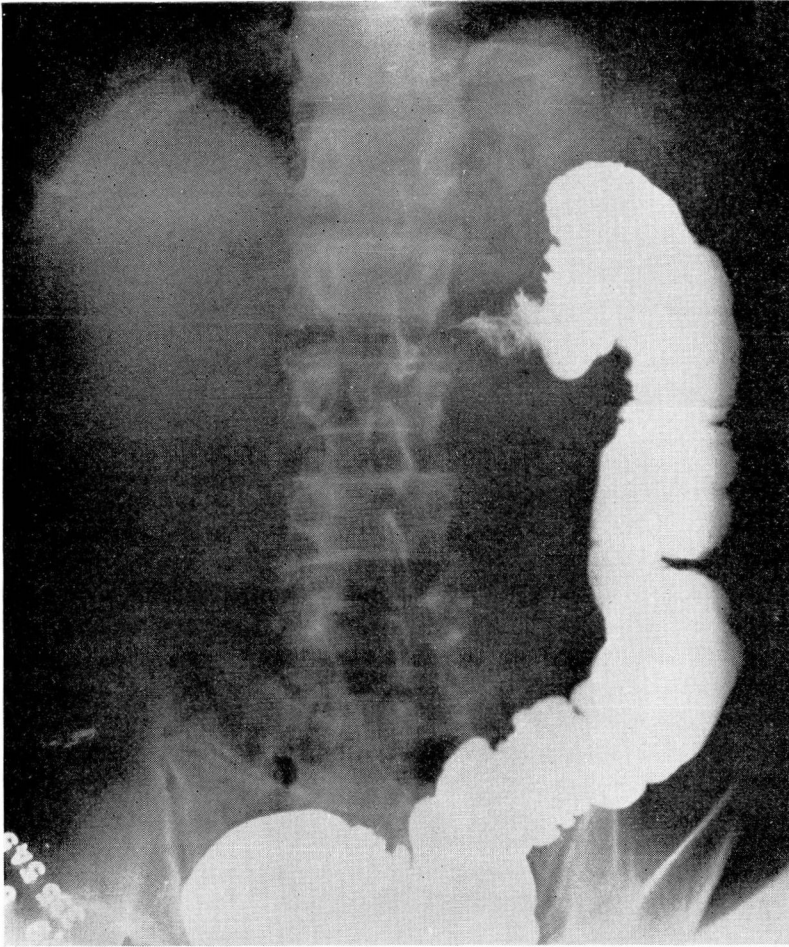


FIGURE 3: Roentgenogram of the abdomen 48 hours after barium meal, showing an annular, obstructing lesion just proximal to the splenic flexure of the colon.

cramps and some distention. A plain roentgenogram of the abdomen, forty-eight hours after the barium meal, showed an annular, obstructing lesion just proximal to the splenic flexure of the colon (Fig. 3). Following the use of enemas and small doses of Epsom salts the barium was expelled and the abdominal distention subsided. The patient stated, in retrospect, that he had noted an occasional abdominal cramp for one week before this admission, but that the bowel habits had not changed in any way.

The lesion near the splenic flexure was again visualized following a barium enema (Fig. 4). Mucosal markings were observed through the obstructed area. The radiologic diagnosis was colonic obstruction, extrinsic in origin.

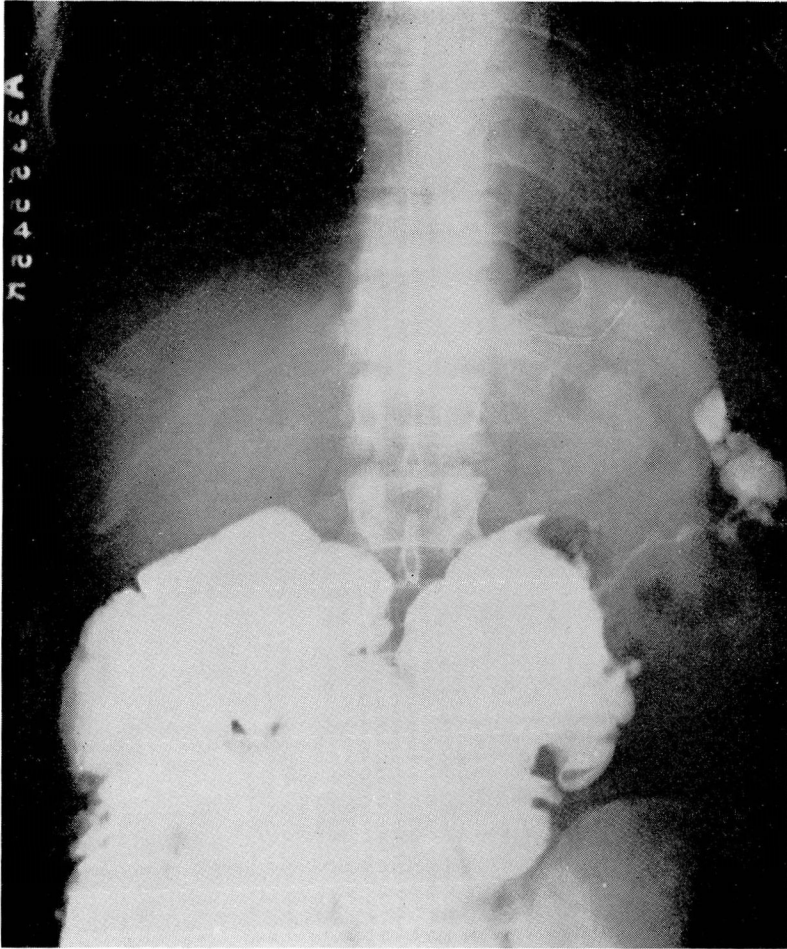


FIGURE 4: Roentgenogram following a barium enema, again demonstrating the lesion near the splenic flexure.

An exploratory operation was again performed, seventeen months after the gastric resection. The distal third of the transverse colon was involved in a metastatic omental mass. Several loops of small bowel were adherent in this area. Additional metastatic deposits were present throughout the abdomen. Iliosigmoidostomy beyond this obstruction was not feasible because obstruction high in the small intestine involved in the mass would soon ensue. The operative wound was closed.

The patient was discharged from the hospital on the eighteenth postoperative day, his condition unimproved.