

Q: Is anticoagulation appropriate for all patients with portal vein thrombosis?

BRADLEY D. CONFER, DO

Digestive Disease Institute, Cleveland Clinic

IBRAHIM HANOUNEH, MD

Digestive Disease Institute, Cleveland Clinic

MARCELO GOMES, MD

Department of Cardiovascular Medicine, Heart and Vascular Institute, Cleveland Clinic

M. CHADI ALRAIES, MD

Clinical Assistant Professor of Medicine, Cleveland Clinic Lerner College of Medicine of Case Western Reserve University, Cleveland, OH, and Department of Hospital Medicine, Cleveland Clinic

A: NO. IN GENERAL, the decision to treat portal vein thrombosis with anticoagulant drugs is complex and depends on whether the thrombosis is acute or chronic, and whether the cause is a local factor, cirrhosis of the liver, or a systemic condition (TABLE 1). A “one-size-fits-all” approach should be avoided (FIGURE 1).

■ ACUTE PORTAL VEIN THROMBOSIS WITHOUT CIRRHOSIS

No randomized controlled trial has yet evaluated anticoagulation in acute portal vein thrombosis. But a prospective study published in 2010 showed that the portal vein and its left or right branch were patent in 39% of anticoagulated patients (vs 13% initially), the splenic vein in 80% (vs 57% initially), and the superior mesenteric vein in 73% (vs 42% initially).¹ Further, there appears to be a 20% reduction in the overall mortality rate associated with anticoagulation for acute portal vein thrombosis in retrospective studies.²

In the absence of contraindications, anticoagulation with heparin or low-molecular-weight heparin is recommended, with complete bridging to oral anticoagulation with a vitamin K antagonist. Anticoagulation should be continued for at least 3 months, and indefi-

doi:10.3949/ccjm.80a.12136

TABLE 1

Risk factors for portal vein thrombosis

Local factors

Abdominal infection or sepsis

Acute appendicitis, cholangitis, cholecystitis, pancreatitis, diverticulitis, abdominal abscess

Abdominal surgery

Especially surgery for abdominal infection, inflammatory bowel disease, abdominal malignancy

Abdominal trauma

Liver cirrhosis

Hypercoagulable states, thrombophilia

Antiphospholipid antibody syndrome

Antithrombin deficiency

Behçet disease

Cancer

Factor V Leiden mutation

Heparin-induced thrombocytopenia

Inflammatory bowel disease

Janus kinase 2 (*JAK2*) polymorphism

Monoclonal gammopathy

Myeloproliferative disorder

Oral contraceptive use

Paroxysmal nocturnal hemoglobinuria

Pregnancy

Protein C deficiency

Protein S deficiency

Prothrombin thrombophilia (20210G>A mutation)

nately in patients with permanent hypercoagulable risk factors.³

■ CHRONIC PORTAL VEIN THROMBOSIS WITHOUT CIRRHOSIS

All patients with chronic portal vein thrombosis should undergo esophagogastroduodenoscopy to evaluate for varices. Patients with

Each case must be evaluated individually with expert consultation

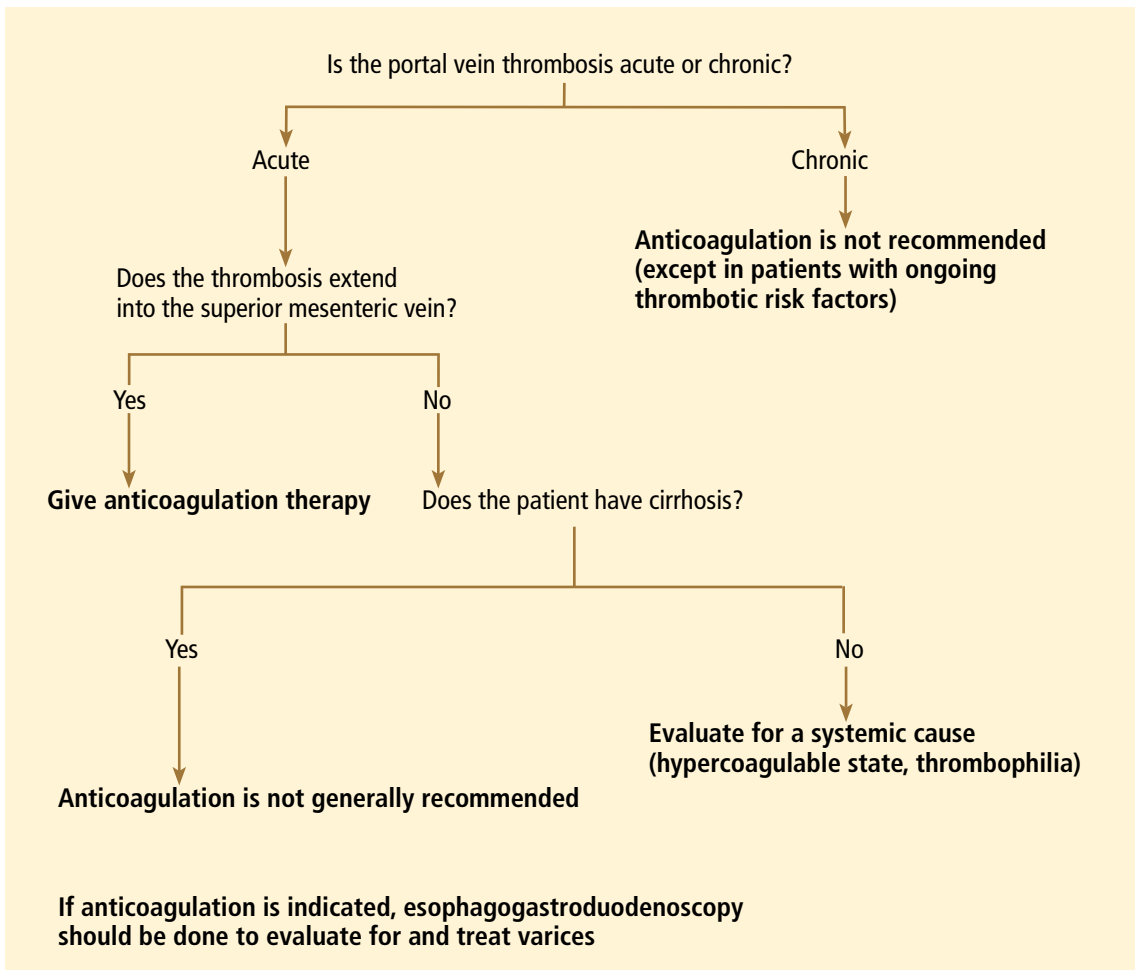


FIGURE 1. Algorithm for deciding when anticoagulation therapy for portal vein thrombosis is appropriate.

Portal vein thrombosis is common in patients with underlying cirrhosis

large varices should be treated orally with a nonselective beta-adrenergic blocker or endoscopically. Though no prospective study has validated this practice, a retrospective analysis showed a decreased risk of first or recurrent bleeding.⁴

In 2007, a retrospective study showed a lower rate of death in patients with portomesenteric venous thrombosis treated with an oral vitamin K antagonist.⁵ Patients with chronic portal vein thrombosis with ongoing thrombotic risk factors should be treated with long-term anticoagulation after screening for varices, and if varices are present, primary prophylaxis should be started.³ With this approach, less than 5% of patients died from classic complications of portal vein thrombosis at 5 years of follow-up.⁴

ACUTE OR CHRONIC PORTAL VEIN THROMBOSIS WITH CIRRHOSIS

Portal vein thrombosis is common in patients with underlying cirrhosis. The risk in patients with cirrhosis significantly increases as liver function worsens. In patients with well-compensated cirrhosis, the risk is less than 1% vs 8% to 25% in those with advanced cirrhosis.⁶

In patients awaiting liver transplantation, a large retrospective study⁷ showed that the rate of partial or complete recanalization of the splanchnic veins was significantly higher in those who received anticoagulation (8 of 19) than in those who did not (0 of 10, $P = .002$). The rate of survival was significantly lower in those who had complete thrombotic

obstruction of the portal vein at the time of surgery ($P = .04$). However, there was no difference in survival rates between those with partial obstruction who received anticoagulation and those with a patent portal vein.⁷

A later retrospective study⁸ showed no significant benefit in the rate of transplantation-free survival or survival after liver transplantation in patients with or without chronic portal vein thrombosis.⁸

Unfortunately, we have no data from prospective controlled trials and only limited data from retrospective studies to make a strong recommendation for or against anticoagulation in either acute and chronic portal vein thrombosis associated with cirrhosis. As

such, each case must be evaluated on an individual basis in association with expert consultation.

In our experience, the risk of bleeding in patients with liver cirrhosis is substantial because of the decreased synthesis of coagulation factors and the presence of varices, whereas the efficacy and the benefits of recanalizing the portal vein in asymptomatic patients with liver cirrhosis and portal vein thrombosis are unknown. Therefore, unless the thrombosis extends into the mesenteric vein, thus posing a risk of mesenteric ischemia, we do not generally recommend anticoagulation in asymptomatic portal vein thrombosis in patients with cirrhosis. ■

REFERENCES

1. Plessier A, Darwish-Murad S, Hernandez-Guerra M, et al; European Network for Vascular Disorders of the Liver (EN-Vie). Acute portal vein thrombosis unrelated to cirrhosis: a prospective multicenter follow-up study. *Hepatology* 2010; 51:210–218.
2. Kumar S, Sarr MG, Kamath PS. Mesenteric venous thrombosis. *N Engl J Med* 2001; 345:1683–1688.
3. de Franchis R. Evolving consensus in portal hypertension. Report of the Baveno IV consensus workshop on methodology of diagnosis and therapy in portal hypertension. *J Hepatol* 2005; 43:167–176.
4. Condat B, Pessione F, Hillaire S, et al. Current outcome of portal vein thrombosis in adults: risk and benefit of anticoagulant therapy. *Gastroenterology* 2001; 120:490–497.
5. Orr DW, Harrison PM, Devlin J, et al. Chronic mesenteric venous thrombosis: evaluation and determinants of survival during long-term follow-up. *Clin Gastroenterol Hepatol* 2007; 5:80–86.
6. DeLeve LD, Valla DC, Garcia-Tsao G; American Association for the Study of Liver Diseases. Vascular disorders of the liver. *Hepatology* 2009; 49:1729–1764.
7. Francoz C, Belghiti J, Vilgrain V, et al. Splanchnic vein thrombosis in candidates for liver transplantation: usefulness of screening and anticoagulation. *Gut* 2005; 54:691–697.
8. John BV, Konjeti VR, Aggarwal A, et al. The impact of portal vein thrombosis (PVT) on cirrhotics awaiting liver transplantation (abstract). *Hepatology* 2010; 52(suppl1):888A–889A.

ADDRESS: M. Chadi Alraies, MD, Department of Hospital Medicine, A13, Cleveland Clinic, 9500 Euclid Avenue, Cleveland, OH 44195; e-mail: alraies@hotmail.com