

## THE CLINICAL PICTURE

**CONG J. LI, MD**

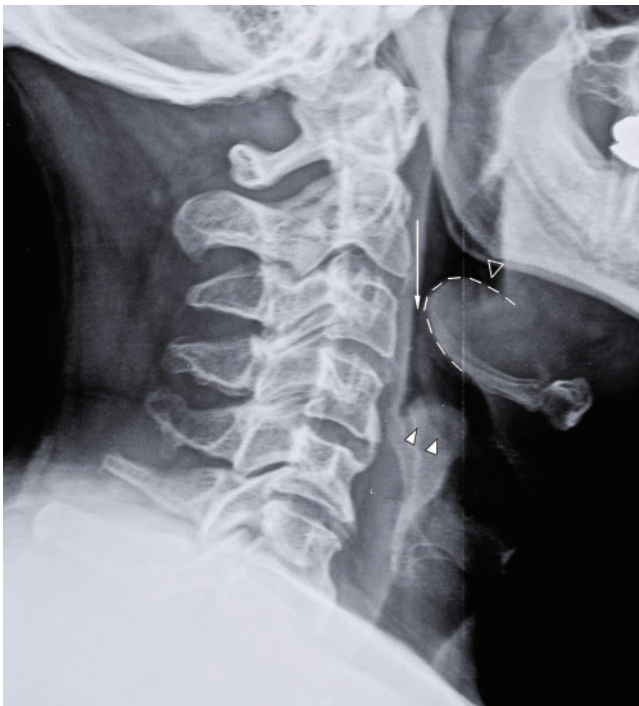
Department of Medicine, California Pacific  
Medical Center, San Francisco, CA

**PAUL ARONOWITZ, MD, FACP**

Program Director, Internal Medicine Residency,  
Department of Medicine, California Pacific  
Medical Center, San Francisco, CA

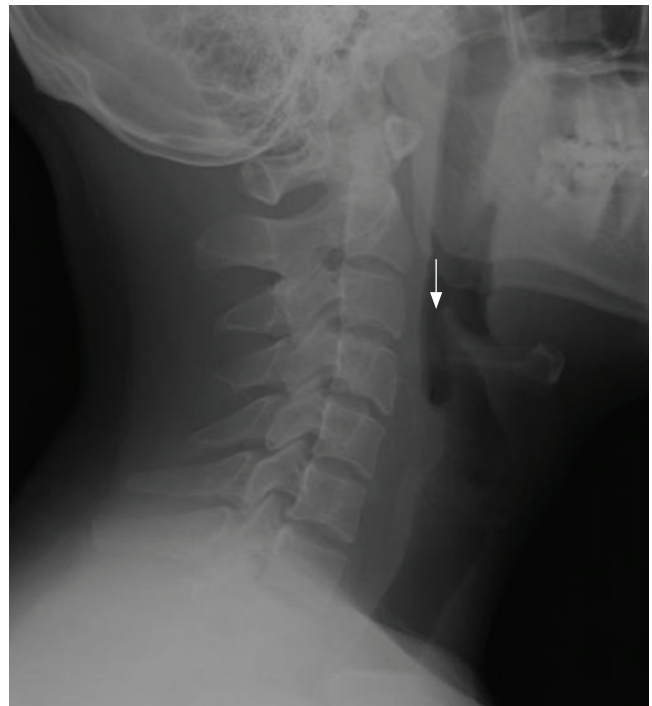# The Clinical Picture

## Sore throat, odynophagia, hoarseness, and a muffled, high-pitched voice



**FIGURE 1.** A lateral soft-tissue radiograph in our patient shows the epiglottis (outlined by dashed lines) consistent with acute epiglottitis and a narrowed airway (thin vertical arrow). Swollen arytenoids (two solid triangles) and a shallow, V-shaped epiglottic vallecula (single open triangle) are also shown.

**A** 55-YEAR-OLD MAN presents to the emergency department with a sore throat, odynophagia, hoarseness, and a high-pitched muffled voice for 1 day. He is otherwise healthy, with no fever, chills, or exposure to sick contacts.



**FIGURE 2.** A lateral soft-tissue radiograph from a different patient shows a normal epiglottis (arrow).

**Q:** Which is the most likely diagnosis?

- Retropharyngeal abscess
- Croup
- Streptococcal pharyngitis (“strep throat”)
- Acute epiglottitis
- Viral upper-respiratory infection

**A:** The correct answer is acute epiglottitis.

Acute epiglottitis is a cellulitis of the epiglottis and adjacent tissues that, without treatment, can progress to life-threatening airway obstruction.

In children, this entity most often occurs between

doi:10.3949/ccjm.80a.12056

ages 2 and 4. Previously, it was mainly associated with *Haemophilus influenzae* type B infection, but since the start of vaccination for this organism, epiglottitis has become less common.

In recent years, *Streptococcus pneumoniae* and beta-hemolytic streptococci have become the main culprits in epiglottitis in children. In adults, common organisms include *H influenzae*, *S pneumoniae*, *Staphylococcus aureus*, and beta-hemolytic streptococci. Epiglottitis may also be caused by herpes simplex, varicella-zoster, and influenza viruses. Noninfectious causes include ingestion of a foreign body and thermal injury.

Common signs and symptoms of epiglottitis include sore throat, a high-pitched and muffled voice, labored breathing, and respiratory distress.<sup>1</sup> Since airway obstruction can be remarkably precipitous, it is important to obtain early consultation with an otolaryngologist for laryngoscopy and visualization of the erythematous, swollen epiglottis. Signs of severe upper-airway obstruction may be absent until late in the disease process, making early diagnosis crucial.

On physical examination, the oropharynx will often appear benign. Currently, the preferred diagnostic test for epiglottitis is visualization by laryngoscopy, which has close to 100% sensitivity and specificity.<sup>2</sup> By comparison, lateral neck radiography has poor sensitivity (38% to 88%) and specificity (78%).<sup>3,4</sup> Bedside ultrasonography has been reported as capable of revealing the “alphabet P sign” in the longitudinal view through the thyrohyoid membrane.<sup>5</sup>

At triage, if clinical suspicion of total airway obstruction is high, the patient may be taken directly to the operating room for visualization of the epiglottis and, if necessary, for endotracheal intubation. When the risk is considered low or moderate, lateral neck radiography may be helpful,<sup>6</sup> as it will sometimes reveal a swollen epiglottis (ie, “thumb sign”), thickened arytenoepiglottic folds, and obliteration of the epiglottic vallecula. If the

radiograph is normal and clinical suspicion is still present, laryngoscopy can be done.

For low-risk, acute epiglottitis, closely monitoring the patient in an intensive care unit is recommended. For severe, high-risk cases, securing the airway is of the utmost importance. In addition to securing the airway, empiric antimicrobial therapy—such as with cefotaxime or ceftriaxone plus clindamycin or vancomycin—is often warranted in both low-risk and high-risk cases. The use of corticosteroids in epiglottitis has not been studied in a randomized, controlled trial, and, though common, it remains controversial.<sup>7</sup> While undergoing treatment, patients should be closely monitored for respiratory compromise.

## ■ HOW OUR PATIENT WAS MANAGED

Our patient had a high-pitched, muffled voice and prominent, tender anterior cervical lymph nodes. No drooling or stridor was noted. The oropharynx appeared normal. Lateral soft-tissue radiography of the neck (FIGURE 1) revealed several key findings:

- A swollen epiglottis (ie, the “thumb sign”) consistent with acute epiglottitis and a narrowed airway
- Swollen arytenoids
- A shallow V-shaped epiglottic vallecula.

For comparison, FIGURE 2 shows a normal lateral soft-tissue radiograph of the neck from a different patient.

Our patient was referred to an otolaryngologist, who noted a severely inflamed epiglottis on laryngoscopy.

The patient was given intravenous vancomycin, ceftriaxone, and high-dose corticosteroids and was admitted to the intensive care unit. After his symptoms improved, repeat laryngoscopy revealed markedly diminished inflammation. He was discharged home with an additional course of oral antibiotics. ■

**Without treatment, epiglottitis can progress to life-threatening airway obstruction**

## ■ REFERENCES

1. **Alcaide ML, Bisno AL.** Pharyngitis and epiglottitis. *Infect Dis Clin North Am* 2007; 21:449–469.
2. **Cheung CS, Man SY, Graham CA, et al.** Adult epiglottitis: 6 years experience in a university teaching hospital in Hong Kong. *Eur J Emerg Med* 2009; 16:221–226.
3. **Stankiewicz JA, Bowes AK.** Croup and epiglottitis: a radiologic study. *Laryngoscope* 1985; 95:1159–1160.
4. **Solomon P, Weisbrod M, Irish JC, Gullane PJ.** Adult epiglottitis: the Toronto Hospital experience. *J Otolaryngol* 1998; 27:332–336.
5. **Hung TY, Li S, Chen PS, et al.** Bedside ultrasonography as a safe and effective tool to diagnose acute epiglottitis. *Am J Emerg Med* 2011; 29:359.e1–359.e3.
6. **Ragosta KG, Orr R, Detweiler MJ.** Revisiting epiglottitis: a protocol—the value of lateral neck radiographs. *J Am Osteopath Assoc* 1997; 97:227–229.
7. **Glynn F, Fenton JE.** Diagnosis and management of supraglottitis (epiglottitis). *Curr Infect Dis Rep* 2008; 10:200–204.

ADDRESS: Cong J. Li, MD, Department of Medicine, California Pacific Medical Center, 2351 Clay St., Suite 360, San Francisco, CA 94115; e-mail LiJ2@Sutterhealth.org.