

THE CLINICAL PICTURE

JOSÉ RAMÓN ESTELA CUBELLS, MD

Department of Dermatology, Valencia University
General Hospital, Valencia, Spain

AMPARO PÉREZ FERRIOLS, MD

Department of Dermatology, Valencia University
General Hospital, and University of Valencia,
Valencia, Spain

VÍCTOR ALEGRE DE MIQUEL, MD

Department of Dermatology, Valencia University
General Hospital, Valencia, Spain

The Clinical Picture

Slow-growing angiomatous lesions on the limbs

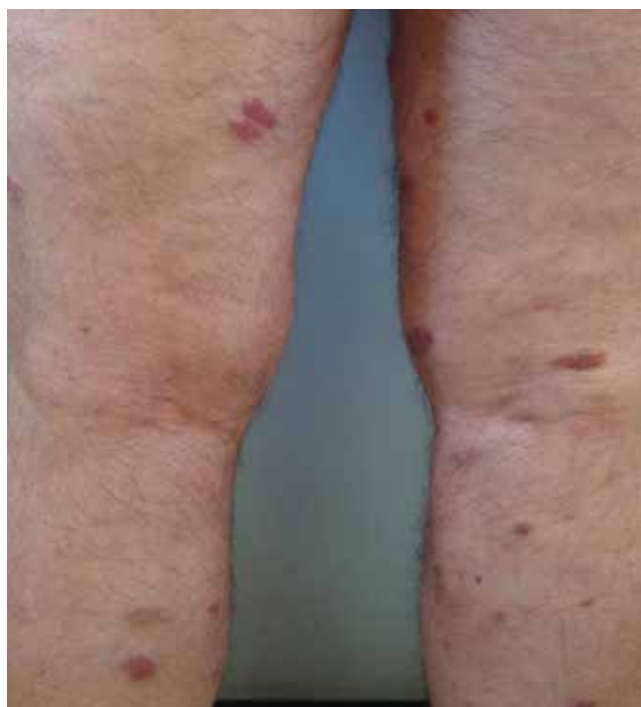
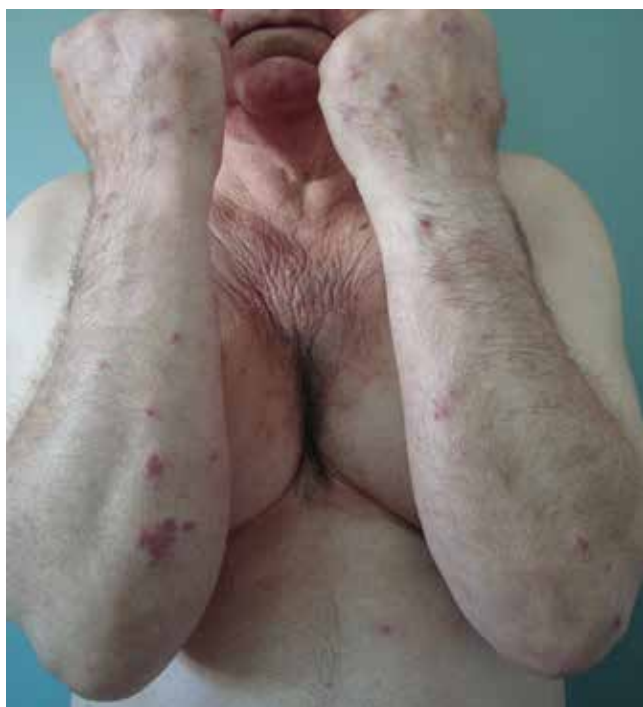
FIGURE 1. The poorly demarcated erythematous plaques had infiltrated the skin on the arms and legs.

A 70-YEAR-OLD MAN presented with multiple erythematous plaques on the arms and legs (**FIGURE 1**). The plaques had infiltrated the skin and were poorly demarcated.

He had hypertension but no history of other relevant medical conditions, and he was not taking any medication. He was not neutropenic or immunocompromised.

In a patient after the sixth decade of life, erythematous plate-shaped lesions on the legs that become apparent on palpation should raise suspicion of classic Kaposi sarcoma. A biopsy confirmed this diagnosis (**FIGURE 2**).

Immunohistochemical staining was positive for human herpesvirus 8 latent nuclear antigen. Clinical examination, computed tomography, and blood tests showed no extracutaneous involvement or other associated pathology. He was treated with paclitaxel, which resulted in improvement of his symptoms.

■ DIFFERENTIAL DIAGNOSIS

Bacillary angiomatosis, acroangiokeratosis (“pseudo-Kaposi sarcoma”) and atypical mycobacterial infections such as *Mycobacterium marinum* infection may present as papules or nodules on the legs.

doi:10.3949/ccjm.81a.13058

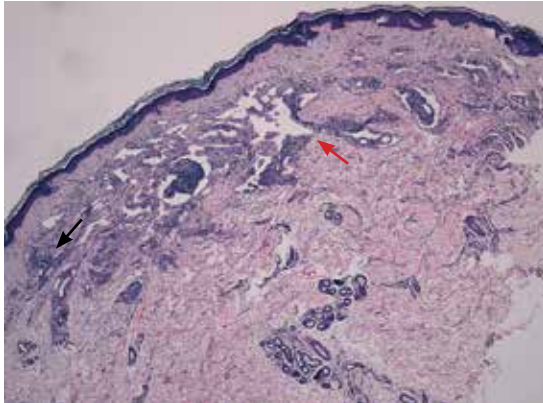


FIGURE 2. Histologic examination showed dissecting vessel proliferation of collagen fibers in the superficial dermis, along with superficial perivascular lymphoplasmacytic infiltration (black arrow). Note the central location of the lymphangioma-like spaces (red arrow) (hematoxylin and eosin, x 10).

Bacillary angiomatosis

Bacillary angiomatosis is more common in patients with acquired immunodeficiency syndrome and other forms of immunosuppression. Bacilli are produced by *Bartonella henselae* and *B quintana* and are a manifestation of cat-scratch disease in an immunocompromised host.¹ The disease manifests as pyogenic granuloma-like lesions or subcutaneous nodules and may be associated with liver damage and systemic impairment.

Acroangiodermatitis

Acroangiodermatitis, or pseudo-Kaposi sarcoma, is caused by hyperplasia of the venous vasculature or chronic venous stasis. It is an entity observed in amputees, in hemodialysis patients with an arteriovenous fistula who are

infected with hepatitis C virus, and in patients with vascular malformations.²⁻³ It presents as plaques or violaceous papules on the legs.

M marinum infection

This syndrome presents clinically with erythematous papular and nodular lesions on the skin surface. They can appear on the knees and feet of people infected while swimming in pools, or on the hands of aquarium owners.⁴⁻⁵ A high index of suspicion and a complete medical history are key to properly diagnosing this disease.

CLASSIC KAPOSI SARCOMA

Kaposi sarcoma is a neoplasm of lymphatic endothelial cells. Four types have been described: classic, endemic, iatrogenic, and associated with human immunodeficiency virus infection.

The disease affects men and women around the sixth decade of life. It is more common in Ashkenazi Jews and people of Mediterranean origin. It presents as slow-growing plaques or nodules on the lower extremities; a disseminated form or internal organ involvement is rare.⁶

Histologic study reveals vascular proliferation with superficial perivascular lymphoplasmacytic infiltration, displaying the classic formation of new vessels from pre-existing vessels. It has a benign course that may last 10 years. Single lesions can be removed surgically or can be treated with chemotherapy. Advanced disease requires systemic chemotherapy with pegylated liposomal doxorubicin, interferon alfa-2a, paclitaxel, or bleomycin and vinblastine.^{7,8}

REFERENCES

1. Zarraga M, Rosen L, Herschthal D. Bacillary angiomatosis in an immunocompetent child: a case report and review of the literature. *Am J Dermatopathol* 2011; 33:513-515.
2. Brenner S, Martinez de Morentin E. What's new in pseudo-Kaposi's sarcoma. *J Eur Acad Dermatol Venereol* 2001; 15:382-384.
3. Mehta AA, Pereira RR, Nayak CS, Dhurat RS. Acroangiodermatitis of mali: a rare vascular phenomenon. *Indian J Dermatol Venereol Leprol* 2010; 76:553-556.
4. Petrini B. *Mycobacterium marinum*: ubiquitous agent of waterborne granulomatous skin infections. *Eur J Clin Microbiol Infect Dis* 2006; 25:609-613.
5. Aboutaleb A, Shen A, Katta R, Allen SE. Primary cutaneous infection by *Mycobacterium avium*: a case report and

literature review. *Cutis* 2012; 89:175-179.

6. Kandemir NO, Yurdakan G, Bektas S, Tekin NS. Classic Kaposi sarcoma with sarcoid-like granulomas: a case report and literature review. *Exp Mol Pathol* 2009; 87:89-93.
7. Régnier-Rosenschner E, Guillot B, Dupin N. Treatments for classic Kaposi sarcoma: a systematic review of the literature. *J Am Acad Dermatol* 2013; 68:313-331.
8. Di Lorenzo G, Di Trollo R, Montesarchio V, et al. Pegylated liposomal doxorubicin as second-line therapy in the treatment of patients with advanced classic Kaposi sarcoma: a retrospective study. *Cancer* 2008; 112:1147-1152.

ADDRESS: José Ramón Estela Cubells, MD, Department of Dermatology, Valencia University General Hospital, Avda. Tres Cruces 2, 46014 Valencia, Spain; e-mail: j.estela@hotmail.com

Immunohistochemical staining was positive for human herpesvirus 8 latent nuclear antigen