

## THE CLINICAL PICTURE

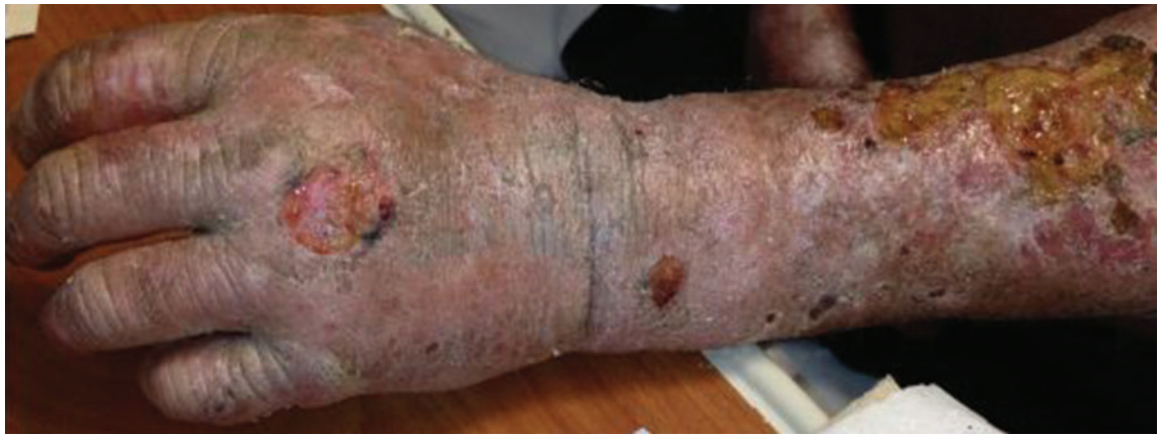**N. MAXWELL RAJAN, MD, MS**

Department of Medicine, Graduate School of Medicine, University of Tennessee at Knoxville

**CAROL L. ELLIS, MD**

Associate Professor, Department of Medicine, Graduate School of Medicine, University of Tennessee at Knoxville

# ‘Allergic to the sun’



**FIGURE 1.** The skin of the left arm and hand is thickened and sclerotic. Atrophic scars are visible on the forearm, particularly on the dorsal aspect. There is patchy hair loss. Small bullae on the left forearm at the time of presentation had resolved by the time this photograph was taken.

**He had burning pain in his arm for 2 to 3 days before he presented to the emergency room**

A 54-YEAR-OLD WHITE MAN presents to the emergency department with burning pain in his left upper arm for the past 2 to 3 days. His medical history includes seizure disorder, for which he takes levetiracetam (Keppra); hypertension, for which he takes metoprolol succinate (Toprol); and in the remote past, a gunshot wound to the head that left his right arm with residual contracture and weakness.

He says he is homeless, has been “allergic to the sun for a while,” and has had dark-colored urine and intermittent abdominal pain. He states that he does not use illicit substances but that he drinks 6 to 12 beers per night and smokes 1 pack of cigarettes per day.

Initial vital signs:

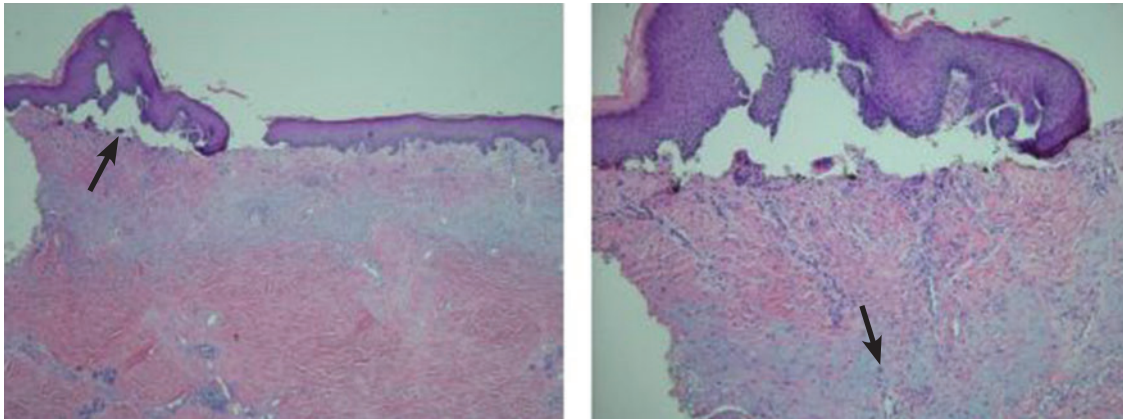
- Temperature 37.7°C (99.9°F)
- Blood pressure 217/114 mm Hg
- Heart rate 82 bpm
- Respiratory rate 18 per minute
- Capillary oxygen saturation 98% while breathing room air.

On examination, his right arm is significantly weak and contracted. His left arm has decreased sensation to pinprick and light touch from elbow to fingers. His face and both arms show hyperpigmentation alternating with atrophic scarring, which also affects his lips. There is no overt mucosal involvement. His hands and forearms have a sclerotic texture and patchy hair loss. Several small bullae are present on the dorsum of the left forearm and hand. There is a 6-inch, irregular, open lesion on the left forearm and a 1-inch lesion on the left hand (**FIGURE 1**).

Initial laboratory studies show:

- Chemistries and complete blood cell count within normal limits
- Platelet count  $305 \times 10^9/L$  (reference range 150–350)
- Orange-colored urine
- Hepatitis C virus (HCV) antibody positive (new finding)
- Human immunodeficiency virus antibody, hepatitis B surface antigen, and antinuclear antibody negative

doi:10.3949/ccjm.81a.13136



**FIGURE 2.** On the left, a punch-biopsy specimen from the patient's right forearm showed a subepidermal vesicle in the upper left corner (arrow) consistent with porphyria cutanea tarda and bullous disorders. On the right, the reticular effacement and significant dermal fibrosis (arrow) were also consistent with porphyria cutanea tarda, as well as with morphea and scleroderma (hematoxylin and eosin,  $\times 10$ ). The specimen on the right is the same as the one on the left, at higher magnification (hematoxylin and eosin,  $\times 20$ ).

- Phenytoin and urine drug screen negative
- Aspartate aminotransferase 70 U/L (reference range 5–34)
- Alanine aminotransferase 73 U/L (reference range 0–55)
- Prothrombin time 10.8 seconds (reference range 8.3–13.0), international normalized ratio 0.98 (reference range 0.8–1.2)
- Iron studies within normal limits.

The patient is admitted to the hospital and is started on cefazolin and clindamycin. Urine is collected for a porphyrin screen, and punch-biopsy samples from the forearms are sent for study. Ultrasonography shows splenomegaly, as well as increased echogenicity of the liver without structural abnormalities. Blood and urine cultures, drawn upon admission, are negative by discharge.

Pathologic study of the punch-biopsy specimens (**FIGURE 2**) shows the formation of subepidermal vesicles with extensive reticular and dermal fibrosis.

#### ■ DIAGNOSIS: PORPHYRIA CUTANEA TARDA

Because of the patient's history, examination, and pathology results, he was preliminarily diagnosed with porphyria cutanea tarda (PCT).<sup>1,2</sup> The diagnosis was confirmed after he was discharged when his urine uroporphyrin level was found to be 157.5  $\mu\text{mol/mol}$  of creatinine (reference range  $< 4$ ) and

his urine heptacarboxylporphyrin level was 118.0  $\mu\text{mol/mol}$  of creatinine (reference range  $< 2$ ).

This patient's clinical presentation is classic for sporadic (ie, type 1) PCT. Sporadic PCT is an acquired deficiency of uroporphyrinogen decarboxylase, an enzyme that catalyzes the fifth step in heme metabolism.<sup>3</sup> The deficiency of this enzyme is exclusively hepatic and is strongly associated with chronic hepatitis C infection. Mutations of the hemochromatosis gene (*HFE*), human immunodeficiency virus infection, alcohol use, and smoking are also risk factors.<sup>4</sup> The prevalence in the United States is about 1:25,000; nearly 80% of cases are sporadic (type 1), and 20% are familial (type 2).<sup>5</sup>

Manifestations of PCT include photosensitive dermatitis, facial hypertrichosis, and orange urine.<sup>3</sup> The photosensitivity dermatitis heals slowly and leads to sclerosis and hyperpigmentation.

Repeated phlebotomy is the first-line treatment, and hydroxychloroquine (Plaquenil) is the second-line treatment.<sup>6</sup> Patients with PCT and hepatitis C should be considered for antiviral therapy according to standard guidelines. Treatment of hepatitis C may reduce the symptoms of PCT, even without a sustained viral response. However, not enough evidence exists to make treatment recommendations for this group.<sup>7</sup>

**Repeated phlebotomy is the first-line treatment, and hydroxychloroquine is the second-line treatment**

Because we were uncertain that the patient would return for follow-up, we did not start phlebotomy or treatment for hepatitis C. However, we did prescribe hydroxychloroquine 100 mg three times a week and instructed him to cover his skin when outside and to use effective

sunblock. An outpatient visit was scheduled prior to discharge. Unfortunately, the patient was lost to follow-up.

**ACKNOWLEDGMENT:** The authors would like to personally thank Dr. Karen DeSouza from the University of Tennessee, Graduate School of Medicine, Department of Pathology, for her clinical expertise and kind advice.

### REFERENCES

1. The University of Iowa, Department of Pathology, Laboratory Services Handbook. Porphyrins & Porphobilinogen, Urine (24 hr or random). [www.healthcare.uiowa.edu/path\\_handbook/handbook/test2893.html](http://www.healthcare.uiowa.edu/path_handbook/handbook/test2893.html). Accessed August 8, 2014.
2. Maynard B, Peters MS. Histologic and immunofluorescence study of cutaneous porphyrias. *J Cutan Pathol* 1992; 19:40–47.
3. Thunell S, Harper P. Porphyrins, porphyrin metabolism, porphyrias. III. Diagnosis, care and monitoring in porphyria cutanea tarda—suggestions for a handling programme. *Scand J Clin Lab Invest* 2000; 60:561–579.
4. Lambrecht RW, Thapar M, Bonkovsky HL. Genetic aspects of porphyria cutanea tarda. *Semin Liver Dis* 2007; 27:99–108.
5. Kushner JP, Barbuto AJ, Lee GR. An inherited enzymatic defect in porphyria cutanea tarda: decreased uroporphyrinogen decarboxylase activity. *J Clin Invest* 1976; 58:1089–1097.
6. Singal AK, Kormos-Hallberg C, Lee C, et al. Low-dose hydroxychloroquine is as effective as phlebotomy in treatment of patients with porphyria cutanea tarda. *Clin Gastroenterol Hepatol* 2012; 10:1402–1409.
7. Ryan Caballes F, Sendi H, Bonkovsky HL. Hepatitis C, porphyria cutanea tarda and liver iron: an update. *Liver Int* 2012; 32:880–893.

**ADDRESS:** Carol L. Ellis, MD, Department of Medicine, Graduate School of Medicine, University of Tennessee at Knoxville, 1926 Alcoa Highway, Box U114, Knoxville, TN 37920; e-mail: [CEllis@mc.utmck.edu](mailto:CEllis@mc.utmck.edu)