

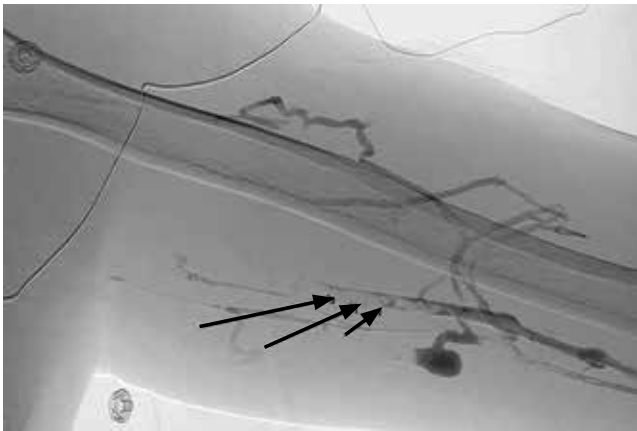
**NIROSSHAN THIRUCHELVAM, MD**  
Department of Pulmonary Medicine,  
Cleveland, Clinic

**FARAYI MBUVAH, MD**  
Department of Anesthesiology,  
Henry Ford Hospital, Detroit, MI

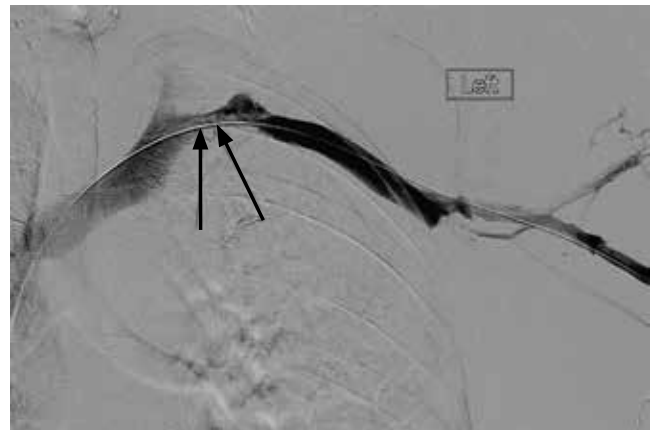**GAURAV KISTANGARI, MD, MPH**  
Department of Hospital Medicine,  
Cleveland Clinic

**ANIL KUMAR REDDY ANUMANDLA, MD**  
Department of Hospital Medicine, Cleveland Clinic

# Upper-limb deep vein thrombosis in Paget-Schroetter syndrome



**FIGURE 1.** Complete occlusion of the subclavian vein and the axillary and brachial veins (arrows).



**FIGURE 2.** After 3 days of thrombolytic therapy, venography showed a 50% residual stenosis of the left subclavian vein.

**A** 43-YEAR-OLD MAN with no medical history presented with pain and swelling in his left arm for 2 weeks. He was a regular weight lifter, and his exercise routine included repetitive hyperextension and hyperabduction of his arms while lifting heavy weights.

He had no history of recent trauma or venous cannulation of the left arm. His family history was negative for thrombophilic disorders. Physical examination revealed a swollen and erythematous left arm and visible venous collaterals at the neck, shoulder, and chest. There was no evidence of arterial insufficiency.

Duplex ultrasonography confirmed thrombosis of the left brachial, axillary, and subclavian veins. Further evaluation with computed tomography showed no intrathoracic mass but revealed several subsegmental pulmonary thrombi in the right lung. A screen for thrombophilia was negative. Venography confirmed complete thrombotic occlusion of the subclavian, axillary, and brachial veins (**Figure 1**).

Catheter-directed thrombolysis with tissue plasminogen activator resulted in complete resolution of

the thrombosis, but venography after 3 days of thrombolysis showed 50% residual stenosis of the left subclavian vein where it passes under the first rib (**Figure 2**). The redness and swelling had markedly improved 2 days after thrombolytic therapy. He was discharged home on rivaroxaban 20 mg daily.

Follow-up venography 2 months later (**Figure 3**), with the patient performing hyperabduction of the arms, showed a patent subclavian vein with no thrombosis, but dynamic compression and occlusion of the subclavian vein where it passes the first rib. Magnetic resonance imaging (MRI) of the neck showed no cervical (ie, extra) rib and no soft-tissue abnormalities of the scalene triangle.

Following this, the patient underwent resection of the left first rib for decompression of the venous thoracic outlet, which resulted in resolution of his symptoms. He remained asymptomatic at 6-month follow-up.

## PAGET-SCHROETTER SYNDROME

Paget-Schroetter syndrome, also referred to as effort-induced or effort thrombosis, is thrombosis of the axillary

or subclavian vein associated with strenuous and repetitive activity of the arms. Anatomic abnormalities at the thoracic outlet—cervical rib, congenital bands, hypertrophy of scalene tendons, abnormal insertion of the costoclavicular ligament—and repetitive trauma to the endothelium of the subclavian vein are key factors in its initiation and progression.

The condition is seen primarily in young people who participate in strenuous activities such as rowing, weight lifting, and baseball pitching. It is estimated to be the cause of 40% of cases of primary upper-extremity deep vein thrombosis in the absence of an obvious risk factor or trigger such as a central venous catheter, pacemaker, port, or occult malignancy.<sup>1</sup>

A provocative test such as the Adson test or hyperabduction test during MRI or venography helps confirm thoracic outlet obstruction by demonstrating dynamic obstruction.<sup>2</sup>

## TREATMENT CONSIDERATIONS

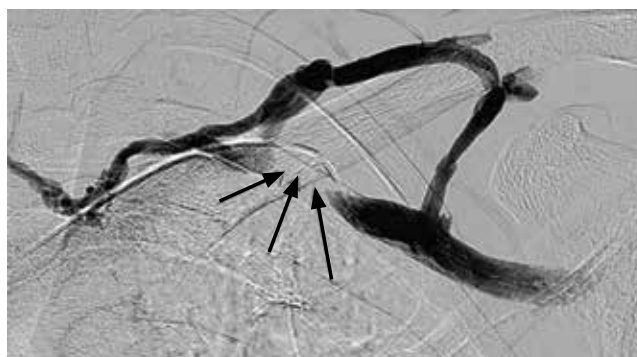
There are no universal guidelines for the treatment of Paget-Schroetter syndrome. However, the available data<sup>3–5</sup> suggest a multimodal approach that involves early catheter-directed thrombolysis and subsequent surgical decompression of the thoracic outlet. This can restore venous patency and reduce the risk of long-term complications such as rethrombosis and postthrombotic syndrome.<sup>3–5</sup>

Surgical treatment includes resection of the first rib and division of the scalene muscles and the costoclavicular ligament. MRI with provocative testing helps guide the surgical approach. Anticoagulation therapy alone—ie, without thrombolysis and surgical decompression—is inadequate as it leads to recurrence of thrombosis and residual symptoms.<sup>6</sup>

Paget-Schroetter syndrome should not be managed the same as lower-extremity deep vein thrombosis because the cause and the exacerbating factors are different.

## Unanswered questions

Because we have no data from randomized controlled trials, questions about management remain. What should be the duration



**FIGURE 3.** After 2 months of thrombolytic therapy, venography with the patient performing hyperabduction of the arms showed dynamic compression of the left subclavian vein with collaterals where they passed under the first rib.

of anticoagulation, especially in the absence of coexisting thrombophilia? Is thrombophilia screening useful? What is the optimal timing for starting thrombolytic therapy?

A careful history and heightened suspicion are required to make this diagnosis. If undiagnosed, it carries a risk of significant long-term morbidity and death. Dynamic obstruction during venography, in addition to MRI, can help identify an anatomic obstruction.

## REFERENCES

1. Bernardi E, Pesavento R, Prandoni P. Upper extremity deep venous thrombosis. *Semin Thromb Hemost* 2006; 32:729–736.
2. Demirbag D, Unlu E, Ozdemir F, et al. The relationship between magnetic resonance imaging findings and postural maneuver and physical examination tests in patients with thoracic outlet syndrome: results of a double-blind, controlled study. *Arch Phys Med Rehabil* 2007; 88:844–851.
3. Alla VM, Natarajan N, Kaushik M, Warriar R, Nair CK. Paget-Schroetter syndrome: review of pathogenesis and treatment of effort thrombosis. *West J Emerg Med* 2010; 11:358–362.
4. Molina JE, Hunter DW, Dietz CA. Paget-Schroetter syndrome treated with thrombolytics and immediate surgery. *J Vasc Surg* 2007; 45:328–334.
5. Thompson RW. Comprehensive management of subclavian vein effort thrombosis. *Semin Intervent Radiol* 2012; 29:44–51.
6. AbuRahma AF, Robinson PA. Effort subclavian vein thrombosis: evolution of management. *J Endovasc Ther* 2000; 7:302–308.

**ADDRESS:** Niroshan Thiruchelvam, MD, Department of Pulmonary Medicine, G91, Cleveland Clinic, 9500 Euclid Avenue, Cleveland, OH 44195; e-mail: thirucn@ccf.org

**Paget-Schroetter syndrome should not be managed the same as lower-extremity deep vein thrombosis**