

THE CLINICAL PICTURE

ANA BRASILEIRO, MD

Department of Dermatology,
Hospital S. António dos Capuchos,
Centro Hospitalar de Lisboa Central,
Lisbon, Portugal

RITA RIBEIRO, MD

Department of Internal Medicine,
Hospital S. António dos Capuchos,
Centro Hospitalar de Lisboa Central,
Lisbon, Portugal

PEDRO EDUARDO SILVA, MD

Department of Internal Medicine, Hospital
S. António dos Capuchos, Centro Hospitalar
de Lisboa Central, Lisbon, Portugal

ANA FIDALGO, MD

Department of Dermatology,
Hospital S. António dos Capuchos,
Centro Hospitalar de Lisboa Central,
Lisbon, Portugal

Stellate ulceration in a nonuremic patient

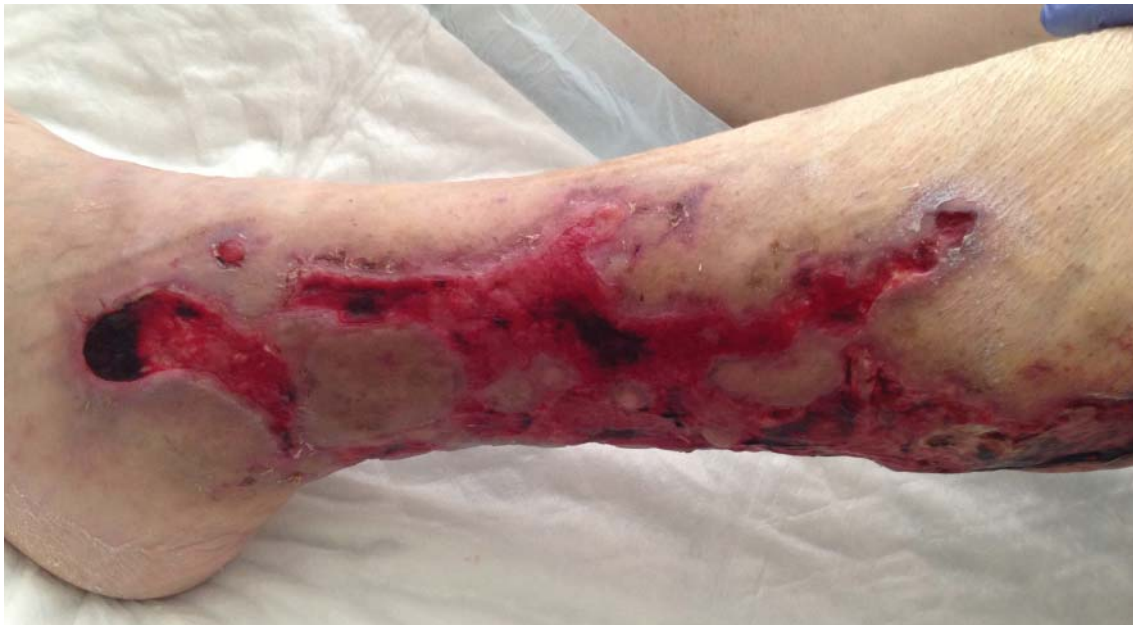

FIGURE 1. The patient's left lower leg had a star-shaped ulceration that included large areas of granulation tissue and necrotic tissue.

A 64-YEAR-OLD MAN WAS admitted for extensive painful ulceration of the left lower leg (**Figure 1**) that occurred after a fall and that had worsened over the last 4 months.

His medical history included hyperuricemia, hypertension, and type 2 diabetes mellitus. He had no known cardiac or renal disease.

Results of initial laboratory testing showed the following:

- Hemoglobin 10.9 g/dL (reference range 13.5–17.5); red blood cells were normocytic and normochromic
- White blood cell count $10.2 \times 10^9/L$ (4.5–11.0)
- Neutrophil count $9.11 \times 10^9/L$ (2.0–8.5)
- C-reactive protein 259 mg/L (< 5)
- Creatinine, urea, sodium, potassium, calcium, and phosphate were within normal limits.

doi:10.3949/ccjm.82a.14176

Doppler ultrasonography of the legs showed mild diffuse atheromatous arterial disease without significant blockage of blood flow, in addition to mild bilateral venous insufficiency.

Cutaneous biopsy showed intravascular calcium deposition in the hypodermis (**Figure 2**) and reticular dermis, erythrocyte extravasation in the superficial dermis, and epidermal necrosis, thus establishing the diagnosis of nonuremic calciphylaxis. The vascular occlusion with spreading necrosis gave the characteristic stellate appearance.

Aside from diabetes, our patient had none of the conditions usually associated with nonuremic calciphylaxis—namely, hyperparathyroidism, previous corticosteroid therapy, warfarin use, connective tissue disease, or malignancy.

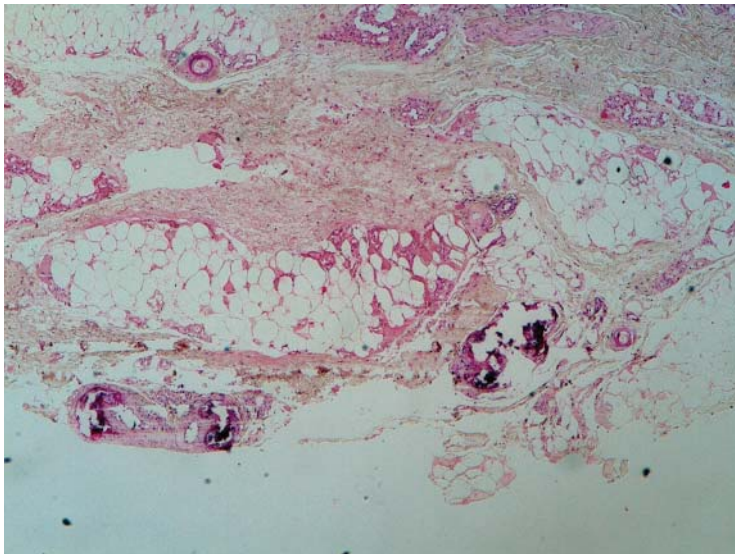


FIGURE 2. Histologic study showed intravascular calcium deposition in the hypodermis (hematoxylin and eosin, × 40).

Cutaneous biopsy showed intravascular calcium deposition in the hypodermis and the reticular dermis

■ **A POORLY UNDERSTOOD SMALL-VESEL VASCULOPATHY**

Calciphylaxis is a poorly understood small-vessel vasculopathy, most often associated with end-stage renal disease, with a prevalence of 1% to 4% in patients on dialysis.¹ It carries a high risk of death, most often from sepsis.

The cause is still unclear, but several conditions have been implicated, including primary hyperparathyroidism, malignancies, alcoholic liver disease, connective tissue disease, and diabetes.²

Making the diagnosis may be challenging, especially in nonuremic patients. It is a rare condition, the presentation is not always typical, and it can occur with fully normal kidney function and normal indicators of calcium and phosphate metabolism.

The differential diagnosis includes:

- Vasculitis, either primary or secondary to an autoimmune disorder such as rheumatoid arthritis, systemic lupus erythematosus, or cryoglobulinemia

- Peripheral vascular disease
- Other inflammatory conditions such as pyoderma gangrenosum and panniculitis
- Infections such as cellulitis and necrotizing fasciitis
- Iatrogenic disorders such as warfarin necrosis and early-stage nephrogenic systemic fibrosis.^{3,4}

The current approach to treatment is multidisciplinary and is based only on case reports and small case series, since no randomized prospective trial has been done. The goal is optimal control of calcium and phosphate homeostasis and correction of hypercoagulability.⁵ Available data^{4,5} support appropriate wound care and surgical debridement.^{4,5} Intravenous sodium thiosulfate is the most widely used medical treatment and can be given regardless of the level of renal function. Resolution rates have been greater than 90% in patients with normal renal function, whereas improvement in cutaneous ulcers and pain has been observed in 70% of hemodialysis patients.⁴ However, it does not reduce the associated mortality rate.⁴

Awareness of nonuremic calciphylaxis and a high index of suspicion are needed when any patient presents with a leg ulcer and no clear cause. It should be considered in the differential diagnosis of leg ulcer in patients with chronic renal failure even if they have risk factors for more common causes of ulcers, and even occasionally in patients such as ours without chronic kidney disease or other risk factors for this condition.

■ **OUR PATIENT'S MANAGEMENT**

The patient developed profuse diarrhea, and infection with *Clostridium difficile* was confirmed. Despite treatment with metronidazole and vancomycin, he died several days later. No treatment directed to calciphylaxis was ever started because of the patient's unstable condition during the entire hospitalization. ■

■ **REFERENCES**

1. Van Hattem S, Bootsma AH, Thio HB. Skin manifestations of diabetes. *Cleve Clin J Med* 2008; 75:772-777.
2. Nigwekar SU, Wolf M, Sterns RH, Hix JK. Calciphylaxis from non-uremic causes: a systematic review. *Clin J Am Soc Nephrol* 2008; 3:1139-1143.
3. Lee JL, Naguwa SM, Cheema G, Gershwin ME. Recognizing calcific uremic arteriopathy in autoimmune disease: An emerging mimicker of vasculitis. *Autoimmun Rev* 2008; 7:638-643.

4. Wollina U. Update on cutaneous calciphylaxis. *Indian J Dermatol* 2013; 58:87-92.
5. Ross EA. Evolution of treatment strategies for calciphylaxis. *Am J Nephrol* 2011; 34:460-467.

ADDRESS: Ana Brasileiro, MD, Department of Dermatology, Hospital S. António dos Capuchos, Centro Hospitalar de Lisboa Central, Alameda Santo António dos Capuchos, 1169-050 Lisbon, Portugal; e-mail: afmbrasileiro@gmail.com