

**YU XIE, MD**

Cardiology Fellow,  
Cedars-Sinai Heart Institute,  
Los Angeles, CA

**ANNA M. McDIVIT, MD**

Assistant Clinical Professor of Medicine,  
University of California San Diego School  
of Medicine, and Sulpizio Cardiovascular  
Center, La Jolla, CA

**LUIS R. CASTELLANOS, MD, MPH**

Associate Clinical Professor of Medicine, University  
of California San Diego School of Medicine, and  
Sulpizio Cardiovascular Center, La Jolla, CA

# A young man with an unusual cause of palpitations

A 23-YEAR-OLD MAN presents to the emergency department with the sudden onset of palpitations, lightheadedness, and dyspnea, accompanied by weakness and nausea, which started earlier in the evening. He estimates that he has experienced 15 similar episodes, lasting minutes to hours, since the age of 16, with the last one 3 years ago. These episodes typically end by themselves or with self-induced vomiting and lying supine. The current episode did not resolve with these maneuvers.

He has never received medical attention for these symptoms. He has no chest pain, orthopnea, paroxysmal nocturnal dyspnea, lower extremity edema, or syncope. He has had no recent illness, contacts with sick people, or travel.

The patient's history includes a "childhood heart murmur," which resolved, and also mild asthma. He is otherwise healthy but has not received regular medical care. He used to play competitive soccer but quit because playing made his symptoms of dyspnea on exertion and palpitations much worse.

He uses marijuana frequently and alcohol occasionally. He does not smoke tobacco or use other recreational drugs. Other than infrequent use of albuterol, he does not take any prescription or over-the-counter medications. He has no allergies. He knows of no family history of arrhythmia or sudden cardiac death.

**Physical examination.** On initial examination, his temperature is 36.4°C (97.5°F), heart rate 230 bpm, systolic blood pressure 60 mm Hg, respiratory rate 30 breaths per minute,

oxygen saturation 100% while breathing room air, and body mass index 25 kg/m<sup>2</sup>.

He is awake, anxious, and appears ill. He speaks only in short sentences. A focused cardiac examination reveals a regular tachycardia with no appreciable murmur or extra heart sounds; the apical impulse is not displaced. His lungs are clear. His abdomen is soft and nontender. He has 2+ pulses on a scale of 0 to 4+, with no peripheral edema.

His initial electrocardiogram (ECG) (Figure 1) shows a heart rate of 260 bpm and a regular wide complex tachycardia, defined as a rate greater than 100 bpm and a QRS complex wider than 0.12 seconds.

## ■ FOCUS ON REGULAR WIDE COMPLEX TACHYCARDIA

1 Which of the following is *not* in the differential diagnosis of regular wide complex tachycardia?

- Monomorphic ventricular tachycardia
- Orthodromic atrioventricular reentrant tachycardia
- Antidromic atrioventricular reentrant tachycardia
- Sinus tachycardia with bundle branch block

Orthodromic atrioventricular reentrant tachycardia is not in the differential diagnosis.

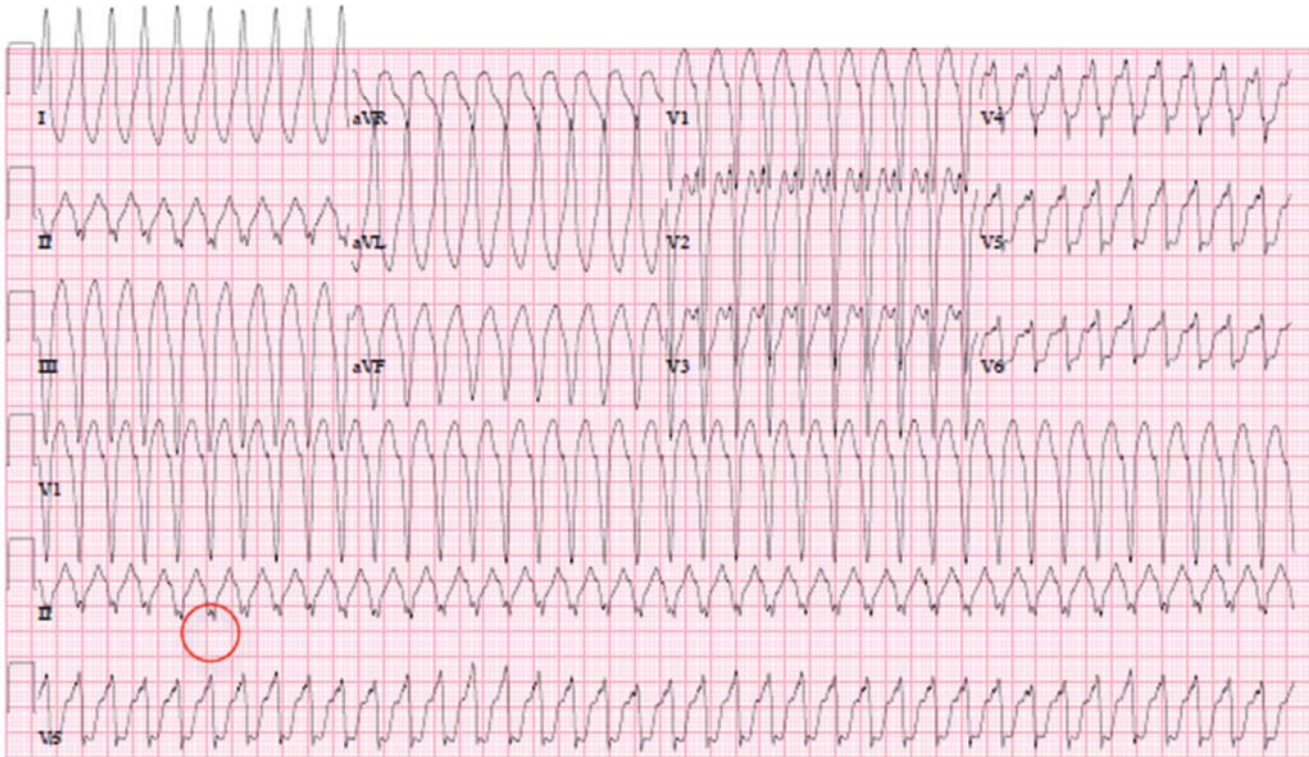
Wide complex tachycardia can occur when the impulse originates outside the normal conduction system or when there is abnormal ventricular activation through the atrioventricular (AV) node and His-Purkinje system.

The main distinction to make when diagnosing the cause of a wide complex tachycar-

He has had about 15 such episodes since age 16

doi:10.3949/ccjm.82a.14171

## The patient's initial electrocardiogram



**FIGURE 1.** The patient's electrocardiogram on presentation demonstrates regular wide complex tachycardia with a heart rate of 260 bpm. Note the "buried" retrograde P waves, best seen in the continuous strip of lead II (circle). This is consistent with supraventricular tachycardia with aberrancy, where the atrial impulse is conducted down an accessory pathway, resulting in a regular wide complex QRS.

dia is between the following:

**Monomorphic ventricular tachycardia**, which originates from a single ventricular focus that depolarizes the adjacent myocardium in a stepwise fashion, causing a wide QRS complex that does not begin in the native conduction system, and

**Sinus tachycardia with bundle branch block**, ie, supraventricular tachycardia with aberrant conduction within the normal conduction system.

Three different conduction patterns are seen with atrioventricular reentrant tachycardia (Figure 2):

**Sinus depolarization (Figure 2a)**, in which the atrial impulse travels down the AV node, and the accessory pathway can be hidden and not contribute to the surface ECG.

**Orthodromic atrioventricular reentrant tachycardia (Figure 2b)**, in which the depolarizing impulse travels antegrade down the

AV node, then propagates from the ventricle back to the atria via the accessory pathway, resulting in a narrow QRS.

**Antidromic atrioventricular reentrant tachycardia (Figure 2c)**, in which the depolarization travels antegrade down the accessory pathway then propagates from the ventricle back to the atria via the AV node, resulting in a wide complex QRS with a delta wave.

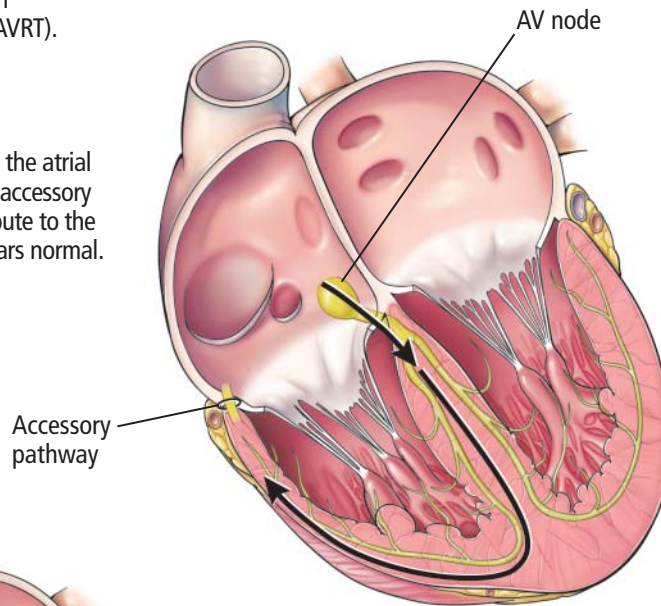
Important features of the patient's electrocardiogram (Figure 1) are consistent with antidromic atrioventricular reentrant tachycardia:

- "Buried" retrograde P waves, which are best seen in the continuous strip of lead II as a positive deflection notching in the negative nadir of the wave
- The PR segment is short, suggesting retrograde atrial depolarization
- The P wave is followed by a slow slurred upstroke (delta wave), best seen in lead I.

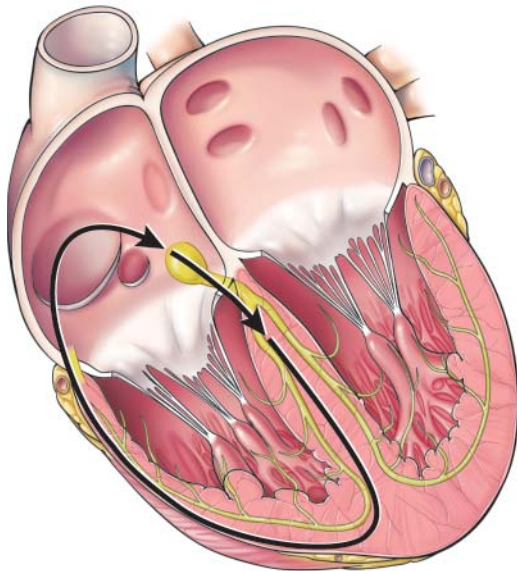
**Electrical conduction in atrioventricular reentrant tachycardia**

Three conduction patterns are seen with atrioventricular reentrant tachycardia (AVRT).

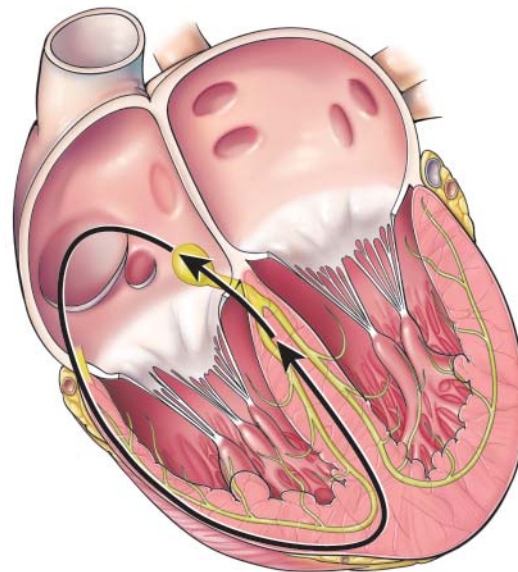
**During sinus depolarization**, the atrial impulse travels down the AV node; the accessory pathway can be hidden and not contribute to the surface electrocardiogram, which appears normal.



**During antidromic AVRT**, the depolarization travels antegrade down the accessory pathway, then propagates from the ventricle back to the atrium via the AV node, resulting in a wide complex QRS with a delta wave.

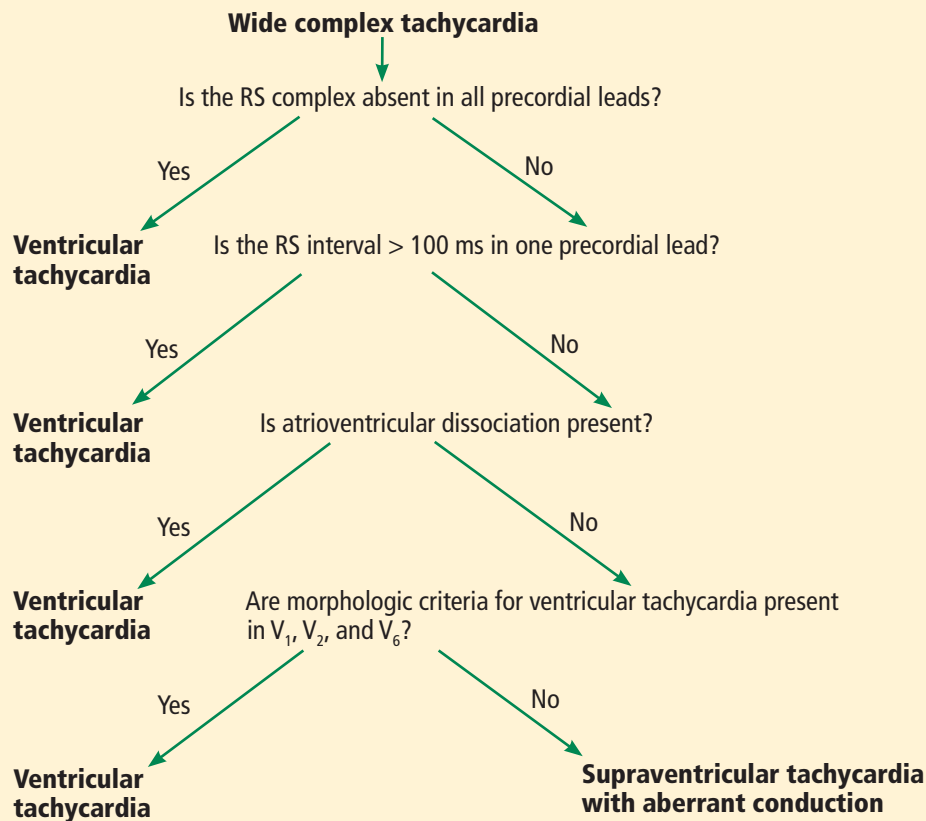


**During orthodromic AVRT**, the depolarizing pulse travels antegrade down the AV node and then propagates from the ventricle back to the atrium via the accessory pathway, resulting in a narrow QRS.



**FIGURE 2.**

### Distinguishing ventricular tachycardia from supraventricular tachycardia using the Brugada criteria



**FIGURE 3**

Adapted from Brugada P, Brugada J, Mont L, Smeets J, Andries EW. A new approach to the differential diagnosis of a regular tachycardia with a wide QRS complex. *Circulation* 1991; 83:1649–1659, with permission from Lippincott Williams & Wilkins.

**Hemodynamically unstable patients with tachyarrhythmias need immediate cardioversion**

#### Treatment depends on diagnosis

Distinguishing supraventricular tachycardia from ventricular tachycardia is important, as the treatments differ. Supraventricular tachycardia is treated with adenosine, calcium channel blockers, and beta-blockers, which are not only ineffective for ventricular tachycardia, but rarely may precipitate hemodynamic deterioration.

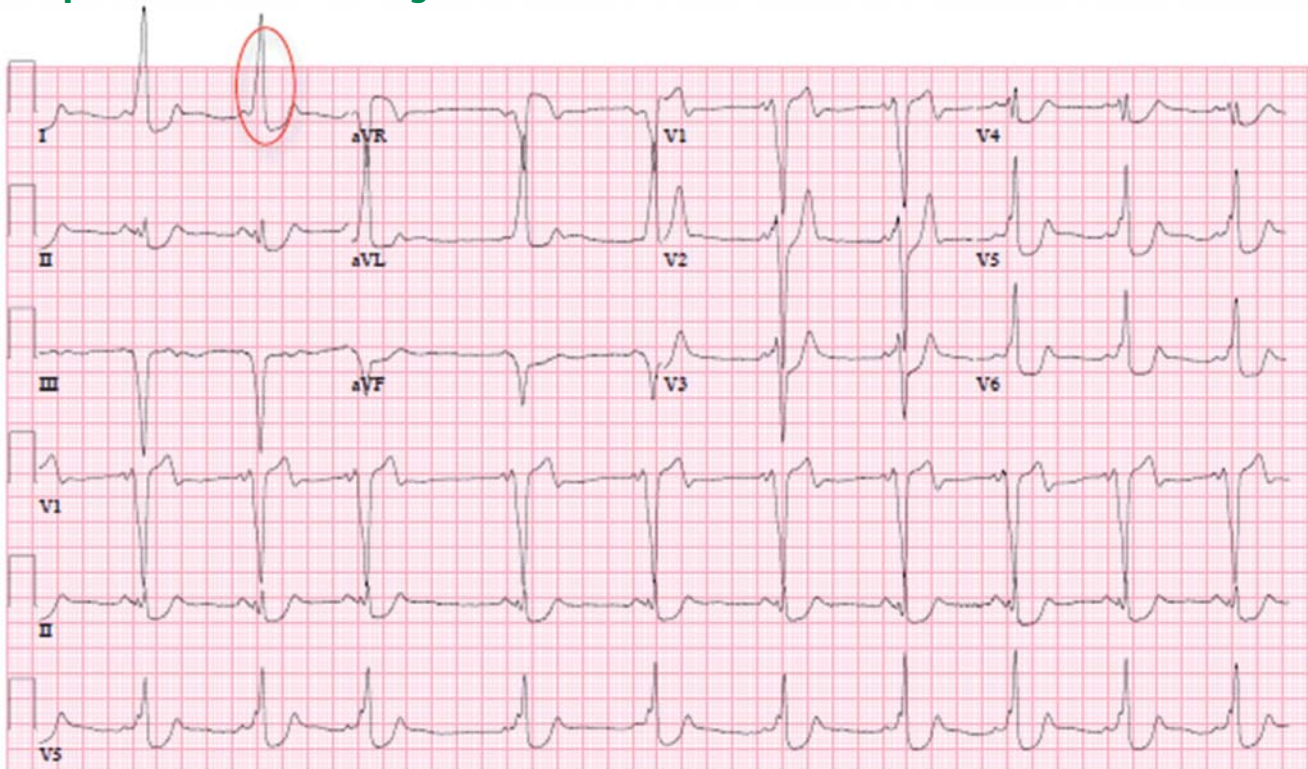
Also important is distinguishing pre-excitation atrial fibrillation from other types of supraventricular tachycardia with aberrancy, because the nodal blockade used to treat other causes of the condition may worsen the tachycardia via the accessory pathway. If pre-excitation atrial fibrillation is suspected on the basis of an irregular wide complex tachycardia with delta waves on ECG, then procainamide—a

sodium channel blocker that affects the cardiac action potential and prolongs the refractory period of the accessory pathway—can be used to help control the arrhythmia.<sup>1</sup>

#### Brugada criteria aid diagnosis

In 1991, Brugada et al<sup>2</sup> devised an algorithm to differentiate ventricular tachycardia from supraventricular tachycardia with aberrancy in the setting of regular wide complex tachycardia (**Figure 3**). It has a sensitivity of 98.7% and a specificity of 96.5% for diagnosing ventricular tachycardia and 96.5% sensitivity and 98.7% specificity for diagnosing supraventricular tachycardia with aberrant conduction. Using the algorithm, only 11 (ie, 2%) of the 544 tachycardias in their study were misclassified.<sup>2–4</sup>

## The patient's electrocardiogram after cardioversion



**FIGURE 4.** The patient's electrocardiogram after cardioversion demonstrates positive delta waves (seen in I [circled], aVL, V<sub>5</sub>, and V<sub>6</sub>) and negative delta waves (seen in aVR, III, aVF, and V<sub>1</sub>). This tracing is consistent with sinus rhythm with pre-excitation due to type B Wolff-Parkinson-White syndrome.

The Brugada algorithm consists of four criteria, with the presence of any leading to a diagnosis of ventricular tachycardia:

- Absence of an RS complex in all precordial leads (the QRS complexes in precordial leads have all negative or all positive deflections).
- An RS interval in at least one precordial lead of at least 100 ms (the interval is measured from the onset of R to the nadir of the S wave).
- AV dissociation, as determined by the existence of P waves marching out independent of the QRS complexes, capture beats (narrow QRS complexes resulting from the rare occasion when an intrinsic P wave conducts down the native pathway), or fusion beats (combined capture beat and ventricular beat, resulting in a different morphology than most of the wide QRS complexes present).
- Leads V<sub>1</sub>, V<sub>2</sub>, and V<sub>6</sub> satisfying the classic

morphologic criteria for ventricular tachycardia.

If none of these criteria are met, supraventricular tachycardia is diagnosed.

In our patient, we can further confirm the diagnosis of antidromic atrioventricular reentrant tachycardia by using Brugada criteria to exclude ventricular tachycardia (**Figure 3**): the ECG (**Figure 1**) shows an RS complex in multiple precordial leads, the maximum RS interval is less than 100 ms in the precordial leads, there is no evidence of AV dissociation (lead II in the continuous strip shows buried P waves associated with QRS), and morphologic criteria are not met for ventricular tachycardia in leads V<sub>1</sub>, V<sub>2</sub>, and V<sub>6</sub>.

### ■ IS CARDIOVERSION NEEDED?

According to the American Heart Association guidelines for advanced cardiopulmonary life support, patients with tachyarrhythmias who are hemodynamically unstable should

undergo cardioversion immediately.<sup>5</sup>

Our patient, who has a heart rate faster than 200 bpm and a systolic blood pressure of only 60 mm Hg, undergoes synchronized cardioversion in the emergency department. Immediately afterward, his ECG (Figure 4) demonstrates sinus rhythm with pre-excitation consistent with type B Wolff-Parkinson-White syndrome.

Once he is hemodynamically stable, a more thorough physical examination is performed. Examination of the head, ears, eyes, nose, and throat is unremarkable. He has no jugular venous distention or carotid bruits. His lungs are clear to auscultation bilaterally, without wheezes. His cardiac examination shows a regular rate and rhythm, normal first and second heart sounds, and no murmurs, rubs, or gallops.

#### ■ WHICH DIAGNOSTIC STUDIES ARE NEEDED?

##### Laboratory tests

In an otherwise healthy young patient presenting with an arrhythmia, the initial laboratory workup should focus on a precipitating illness or a disease state that may incite an arrhythmia.

Our patient is evaluated for infection or septic shock (white blood cell count with differential), anemia (hemoglobin), thyrotoxicosis (thyroid-stimulating hormone and free thyroxine levels), drug abuse (urine toxicology screen), and cardiac syndromes including structural heart disease and myocardial injury (cardiac enzymes and B-type natriuretic peptide).<sup>6</sup>

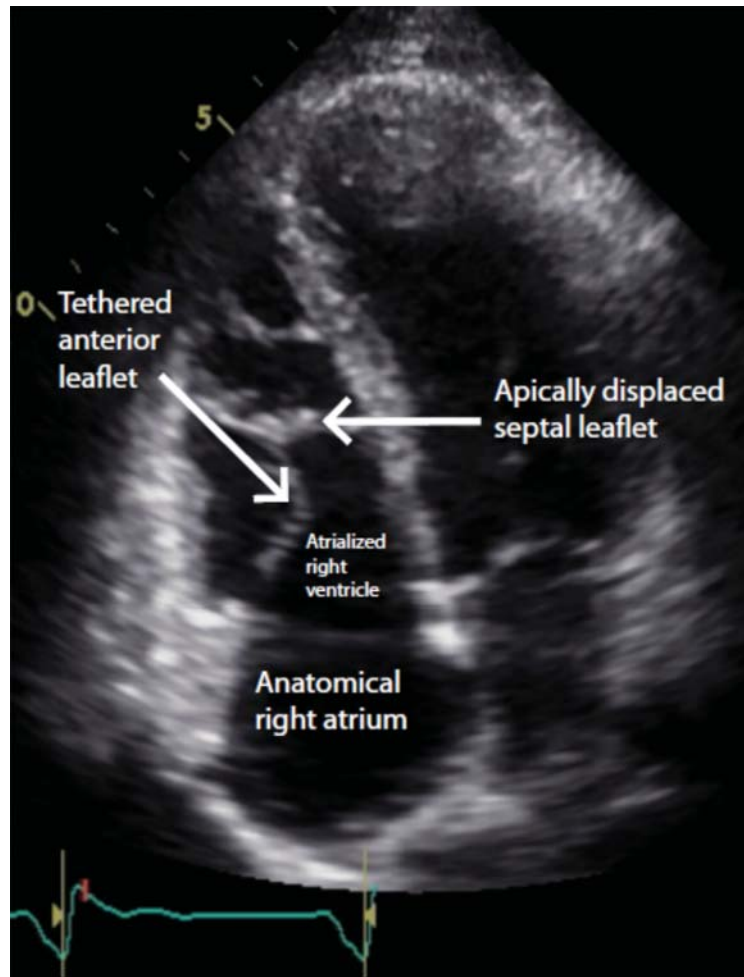
His initial laboratory tests show normal electrolyte levels and renal function, leukocytosis with a white blood cell count of  $15.6 \times 10^9/L$  (normal 4.0–10.0), mildly elevated thyroid-stimulating hormone, and a negative urine toxicology screen.

##### Transthoracic echocardiography

For a young patient presenting with pre-excitation on ECG and hemodynamic instability, transthoracic echocardiography to evaluate chamber size and look for structural abnormalities is a reasonable option.

Our patient undergoes transthoracic echocardiography, which demonstrates normal

#### The patient's echocardiogram demonstrating Ebstein anomaly



**FIGURE 5.** A transthoracic echocardiogram apical four-chamber view demonstrates apical displacement of the septal leaflet from the tricuspid valve annulus, consistent with Ebstein anomaly. There is also atrialization of the right ventricle.

left ventricular size and function with a left ventricular ejection fraction of 69%, moderate right atrial enlargement, and mild right ventricular enlargement (Figure 5). The septal leaflet of the tricuspid valve is apically displaced, and there is mild regurgitation.

#### ■ DIAGNOSIS: EBSTEIN ANOMALY

These findings are consistent with Ebstein anomaly. It can be recognized on transthoracic echocardiography as adherence of the septal and posterior tricuspid valve leaflets

to the myocardium due to failure of the tissue to detach during embryogenesis, apical displacement of the annulus, right atrial enlargement, and right ventricular enlargement.<sup>7-10</sup> Apical displacement of the tricuspid valve is a hallmark finding and must be more than 20 mm or 8 mm/m<sup>2</sup> of body surface area to make the diagnosis.<sup>11-13</sup> ECG often demonstrates right atrial enlargement, first-degree atrial ventricular block, and right bundle branch block.

Ebstein anomaly is a rare embryonic developmental abnormality of the tricuspid valve. It occurs in 1 to 5 of 200,000 live births, accounting for approximately 0.5% of all congenital heart disease.<sup>14,15</sup> Most cases are sporadic and result from failure of the ventricle to delaminate during embryogenesis of the tricuspid valve, resulting in apical displacement of either the septal, posterior, or, very rarely, anterior leaflet of the tricuspid valve.<sup>7,8</sup> The prevalence is higher in infants whose mothers took lithium during early pregnancy.<sup>16</sup>

**2** Which of the following is *not* a common finding associated with Ebstein anomaly?

- Apical displacement of the septal leaflet of the tricuspid valve
- Wolff-Parkinson-White syndrome
- Accessory bypass tract
- Tachyarrhythmias
- Increased risk of sudden death
- Left-sided heart failure

The answer is left-sided heart failure. Ebstein anomaly is associated with increased risk of tachyarrhythmias, right-sided heart failure, and sudden death.<sup>7,8,17,18</sup> In Ebstein anomaly, the tricuspid valve forms closer to the apex, so the part of the right ventricle that is superior to the displaced tricuspid valve functions as the right atrium, thus the term “atrialized” right ventricle. These abnormalities create an environment for accessory pathways, most commonly type B Wolff-Parkinson-White syndrome.<sup>19</sup> Biventricular dysfunction can occur in rare severe cases.<sup>7,8,18</sup>

Our patient is found to have an accessory tract-mediated antidromic atrioventricular reentrant tachycardia in the setting of Wolff-Parkinson-White syndrome and Ebstein

anomaly. This is further confirmed with an electrophysiology study demonstrating a right posterior accessory pathway.

**TREATMENT FOR EBSTEIN ANOMALY**

**3** Which treatment is advised for Ebstein anomaly?

- Observation alone
- Standard heart failure medications
- Radiofrequency catheter ablation
- Tricuspid valve repair or replacement
- Biventricular reconstruction
- Heart transplant

The answer is all of the above. Observation alone is advised for patients with mild symptoms, no evidence of right-to-left shunting, and only mild cardiomegaly. Medical management includes an angiotensin-converting enzyme inhibitor or angiotensin receptor blocker, a beta-blocker, and diuretics. Radiofrequency catheter ablation is the first-line therapy for patients with symptomatic Wolff-Parkinson-White syndrome.<sup>20</sup> A patient who develops worsening right-sided heart failure, cyanosis, paradoxical emboli, or frequent tachyarrhythmias should be considered for corrective surgery, which may include tricuspid valve repair or replacement, or biventricular reconstruction.<sup>7,8,21</sup> Cardiac transplant is reserved for severe cases.<sup>8</sup>

On hospital day 4, our patient undergoes successful radiofrequency catheter ablation without complications. At follow-up 3 months later, he continues to do well, with resolution of his symptoms and no further evidence of pre-excitation. His postprocedure ECG no longer shows delta waves.

**TAKE-HOME POINTS**

- For a patient with regular wide complex tachycardia, the first step is to assess hemodynamic stability. If the patient is hemodynamically unstable, emergent cardioversion is indicated.
- The differential diagnosis for regular wide complex tachycardia includes supraventricular tachycardia with aberrancy (orthodromic atrioventricular reentrant tachycardia), antidromic atrioventricular reentrant

tachycardia, atrial tachycardia), and ventricular tachycardia.

- When pre-excited atrial fibrillation is suspected, AV nodal blocking agents should be avoided, as they may worsen tachyarrhythmia. Sodium channel blockers such as procainamide can help slow down the conduction of the accessory pathway.
- Ebstein anomaly is diagnosed on transthoracic echocardiography as apical displacement of the tricuspid valve resulting in atrialization of the right ventricle.

- Patients with Ebstein anomaly have a higher risk of death from right-sided heart failure and tachyarrhythmias, most commonly type B Wolff-Parkinson-White syndrome.
- Ebstein anomaly is medically managed with standard heart failure medications, including neurohormonal blockade therapies.
- Patients with Ebstein anomaly and cyanosis require surgical intervention with either valve repair or replacement. ■

**ACKNOWLEDGMENT:** We thank Dr. William Collins for his contribution in reviewing the manuscript and his technical expertise in developing some of the figures.

## REFERENCES

1. January CT, Wann L, Alpert JS, et al; ACC/AHA Task Force Members. 2014 AHA/ACC/HRS Guideline for the Management of Patients With Atrial Fibrillation: Executive Summary: A Report of the American College of Cardiology/American Heart Association Task Force on Practice Guidelines and the Heart Rhythm Society. *Circulation* 2014; 130:2071–2104.
2. Brugada P, Brugada J, Mont L, Smeets J, Andries EW. A new approach to the differential diagnosis of a regular tachycardia with a wide QRS complex. *Circulation* 1991; 83:1649–1659.
3. Alzand BS, Crijns HJ. Diagnostic criteria of broad QRS complex tachycardia: decades of evolution. *Europace* 2011; 13:465–472.
4. Wellens HJ, Bar FW, Lie KI. The value of the electrocardiogram in the differential diagnosis of a tachycardia with a widened QRS complex. *Am J Med* 1978; 64:27–33.
5. Field JM, Hazinski MF, Sayre MR, et al. Part 1: executive summary: 2010 American Heart Association Guidelines for Cardiopulmonary Resuscitation and Emergency Cardiovascular Care. *Circulation* 2010; 122(suppl 3):S640–S656.
6. Walkey AJ, Wiener RS, Ghobrial JM, Curtis LH, Benjamin EJ. Incident stroke and mortality associated with new-onset atrial fibrillation in patients hospitalized with severe sepsis. *JAMA* 2011; 306:2248–2254.
7. Attenhofer Jost CH, Connolly HM, Edwards WD, Hayes D, Warnes CA, Danielson GK. Ebstein's anomaly - review of a multifaceted congenital cardiac condition. *Swiss Med Wkly* 2005; 135:269–281.
8. Attenhofer Jost CH, Connolly HM, Dearani JA, Edwards WD, Danielson GK. Ebstein's anomaly. *Circulation* 2007; 115:277–285.
9. Oechslin E, Buchholz S, Jenni R. Ebstein's anomaly in adults: Doppler-echocardiographic evaluation. *Thorac Cardiovasc Surg* 2000; 48:209–213.
10. Ali SK, Nimeri NA. Clinical and echocardiographic features of Ebstein's malformation in Sudanese patients. *Cardiol Young* 2006; 16:147–151.
11. Edwards WD. Embryology and pathologic features of Ebstein's anomaly. *Prog Pediatr Cardiol* 1993; 2:5–15.
12. Shiina A, Seward JB, Edwards WD, Hagler DJ, Tajik AJ. Two dimensional echocardiographic spectrum of Ebstein's anomaly: detailed anatomic assessment. *J Am Coll Cardiol* 1984; 3:356–370.
13. Gussenhoven EJ, Stewart PA, Becker AE, Essed CE, Ligtoet KM, De Villeneuve VH. "Offsetting" of the septal tricuspid leaflet in normal hearts and in hearts with Ebstein's anomaly. Anatomic and echographic correlation. *Am J Cardiol* 1984; 54:172–176.
14. Brickner ME, Hillis LD, Lange RA. Congenital heart disease in adults. Second of two parts. *N Engl J Med* 2000; 342:334–342.
15. Report of the New England Regional Infant Cardiac Program. *Pediatrics* 1980; 65:375–461.
16. Cohen LS, Friedman JM, Jefferson JW, Johnson EM, Weiner ML. A reevaluation of risk of in utero exposure to lithium. *JAMA* 1994; 271:146–150.
17. Paranon S, Acar P. Ebstein's anomaly of the tricuspid valve: from fetus to adult: congenital heart disease. *Heart* 2008; 94:237–243.
18. Watson H. Natural history of Ebstein's anomaly of tricuspid valve in childhood and adolescence. An international co-operative study of 505 cases. *Br Heart J* 1974; 36:417–427.
19. Delhaas T, Sarvaas GJ, Rijlaarsdam ME, et al. A multicenter, long-term study on arrhythmias in children with Ebstein anomaly. *Pediatr Cardiol* 2010; 31:229–223.
20. Tischenko A, Fox DJ, Yee R, et al. When should we recommend catheter ablation for patients with the Wolff-Parkinson-White syndrome? *Curr Opin Cardiol* 2008; 23:32–37.
21. Misaki T, Watanabe G, Iwa T, et al. Surgical treatment of patients with Wolff-Parkinson-White syndrome and associated Ebstein's anomaly. *J Thorac Cardiovasc Surg* 1995; 110:1702–1707.

**ADDRESS:** Luis R. Castellanos, MD, MPH, UCSD Sulpizio Cardiovascular Center, East Campus Office Building, 9444 Medical Center Drive, 3rd Floor, La Jolla, CA 92037; e-mail: lrcastellanos@ucsd.edu