

## THE CLINICAL PICTURE

**FATIMA ADHI, MD**

Department of Internal Medicine,  
Cleveland Clinic, Cleveland, OH

**GURSHAWN SINGH, MD**

Department of Internal Medicine,  
Cleveland Clinic, Cleveland, OH

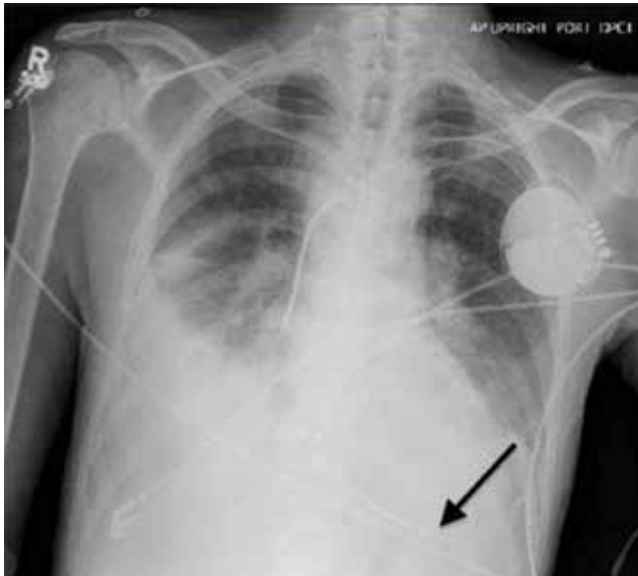
**WAYNE TSUANG, MD**

Departments of Pulmonary and Critical Care  
Medicine, Respiratory Institute, Cleveland Clinic;  
Assistant Professor of Medicine, Cleveland  
Clinic Lerner College of Medicine of Case  
Western Reserve University, Cleveland, OH

**EDUARDO MIRELES-CABODEVILA, MD**

Program Director, Critical Care Medicine, Departments of  
Pulmonary and Critical Care Medicine, Respiratory  
Institute, Cleveland Clinic; Assistant Professor of Medicine,  
Cleveland Clinic Lerner College of Medicine of Case  
Western Reserve University, Cleveland, OH

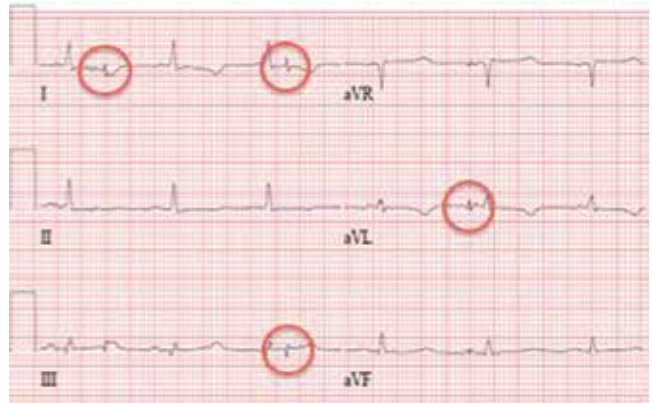# Syncope from a twiddled ICD



**FIGURE 1.** A chest radiograph taken at the time of the original implantation shows the appropriate placement of the generator and the lead (arrow).

**A** 61-YEAR-OLD MAN with ischemic cardiomyopathy underwent implantation of a cardioverter-defibrillator (ICD) in a left subpectoral pocket. Placement was confirmed with chest radiography (FIGURE 1). Six weeks later, he presented to the emergency department reporting two episodes of syncope within the previous 24 hours.

Electrocardiography at the time of presentation showed a normal sinus rhythm with inappropriate ICD discharges (FIGURE 2). This finding prompted chest radiography, which showed that the ICD had rotated 90 degrees from its original position, and that the lead had completely wrapped around the generator and thus was no longer correctly positioned (FIGURE 3). The patient admitted to frequently rubbing (ie, twiddling) the area, which led to twisting and dislocation of the device, a complication known as twiddler syndrome.

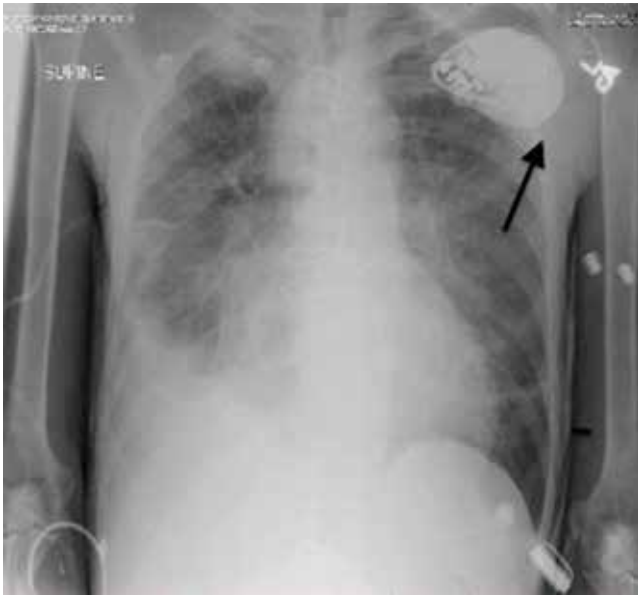

**FIGURE 2.** Electrocardiography 6 weeks after the device was placed showed normal sinus rhythm, but with inappropriate device discharges (circles).

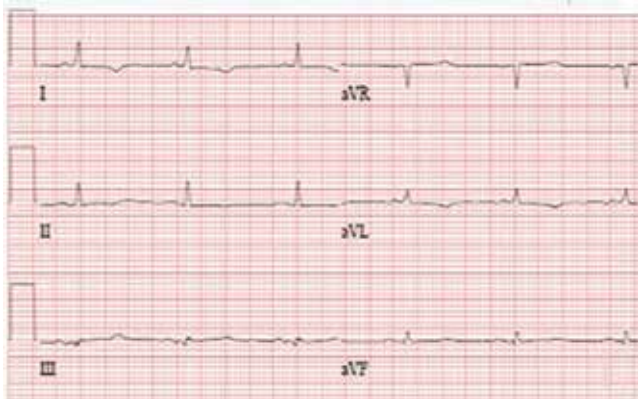Twiddler syndrome is a rare complication of ICD placement, occurring in only about 0.1% of cases.<sup>1</sup> It is usually a result of intentional manipulation (ie, twiddling) of the device by the patient, causing the ICD and the leads to dislodge, break, or retract. It is seen more often in women and in patients with cognitive dysfunction or psychiatric illness, in obese patients, and in patients with laxity of subcutaneous tissues, such as elderly people or people with accelerated weight loss. Placement of the ICD in an inappropriately large pocket predisposes to device rotation.<sup>2,3</sup>

Twiddler syndrome may cause mild discomfort or may even go unnoticed by the patient.<sup>4</sup> In rare cases, it may lead to stimulation of the phrenic nerve, causing diaphragmatic pacing, or to stimulation of the brachial plexus, causing muscle twitching.<sup>2,3</sup> However, malfunction of an ICD is life-threatening and requires immediate repair and replacement of the device. Educating the patient about the risks of twiddling the device site and the importance of periodic device checks is imperative to prevent this syndrome and ensure its early identification if it should occur. The patient should understand that dislodging the ICD can make it unable to sense abnormal rhythms and cause the device to deliver inappropriate shocks<sup>2,3,5</sup> or stop delivering shocks altogether.

doi:10.3949/ccjm.82a.14095



**FIGURE 3.** Chest radiography showed that the generator had rotated 90 degrees and the lead had completely wrapped around the generator (arrow).



**FIGURE 4.** After reimplantation of the cardioverter-defibrillator, the electrocardiogram was normal.

### ■ HOW IT IS TREATED

Treatment involves replacing the leads and affixing the device with sutures in the existing pocket or in a new pocket. The subpectoral position is preferred as it is more secure,<sup>3</sup> although subcutaneous reimplantation has been successful.<sup>1</sup> The device may also be placed in a fabric pouch to help lower the risk of migration or manipulation.<sup>3,6</sup>

In this case, because of the patient's slender body habitus (body mass index 13 kg/m<sup>2</sup>), the ICD was removed from the subpectoral pocket and a new ICD was sutured into a subcutaneous pocket. The single lead was secured to the sternum and fascia using nonabsorbable sutures and a tie-down sleeve, making the device less susceptible to dislodgement by twiddling. Electrocardiography after replacement showed a normal sinus rhythm (FIGURE 4).

### ■ REFERENCES

1. **Constandse J, Smit JJ, Ramdat Misier AR, Elvan A, Delnoy PP.** Unusual twiddler syndrome: movement ties the knot. *Neth Heart J* 2013; 21:253–254.
2. **Spencer S, Poppelbaum A, Müller D.** An unusual cause of oversensing leading to inappropriate ICD discharges. *Int J Cardiol* 2008; 129:e24–e26.
3. **Benezet-Mazuecos J, Benezet J, Ortega-Carnicer J.** Pacemaker twiddler syndrome. *Eur Heart J* 2007; 28:2000.
4. **Chemello D, Subramanian A, Cameron D.** Twiddler syndrome with 180 degrees rotation of an implantable cardioverter defibrillator generator resulting in malfunction of one of the shocking coils. *Europace* 2009; 11:1259.
5. **Garweg C, Alzand BS, Willems R.** Twiddler syndrome causing an inappropriate implantable cardioverter-defibrillator shock. *Eur Heart J* 2014; 35:516.
6. **Parsonnet V, Bernstein AD, Neglia D, Omar A.** The usefulness of a stretch-polyester pouch to encase implanted pacemakers and defibrillators. *Pacing Clin Electrophysiol* 1994; 17:2274–2278.

**ADDRESS:** Eduardo Mireles-Cabodevila, MD, Department of Pulmonary and Critical Care Medicine, A90, Cleveland Clinic, 9500 Euclid Avenue, Cleveland, OH 44195; e-mail: mirelee@ccf.org