

THE CLINICAL PICTURE

PRASHANT SHARMA, MD

Department of Hospital Internal Medicine,
Mayo Clinic, Rochester, MN

VJAIGANESH NAGARAJAN, MD, MRCP

Department of Cardiovascular Medicine, University of
Virginia, Charlottesville

DONALD A. UNDERWOOD, MD

Department of Cardiovascular Medicine,
Cleveland Clinic

Heart on the right may sometimes be ‘right’

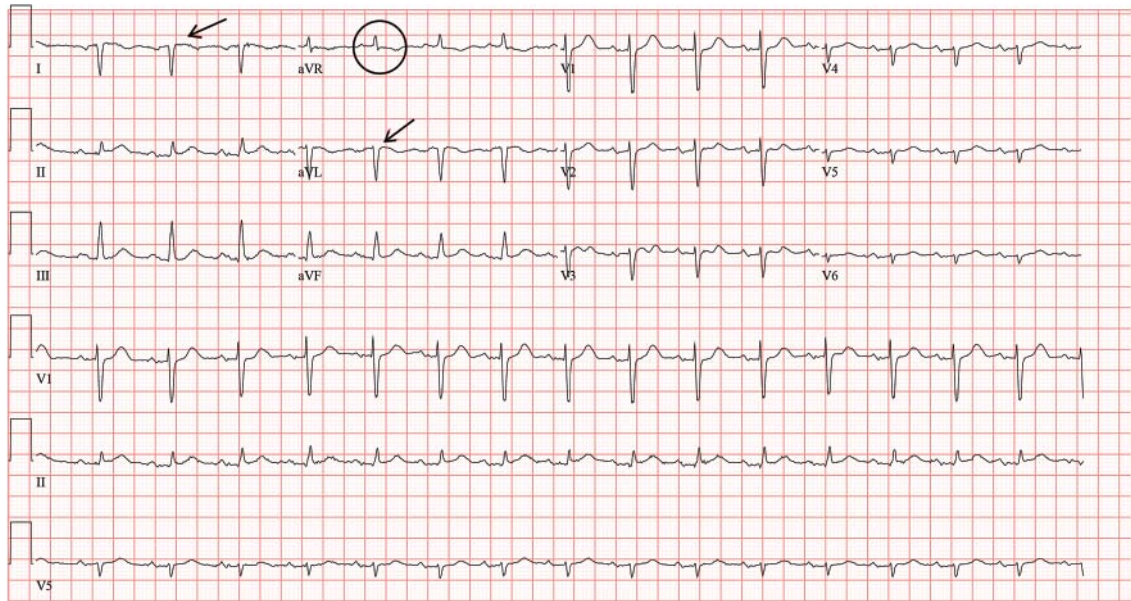


FIGURE 1. The standard left-sided 12-lead electrocardiogram showed right-axis deviation; inverted P, QRS, and T waves in leads I and aVL (arrows), and positive complexes in lead aVR (circle). Leads V₁–V₆ showed reversal of R-wave progression.

Negative complexes in lead I, positive complexes in aVR, and slight reversal of R-wave progression indicate dextrocardia

A 76-YEAR-OLD MAN presented to the emergency department with right-sided exertional chest pain radiating to the right shoulder and arm associated with shortness of breath. His vital signs were normal. On clinical examination, the cardiac apex was palpated on the right side, 9 cm from the midsternal line in the fifth intercostal space.

A standard left-sided 12-lead electrocardiogram (ECG) showed right-axis deviation and inverted P, QRS, and T waves in leads I and aVL (FIGURE 1). Although these changes are also seen when the right and left arm electrode wires are transposed, the precordial lead morphology in such a situation would usually be normal. In our patient, the precordial leads showed the absence or even slight reversal of R-wave progression, a feature indicative of dextrocardia.^{1,2}

doi:10.3949/ccjm.81a.13163

In patients with dextrocardia, right-sided hookup of the electrodes is usually necessary for proper interpretation of the ECG. When this was done in our patient, the ECG showed a normal cardiac axis, a negative QRS complex in lead aVR, a positive P wave and other complexes in lead I, and normal R-wave progression in the precordial leads—findings suggestive of dextrocardia (FIGURE 2).

Chest radiography showed a right-sided cardiac silhouette (FIGURE 3), and computed tomography of the abdomen (FIGURE 4) revealed the liver positioned on the left side and the spleen on the right, confirming the diagnosis of situs inversus totalis. The ECG showed dextrocardia, but no other abnormalities. The patient eventually underwent coronary angiography, which showed nonobstructive coronary artery disease.

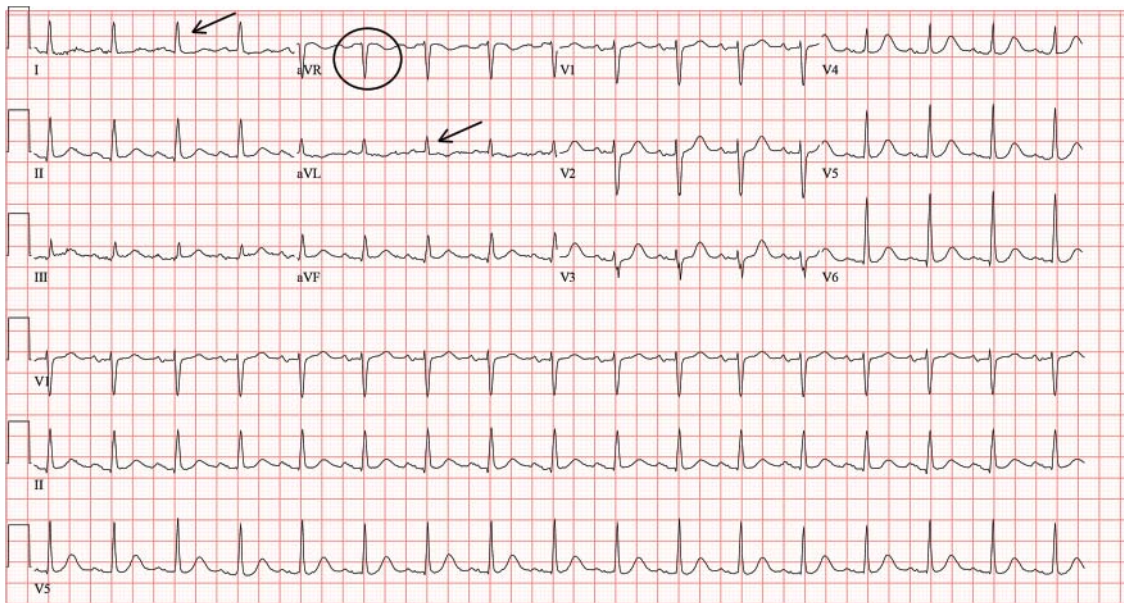


FIGURE 2. With right-sided hookup in the same patient, the electrocardiogram showed a normal QRS axis, positive QRS complexes in leads I and aVL (arrows), negative QRS complexes in lead aVR (circle), and normal R-wave progression.

■ DEXTROCARDIA, OTHER CONGENITAL CARDIOVASCULAR MALFORMATIONS

Dextrocardia was first described in early 17th century.¹ Situs solitus is the normal position of the heart and viscera, whereas situs inversus is a mirror-image anatomic arrangement of the organs. Situs inversus with dextrocardia, also called situs inversus totalis, is a rare condition (with a prevalence of 1 in 8,000) in which the heart and descending aorta are on the right and the thoracic and abdominal viscera are usually mirror images of the normal morphology.^{1,3,4} A mirror-image sinus node lies at the junction of the left superior vena cava and the left-sided (morphologic right) atrium.¹ People with situs inversus with dextrocardia are usually asymptomatic and have a normal life expectancy.^{1,2} Situs inversus with levocardia is a rare condition in which the heart is in the normal position but the viscera are in the dextro-position. This anomaly has a prevalence of 1 in 22,000.⁵

Atrial situs almost always corresponds to visceral situs. However, when the alignment of the atria and viscera is inconsistent and situs cannot be determined clearly because of the malpositioning of organs, the condition is called “situs ambiguous.” This is very rare, with a prevalence of 1 in 40,000.⁶

Risk factors

The cause of congenital cardiovascular malformations such as these is not known, but risk factors include positive family history, maternal diabetes, and cocaine use in the first trimester.⁷

The prevalence of congenital heart disease in patients with situs inversus with dextrocardia is low and ranges from 2% to 5%. This is in contrast to situs solitus with dextrocardia (isolated dextrocardia), which is almost always associated with cardiovascular anomalies.^{2,4} Kartagener syndrome—the triad of situs inversus, sinusitis, and bronchiectasis—occurs in 25% of people with situs inversus with dextrocardia.⁴ Situs inversus with levocardia is also frequently associated with cardiac anomalies.⁵

The major features of dextrocardia on ECG are:

- Negative P wave, QRS complex, and T wave in lead I
- Positive QRS complex in aVR
- Right-axis deviation
- Reversal of R-wave progression in the precordial leads.

Ventricular activation and repolarization are reversed, resulting in a negative QRS complex and an inverted T wave in lead I. The absence of R-wave progression in the pre-

People with situs inversus with dextrocardia are usually asymptomatic and have a normal life expectancy

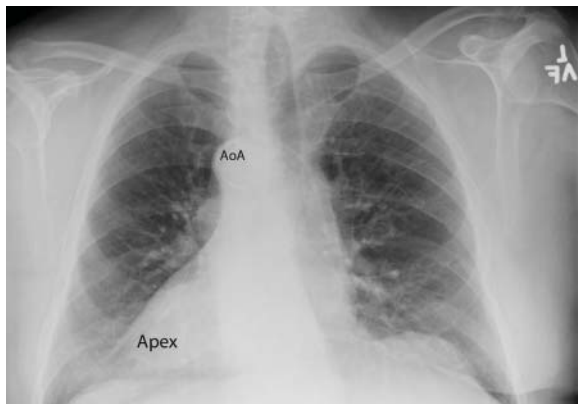


FIGURE 3. Chest radiography confirmed dextrocardia, showing a right-sided cardiac apex and a right-sided aortic arch (AoA).

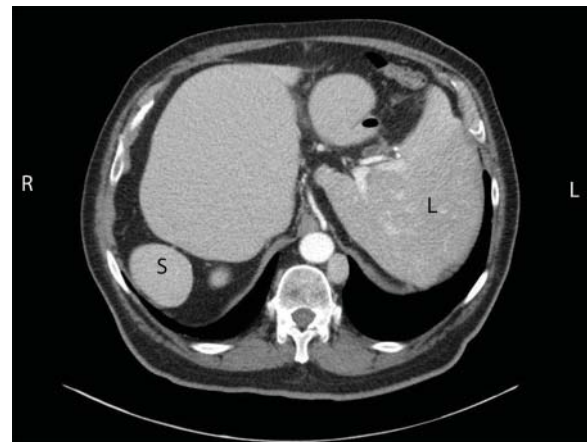


FIGURE 4. Computed tomography of the abdomen confirmed situs inversus totalis, with the liver (L) on the left side and the spleen (S) on the right side.

cordial leads helps differentiate mirror-image dextrocardia from erroneously reversed limb-electrode placement, which shows normal R-wave progression from V_1 to V_6 while showing similar features to those seen in dextrocardia in the limb leads.² In right-sided hookup, the limb electrodes are reversed, and the chest electrodes are recorded from the right precordium.

CORONARY INTERVENTIONS REQUIRE SPECIAL CONSIDERATION

In patients with dextrocardia, coronary interventions can be challenging because of the mirror-image position of the coronary ostia

and the aortic arch.⁸ These patients also need careful imaging, consideration of other associated congenital cardiac abnormalities, and detailed planning before cardiac surgery, including coronary artery bypass grafting.⁹

Patients with dextrocardia may present with cardiac symptoms localized to the right side of the body and have confusing clinical and diagnostic findings. Keeping dextrocardia and other such anomalies in mind can prevent delay in appropriately directed interventions. In a patient such as ours, the heart on the right side of the chest may indeed be “right.” Still, diagnostic tests to look for disorders encountered with dextrocardia may be necessary. ■

REFERENCES

1. Perloff JK. The cardiac malpositions. *Am J Cardiol* 2011; 108:1352–1361.
2. Tanawuttiwat T, Vasaiwala S, Dia M. ECG image of the month. Mirror mirror. *Am J Med* 2010; 123:34–36.
3. Douard R, Feldman A, Bargy F, Loric S, Delmas V. Anomalies of lateralization in man: a case of total situs inversus. *Surg Radiol Anat* 2000; 22:293–297.
4. Maldjian PD, Saric M. Approach to dextrocardia in adults: review. *AJR Am J Roentgenol* 2007; 188(suppl 6):S39–S49.
5. Gindes L, Hegesh J, Barkai G, Jacobson JM, Achiron R. Isolated levocardia: prenatal diagnosis, clinical importance, and literature review. *J Ultrasound Med* 2007; 26:361–365.
6. Abut E, Arman A, Güveli H, et al. Malposition of internal organs: a case of situs ambiguous anomaly in an adult. *Turk J Gastroenterol* 2003; 14:151–155.
7. Kuehl KS, Loffredo C. Risk factors for heart disease associated with abnormal sidedness. *Teratology* 2002; 66:242–248.
8. Aksoy S, Cam N, Gurkan U, Altay S, Bozbay M, Agirbasli M. Primary percutaneous intervention: for acute myocardial infarction in a patient with dextrocardia and situs inversus. *Tex Heart Inst J* 2012; 39:140–141.
9. Murtuza B, Gupta P, Goli G, Lall KS. Coronary revascularization in adults with dextrocardia: surgical implications of the anatomic variants. *Tex Heart Inst J* 2010; 37:633–640.

ADDRESS: Prashant Sharma, MD, Department of Hospital Internal Medicine, Mayo Clinic, 200 1st St. SW, OL-2, Rochester, MN 55905; e-mail: sharma.prashant@mayo.edu