

**DONIKA K. PATEL, DO**Division of Neurology, LeBauer HealthCare,  
Cone Health Medical Group, Greensboro, NC**KERRY H. LEVIN, MD**Chairman, Department of Neurology; Director,  
Neuromuscular Center, Neurological Institute,  
Cleveland Clinic; Professor, Cleveland Clinic Lerner  
College of Medicine of Case Western Reserve  
University, Cleveland, OH

# Bell palsy: Clinical examination and management

## ABSTRACT

Bell palsy is a common neurologic disorder characterized by acute facial mononeuropathy of unclear cause presenting with unilateral facial weakness. Careful examination and a detailed history are important in making an accurate diagnosis. Early recognition is essential, as treatment with corticosteroids within 72 hours of onset has been shown to hasten recovery. Fortunately, most patients recover spontaneously within 3 weeks, even if untreated.

## KEY POINTS

Bell palsy is an acute disorder of the facial nerve causing unilateral facial weakness, pain, abnormal taste, and reduced tearing.

Although herpes simplex virus reactivation is suspected in the pathogenesis, the exact cause is unknown.

An additional workup is warranted for abnormalities beyond isolated facial nerve palsy.

Guidelines recommend starting corticosteroids for patients who present within 3 days of symptom onset. There is no compelling evidence to support antiviral therapy, physical therapy, acupuncture, or surgical decompression.

**B**ELL PALSY is an idiopathic peripheral nerve disorder involving the facial nerve (ie, cranial nerve VII) and manifesting as acute, ipsilateral facial muscle weakness. It is named after Sir Charles Bell, who in 1821 first described the anatomy of the facial nerve.<sup>1</sup> Although the disorder is clinically benign, patients can be devastated by its disfigurement.

The annual incidence of Bell palsy is 20 per 100,000, with no predilection for sex or ethnicity. It can affect people at any age, but the incidence is slightly higher after age 40.<sup>2,3</sup> Risk factors include diabetes, pregnancy, severe preeclampsia, obesity, and hypertension.<sup>4-7</sup>

### ■ THE FACIAL NERVE IS VULNERABLE TO TRAUMA AND COMPRESSION

A basic understanding of the neuroanatomy of the facial nerve provides clues for distinguishing a central lesion from a peripheral lesion. This differentiation is important because the causes and management differ.

The facial nerve is a mixed sensory and motor nerve, carrying fibers involved in facial expression, taste, lacrimation, salivation, and sensation of the ear. It originates in the lower pons and exits the brainstem ventrally at the pontomedullary junction. After entering the internal acoustic meatus, it travels 20 to 30 mm in the facial canal, the longest bony course of any cranial nerve, making it highly susceptible to trauma and compression by edema.<sup>8</sup>

In the facial canal, it makes a posterior and inferior turn, forming a bend (ie, the genu of the facial nerve). The genu is proximal to the geniculate ganglion, which contains the facial nerve's primary sensory neurons for taste and sensation. The motor branch of the facial nerve then exits the cranium via the stylomas-

**TABLE 1**

**Approach to the clinical examination for Bell palsy**

**Observe for asymmetry** during the interview; pay close attention to blinking, the nasolabial folds, and the corners of the mouth

**General examination**, otoscopy, palpation for masses near the neck and face, and examination of the skin

**Assess motor function**, asking the patient to:

- Raise both eyebrows
- Close both eyes tightly
- Smile
- Puff out the cheeks
- Purse the lips
- Show both upper and lower teeth (grimace)

**Assess special sensory function**, if clinically indicated

- Sensation of the face and ear
- Taste sensation of anterior two-thirds of the tongue

**Assess reflexes**

- Orbicularis reflex: tap the glabella and observe asymmetry in blink pattern
- Bell phenomenon: observe upward movement of eyes during forced eye-closure

Isolated unilateral or asymmetric facial weakness in the absence of other cranial neuropathy supports the diagnosis of Bell palsy.

**Although Bell palsy is clinically benign, its disfigurement can be devastating**

toid foramen and passes through the parotid gland, where it divides into temporofacial and cervicofacial trunks.<sup>9</sup>

The facial nerve has five terminal branches that innervate the muscles of facial expression:

- **The temporal branch** (muscles of the forehead and superior part of the orbicularis oculi)
- **The zygomatic branch** (muscles of the nasolabial fold and cheek, eg, nasalis and zygomaticus).
- **The buccal branch** (the buccinators and inferior part of the orbicularis oculi)
- **The marginal mandibular branch** (the depressors of the mouth, eg, depressor anguli and mentalis)
- **The cervical branch** (the platysma muscle).

**INFLAMMATION IS BELIEVED TO BE RESPONSIBLE**

Although the precise cause of Bell palsy is not known, one theory is that inflammation of the nerve causes focal edema, demyelination, and ischemia. Several studies have suggested that

herpes virus simplex type 1 infection may be involved.<sup>10</sup>

**FACIAL DROOPING, EYELID WEAKNESS, OTHER SYMPTOMS**

Symptoms of Bell palsy include ipsilateral sagging of the eyebrow, drooping of the face, flattening of the nasolabial fold, and inability to fully close the eye, pucker the lips, or raise the corner of the mouth (**Figure 1**). Symptoms develop within hours and are maximal by 3 days.

About 70% of patients have associated ipsilateral pain around the ear. If facial pain is present with sensory and hearing loss, a tumor of the parotid gland or viral otitis must be considered.<sup>11</sup> Other complaints may include hyperacusis due to disruption of nerve fibers to the stapedius muscle, changes in taste, and dry eye from parasympathetic dysfunction. Some patients report paresthesias over the face, which most often represent motor symptoms misconstrued as sensory changes.

**PHYSICAL EXAMINATION**

The clinical examination should include a complete neurologic and general examination, including otoscopy and attention to the skin and parotid gland. Vesicles or scabbing around the ear should prompt testing for herpes zoster. Careful observation during the interview while the patient is talking may reveal subtle signs of weakness and provide additional clues.

A systematic approach to the assessment of a patient with suspected Bell palsy is recommended (**Table 1**) and outlined below:

**Does the patient have peripheral facial palsy?**

In Bell palsy, wrinkling of the forehead on the affected side when raising the eyebrows is either asymmetrical or absent.

If the forehead muscles are spared and the lower face is weak, this signifies a central lesion such as a stroke or other structural abnormality and not a peripheral lesion of the facial nerve (eg, Bell palsy).

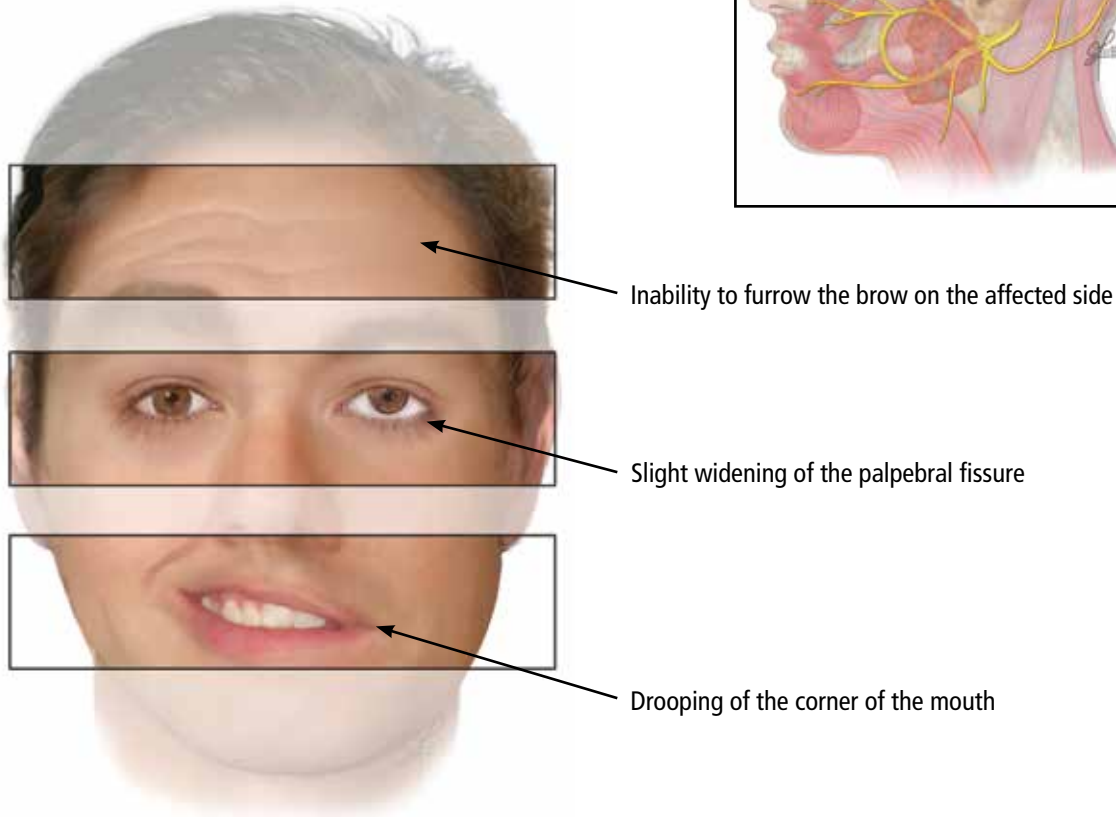
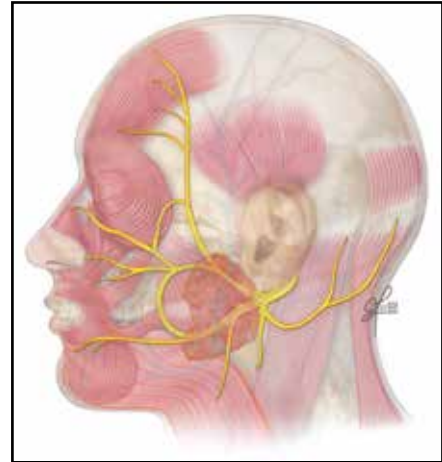
**Can the patient close the eyes tightly?**

Normally, the patient should be able to close both eyes tightly, and the eyelashes should be buried between the eyelids. In Bell palsy, when

## Facial asymmetry in Bell palsy

The **facial nerve** is a mixed sensory and motor nerve, carrying fibers involved in facial expression, taste, lacrimation, salivation, and sensation of the ear.

**Bell palsy**, due to dysfunction of the facial nerve, typically causes paralysis or weakness of the muscles on one side of the face. In the patient below, the left side of the face is affected, causing:



CCF  
Medical Illustrator: Jeff Loerch ©2015

### FIGURE 1

the patient attempts to close the eyes, the affected side shows incomplete closure, and the eye may remain partly open.

Assess the strength of the orbicularis oculi by trying to open the eyes. The patient who is attempting to close the eyelids tightly but cannot will demonstrate the Bell phenomenon, ie, the examiner is able to force open the eyelids, and the eyes are deviated upward and laterally.

Closely observe the blink pattern, as the

involved side in Bell palsy may slightly lag behind the normal eye, and the patient may be unable to close the eye completely.

#### Is the smile symmetric?

Note flattening of the nasolabial fold on one side, which indicates facial weakness.

#### Can the patient puff out the cheeks?

Ask the patient to hold air in the mouth against resistance. This assesses the strength

of the buccinator muscle.

**Can the patient purse the lips?**

Ask the patient to pucker or purse the lips and observe for asymmetry or weakness on the affected side.

Test the orbicularis oris muscle by trying to spread the lips apart while the patient resists, and observe for weakness on one side.

**Is there a symmetric grimace?**

This will test the muscles involved in depressing the angles of the mouth and platysma.

**Are taste, sensation, and hearing intact?**

Other testable functions of the facial nerve, including taste, sensation, and hearing, do not always need to be assessed but can be in patients with specific sensory deficits.

Abnormalities in taste can support localization of the problem either proximal or distal to the branch point of fibers mediating taste. The facial nerve supplies taste fibers to the anterior two-thirds of the tongue. Sweet and salty taste can be screened with sugar and salt. Tell the patient to close the eyes, and using a tongue blade, apply a small amount of sugar or salt on the side of the tongue. Ask the patient to identify the taste and repeat with the other sample after he or she has rinsed the mouth.

Somatic sensory fibers supplied by the facial nerve innervate the inner ear and a small area behind the ear, but these may be difficult to assess objectively. Formal audiologic testing may be needed if hearing is impaired.

**Facial nerve reflexes**

A number of facial reflexes can be tested, including the orbicularis oculi, palpebral-oculogyric, and corneal reflexes.<sup>12</sup>

**The orbicularis oculi reflex** is tested by gentle finger percussion of the glabella while observing for involuntary blinking with each stimulus. The afferent branch of this reflex is carried by the trigeminal nerve, while the efferent response is carried by the facial nerve. In peripheral facial nerve palsy, this reflex is weakened or absent on the affected side.

**The palpebral-oculogyric reflex**, or Bell phenomenon, produces upward and lateral deviation of the eyes when attempting forceful

eyelid closure. In this reflex, the afferent fibers are carried by the facial nerve and the efferent fibers travel in the oculomotor nerve to the superior rectus muscle. In Bell palsy, this reflex is visible because of failure of adequate eyelid closure.

**The corneal reflex** is elicited by stimulating the cornea with a wisp of cotton, causing reflexive closure of the both eyes. The affected side may show slowed or absent lid closure when tested on either side. The sensory afferent fibers are carried by the trigeminal nerve, and the motor efferent fibers are carried by the facial nerve.

**Grading of facial paralysis**

The House-Brackmann scale is the most widely used tool for grading the degree of facial paralysis and for predicting recovery. Grades are I to VI, with grade I indicating normal function, and grade VI, complete paralysis.

Patients with some preserved motor function generally have good recovery, but those with complete paralysis may have long-term residual deficits.<sup>13</sup>

**■ A DIAGNOSIS OF EXCLUSION**

The diagnosis of Bell palsy is made by excluding other causes of unilateral facial paralysis, and 30% to 60% of cases of facial palsy are caused by an underlying disorder that mimics Bell palsy, including central nervous system lesion (eg, stroke, demyelinating disease), parotid gland tumor, Lyme disease, Ramsay Hunt syndrome, granulomatous disease, otitis media, cholesteatoma, diabetes, trauma, and Guillain-Barré syndrome (**Table 2**).<sup>14,15</sup> Many of these conditions have associated features that help distinguish them from Bell palsy. Facial palsy that does not improve after 3 weeks should prompt referral to a neurologist.

**Brain lesions**

It is uncommon to have isolated facial palsy with a cortical or subcortical brain lesion, since the corticobulbar and corticospinal tracts travel in close proximity. Cortical signs such as hemiparesis, hemisensory loss, neglect, and dysarthria suggest a lesion of the cerebral cortex. Additionally, forehead muscle sparing is expected in supranuclear lesions.

Brainstem lesions can manifest with multi-

**Facial palsy that does not improve after 3 weeks should prompt a referral to a neurologist**

TABLE 2

Differential diagnosis of Bell palsy

Differential diagnosis	Cause	Distinguishing characteristics
<b>Central nervous system lesion</b>	Stroke, space-occupying lesion	Forehead sparing, headache, limb weakness, multiple neurologic signs
<b>Autoimmune diseases</b>	Guillain-Barré syndrome	Ascending weakness, absent reflexes
	Multiple sclerosis	Upper motor neuron signs, abnormal cerebrospinal fluid
<b>Metabolic diseases</b>	Diabetes	Elevated blood glucose
<b>Infectious diseases</b>		
Meningitis, encephalitis	Viral, bacterial, fungal pathogen	Headache, fever, meningeal signs, abnormal cerebrospinal fluid
Herpes simplex	Reactivation of herpes simplex virus type 1 from geniculate ganglion	Fever, malaise
Lyme disease	<i>Borrelia burgdorferi</i>	Rash, arthralgia, malaise, bilateral facial palsy
Ramsay Hunt syndrome	Varicella zoster	Pain, vesicular eruption
<b>Granulomatous disease</b>	Sarcoidosis	Bilateral facial palsy, elevated angiotensin-converting enzyme
<b>Neoplasm</b>	Parotid tumor, facial nerve tumor, metastasis	Insidious onset, palpable mass, partial involvement of facial nerve branches

Serologic testing, electrodiagnostic studies, and imaging are not routinely necessary to diagnose Bell palsy

ple ipsilateral cranial nerve palsies and contralateral limb weakness. Sarcoidosis and leptomeningeal carcinomatosis tend to involve the skull base and present with multiple cranial neuropathies.

Tumors of the brain or parotid gland have an insidious onset and may cause systemic signs such as fevers, chills, and weight loss. Headache, seizures, and hearing loss indicate an intracranial lesion. A palpable mass near the ear, neck, or parotid gland requires imaging of the face to look for a parotid gland tumor.

Infection

A number of infections can cause acute facial paralysis. The most common is herpes simplex virus, and the next most common is varicella zoster.<sup>14</sup> Herpes simplex virus, Ramsay Hunt syndrome, and Lyme disease may have associated pain and skin changes. Erythema of the

tympanic membrane suggests otitis media, especially in the setting of ear pain and hearing loss.

Ramsay Hunt syndrome is caused by reactivation of the herpes zoster virus from the geniculate ganglion, affecting the facial nerve. Careful examination of the ear canal and the oropharynx may show vesicles.

In Lyme disease, facial palsy is the most common cranial neuropathy, seen in 50% to 63% of patients with *Borrelia burgdorferi* meningitis.<sup>16,17</sup> In people with a history of rash, arthralgia, tick bite, or travel to an endemic region, Lyme titers should be checked before starting the patient on corticosteroids.

Bilateral facial palsy is rare and occurs in fewer than 1% of patients. It has been reported in patients with Lyme disease, Guillain-Barré syndrome, sarcoidosis, diabetes mellitus, viral infection, and pontine glioma.<sup>18</sup>

**■ DIAGNOSTIC EVALUATION**

Serologic testing, electrodiagnostic studies, and imaging are not routinely necessary to diagnose Bell palsy. However, referral to the appropriate specialist (neurologist, otolaryngologist, optometrist, ophthalmologist) is advised if the patient has sparing of the forehead muscle, multiple cranial neuropathies, signs of infection, or persistent weakness without significant improvement at 3 weeks.

**Laboratory testing**

A complete blood cell count with differential may point to infection or a lymphoproliferative disorder. When indicated, screening for diabetes mellitus with fasting blood glucose or hemoglobin A<sub>1c</sub> may be helpful. In Lyme-endemic regions, patients should undergo an enzyme-linked immunosorbent assay or an indirect fluorescent antibody test to screen for the disease. If positive, the diagnosis of Lyme disease should be confirmed by Western blot. If vesicles are present on examination, check serum antibodies for herpes zoster. In the appropriate clinical setting, angiotensin-converting enzyme, human immunodeficiency virus, and inflammatory markers can be tested.

Cerebrospinal fluid analysis is generally not helpful in diagnosing Bell palsy but can differentiate it from Guillain-Barré syndrome, leptomeningeal carcinomatosis, and infection involving the central nervous system.

**Imaging**

Imaging is not recommended in the initial evaluation of Bell palsy unless symptoms and the examination are atypical. From 5% to 7% of cases of facial palsy are caused by a tumor (eg, facial neuroma, cholesteatoma, hemangioma, meningioma), whether benign or malignant.<sup>14,15</sup> Therefore, in patients with insidious onset of symptoms that do not improve in about 3 weeks, contrast-enhanced computed tomography or gadolinium-enhanced magnetic resonance imaging of the internal auditory canal and face is warranted.

**Electrodiagnostic studies**

Electrodiagnostic testing is typically not part of the evaluation of acute Bell palsy, but in patients with complete paralysis, it may help assess the degree of nerve injury and the

chances of recovery, especially since patients with complete paralysis have a higher risk of incomplete recovery.<sup>19</sup> Electrodiagnostic studies should be performed at least 1 week after symptom onset to avoid false-negative results.

**■ TREATMENT**

The treatment of Bell palsy focuses on maximizing recovery and minimizing associated complications.

**Protect the eyes**

Patients who cannot completely close their eyes should be given instructions on ocular protective care to prevent exposure keratopathy. Frequent application of lubricant eyedrops with artificial tears during the day or ophthalmic ointment at bedtime is recommended. The physician should also recommend protective eyewear such as sunglasses during the day. Eye patching or taping at night may be useful but could be harmful if applied too loosely or too tightly. Patients with vision loss or eye irritation should be referred to an ophthalmologist.<sup>19</sup>

**Corticosteroids are recommended in the first 72 hours**

In two randomized clinical trials (conducted by Sullivan et al<sup>20</sup> in 511 patients and Engström et al<sup>21</sup> in 829 patients), prednisolone was found to be beneficial if started within 72 hours of symptom onset.

In a double-blind, randomized, placebo-controlled study of prednisone in 58 patients, those who received the drug recovered faster, although long-term outcomes in these patients were not significantly different than those in the control group.<sup>22</sup> The American Academy of Neurology<sup>23</sup> rated this study as class II, ie, not meeting all of its criteria for the highest level of evidence, class I. Nevertheless, although prednisone lacks class I evidence, its use is recommended because it is a precursor to its active metabolite, prednisolone, which has been studied extensively.

The current guidelines of the American Academy of Neurology, updated in 2012, state, “For patients with new-onset Bell palsy, steroids are highly likely to be effective and should be offered to increase the probability of recovery of facial nerve function”<sup>23</sup> (level

**Most patients with Bell palsy recover spontaneously without treatment—especially those with mild symptoms**

TABLE 3

**Bell palsy treatment recommendations for adults presenting within 72 hours**

Class of medication	Recommendation grade	Examples
<b>Corticosteroids</b>	A (established as effective)	Prednisone 50 mg orally daily for 5 days, followed by 10 mg less each day for 5 days Prednisolone 50 mg orally daily for 10 days
<b>Antivirals<sup>a</sup></b>	C (possibly effective)	Valacyclovir 1 g three times daily for 7 days <sup>b</sup> Acyclovir 400 mg five times daily for 7 days <sup>b</sup>

<sup>a</sup> In combination with corticosteroids for moderate to severe weakness.

<sup>b</sup> Dose should be adjusted for patients with impaired renal clearance.

Based on American Academy of Neurology guidelines, Gronseth GS, Paduga R; American Academy of Neurology. Evidence-based guideline update: steroids and antivirals for Bell palsy: report of the Guideline Development Subcommittee of the American Academy of Neurology. *Neurology* 2012; 79:2209–2213.

A evidence, ie, established as effective). They also concluded that adverse effects of corticosteroids were generally minor and temporary.

Similarly, the guidelines of the American Academy of Otolaryngology–Head and Neck Surgery, published in 2013, recommend oral corticosteroids within 72 hours of onset of symptoms of Bell palsy for patients age 16 and older.<sup>19</sup> The recommendation is for a 10-day course of corticosteroids with at least 5 days at a high dose (prednisolone 50 mg orally daily for 10 days, or prednisone 60 mg orally daily for 5 days, followed by a 5-day taper). The benefit of corticosteroids after 72 hours is unclear (Table 3).<sup>19</sup>

Even though the guidelines recommend corticosteroids, the decision to use them in diabetic patients and pregnant women should be individualized. Discretion is advised, as not all patients with Bell palsy need to be treated. Most recover spontaneously, especially those with mild symptoms.

**Antiviral therapy may offer modest benefit**

Antiviral therapy has not been shown to be beneficial in Bell palsy, and current guidelines do not recommend oral antiviral therapy alone.<sup>19</sup> However, an antiviral combined with a corticosteroid may offer modest benefit if started within 72 hours of symptom onset (level C evidence, ie, possibly effective).<sup>23</sup> Patients starting antiviral therapy should under-

stand that its benefit has not been established.

**Surgical decompression remains controversial**

A Cochrane systematic review in 2011 found insufficient evidence regarding the safety and efficacy of surgical intervention in Bell palsy.<sup>24</sup> Surgery should be considered only for patients with complete paralysis with a greater than 90% reduction in motor amplitude on a nerve conduction study compared with the unaffected side, and absent volitional activity on needle examination.<sup>19,25</sup>

**Acupuncture: No recommendation**

Currently, there is no recommendation for acupuncture in the treatment of Bell palsy.<sup>19</sup> A recent randomized clinical trial suggests benefit from acupuncture combined with corticosteroids,<sup>26</sup> but high-quality studies to support its use are lacking.<sup>26</sup>

**Physical therapy: Insufficient evidence**

There is insufficient evidence to show that physical therapy has benefit—or harm—in Bell palsy. However, some low-quality studies indicated that facial exercises and mime therapy may improve function in patients with moderate paralysis.<sup>27</sup>

**Follow-up**

Patients should be instructed to call at 2 weeks to report progress of symptoms and to be re-

**Instruct patients to call at 2 weeks to report progress of symptoms**

evaluated within or at 1 month, with close attention to facial weakness and eye irritation. Further evaluation is needed if there has been no improvement, if symptoms have worsened, or if new symptoms have appeared.

The psychosocial impact of Bell palsy cannot be discounted, as the disfigurement can have negative implications for self-esteem and social relationships. Appropriate referral to an ophthalmologist, neurologist, otolaryngologist, social worker, or a plastic surgeon may be necessary.

**■ COMPLICATIONS AND PROGNOSIS**

Most patients with Bell palsy recover completely, but up to 30% have residual symptoms at 6 months.<sup>14,20</sup> Furthermore, although Bell

palsy usually has a monophasic course, 7% to 12% of patients have a recurrence.<sup>3,15</sup>

Long-term complications can include residual facial weakness, facial synkinesis, facial contracture, and facial spasm.<sup>14,28</sup> Incomplete eye closure may benefit from surgery (tarsorrhaphy or gold-weight implantation) to prevent corneal ulceration. Facial synkinesis is due to aberrant nerve regeneration and occurs in 15% to 20% of patients after recovery from Bell palsy.<sup>29</sup> Patients may describe tearing while chewing (“crocodile tears”), involuntary movement of the corners of the mouth with blinking, or ipsilateral eye-closing when the jaw opens (“jaw-winking”). Facial contracture, facial synkinesis, and facial spasm can be treated with botulinum toxin injection.<sup>30</sup> ■

**■ REFERENCES**

1. **Grzybowski A, Kaufman MH.** Sir Charles Bell (1774-1842): contributions to neuro-ophthalmology. *Acta Ophthalmol Scand* 2007; 85:897-901.
2. **De Diego-Sastre JI, Prim-Espada MP, Fernández-García F.** The epidemiology of Bell's palsy. *Rev Neurol* 2005; 41:287-290. In Spanish.
3. **Morris AM, Deeks SL, Hill MD, et al.** Annualized incidence and spectrum of illness from an outbreak investigation of Bell's palsy. *Neuroepidemiology* 2002; 21:255-261.
4. **Bosco D, Plastino M, Bosco F, et al.** Bell's palsy: a manifestation of prediabetes? *Acta Neurol Scand* 2011; 123:68-72.
5. **Riga M, Kefalidis G, Danielides V.** The role of diabetes mellitus in the clinical presentation and prognosis of Bell palsy. *J Am Board Fam Med* 2012; 25:819-826.
6. **Hilsinger RL Jr, Adour KK, Doty HE.** Idiopathic facial paralysis, pregnancy, and the menstrual cycle. *Ann Otol Rhinol Laryngol* 1975; 84:433-442.
7. **Savadi-Oskouei D, Abedi A, Sadeghi-Bazargani H.** Independent role of hypertension in Bell's palsy: a case-control study. *Eur Neurol* 2008; 60:253-257.
8. **Murai A, Kariya S, Tamura K, et al.** The facial nerve canal in patients with Bell's palsy: an investigation by high-resolution computed tomography with multiplanar reconstruction. *Eur Arch Otorhinolaryngol* 2013; 270:2035-2038.
9. **Blumenfeld H.** *Neuroanatomy Through Clinical Cases*. 1st ed. Sunderland, MA: Sinauer; 2002:479-484.
10. **Murakami S, Mizobuchi M, Nakashiro Y, Doi T, Hato N, Yanagihara N.** Bell palsy and herpes simplex virus: identification of viral DNA in endoneurial fluid and muscle. *Ann Intern Med* 1996; 124:27-30.
11. **Boahene DO, Olsen KD, Driscoll C, Lewis JE, McDonald TJ.** Facial nerve paralysis secondary to occult malignant neoplasms. *Otolaryngol Head Neck Surg* 2004; 130:459-465.
12. **DeJong RN.** *The Neurologic Examination: Incorporating the fundamentals of neuroanatomy and neurophysiology*. 4th ed. New York, NY: Harper & Row; 1979:178-198.
13. **House JW, Brackmann DE.** Facial nerve grading system. *Otolaryngol Head Neck Surg* 1985; 93:146-147.
14. **Peitersen E.** Bell's palsy: the spontaneous course of 2,500 peripheral facial nerve palsies of different etiologies. *Acta Otolaryngol Suppl* 2002; 549:4-30.
15. **Hohman MH, Hadlock TA.** Etiology, diagnosis, and management of facial palsy: 2000 patients at a facial nerve center. *Laryngoscope* 2014; 124:E283-E293.
16. **Ackermann R, Hörstrup P, Schmidt R.** Tick-borne meningopolyneuritis (Garin-Bujadoux, Bannwarth). *Yale J Biol Med* 1984; 57:485-490.
17. **Pachner AR, Steere AC.** The triad of neurologic manifestations of Lyme disease: meningitis, cranial neuritis, and radiculoneuritis. *Neurology* 1985; 35:47-53.
18. **Keane JR.** Bilateral seventh nerve palsy: analysis of 43 cases and review of the literature. *Neurology* 1994; 44:1198-1202.
19. **Baugh RF, Basura GJ, Ishii LE, et al.** Clinical practice guideline: Bell's palsy. *Otolaryngol Head Neck Surg* 2013; 149(suppl 3):S1-S27.
20. **Sullivan FM, Swan IR, Donnan PT, et al.** Early treatment with prednisolone or acyclovir in Bell's palsy. *N Engl J Med* 2007; 357:1598-1607.
21. **Engström M, Berg T, Stjernquist-Desatnik A, et al.** Prednisolone and valaciclovir in Bell's palsy: a randomised, double-blind, placebo-controlled, multicentre trial. *Lancet Neurol* 2008; 7:993-1000.
22. **Lagalla G, Logullo F, Di Bella P, Provinciali L, Ceravolo MG.** Influence of early high-dose steroid treatment on Bell's palsy evolution. *Neuro Sci* 2002; 23:107-112.
23. **Gronseth GS, Paduga R; American Academy of Neurology.** Evidence-based guideline update: steroids and antivirals for Bell palsy: report of the Guideline Development Subcommittee of the American Academy of Neurology. *Neurology* 2012; 79:2209-2213.
24. **McAllister K, Walker D, Donnan PT, Swan I.** Surgical interventions for the early management of Bell's palsy. *Cochrane Database Syst Rev* 2011; 2:CD007468.
25. **Gantz BJ, Rubinstein JT, Gidley P, Woodworth GG.** Surgical management of Bell's palsy. *Laryngoscope* 1999; 109:1177-1188.
26. **Xu SB, Huang B, Zhang CY, et al.** Effectiveness of strengthened stimulation during acupuncture for the treatment of Bell palsy: a randomized controlled trial. *CMAJ* 2013; 185:473-479.
27. **Teixeira LJ, Valbuza JS, Prado GF.** Physical therapy for Bell's palsy (idiopathic facial paralysis). *Cochrane Database Syst Rev* 2011; 12:CD006283.
28. **Yaltho TC, Jankovic J.** The many faces of hemifacial spasm: differential diagnosis of unilateral facial spasms. *Mov Disord* 2011; 26:1582-1592.
29. **Celik M, Forta H, Vural C.** The development of synkinesis after facial nerve paralysis. *Eur Neurol* 2000; 43:147-151.
30. **Chua CN, Quhill F, Jones E, Voon LW, Ahad M, Rowson N.** Treatment of aberrant facial nerve regeneration with botulinum toxin A. *Orbit* 2004; 23:213-218.

ADDRESS: Donika K. Patel, DO, LeBauer Neurology, 301 East Wendover Avenue, Suite 310, Greensboro, NC 27401; e-mail: ccf.pateld6@gmail.com