

Q: Does stenting of severe renal artery stenosis improve outcomes compared with medical therapy alone?

AMJAD KABACH, MD

Department of Medicine, Creighton University, Omaha, NE

OSAMA QASIM AGHA, MD

Department of Internal Medicine, St. Joseph's Hospital and Medical Center, Phoenix, AZ

MOTAZ BAIBARS, MD, FACP

Department of Hospital Medicine, Peninsula Regional Medical Center, Salisbury, MD

ABDUL HAMID ALRAIYES, MD

Pulmonary, Allergy, and Critical Care Medicine, Respiratory Institute, Cleveland Clinic, Cleveland, OH

M. CHADI ALRAIES, MD, FACP

Department of Medicine, Cardiovascular Division, University of Minnesota, Minneapolis

A: No. In patients with severe atherosclerotic renal artery stenosis and hypertension or chronic kidney disease, renal artery stenting offers no additional benefit when added to comprehensive medical therapy.

See related editorial, page 495

In these patients, renal artery stenting in addition to antihypertensive drug therapy can improve blood pressure control modestly but has no significant effect on outcomes such as adverse cardiovascular events and death. And because renal artery stenting carries a risk of complications, medical management should continue to be the first-line therapy.

RENAL ARTERY STENOSIS

Renal artery stenosis is a common form of peripheral artery disease. Atherosclerosis is the most common cause, but it can also be caused by fibromuscular dysplasia or vasculitis (eg, Takayasu arteritis). It is most often unilateral,

but bilateral disease has also been reported.

The prevalence of atherosclerotic renal vascular disease in the US Medicare population is 0.5%, and 5.5% in those with chronic kidney disease.¹ Furthermore, renal artery stenosis is found in 6.8% of adults over age 65.² The prevalence increases with age and is higher in patients with hyperlipidemia, peripheral arterial disease, and hypertension. The prevalence of renal artery stenosis in patients with atherosclerotic disease and renal dysfunction is as high as 50%.³

Patients with peripheral artery disease may be five times more likely to develop renal artery stenosis than people without peripheral artery disease.⁴ Significant stenosis can result in resistant arterial hypertension, renal insufficiency, left ventricular hypertrophy, and congestive heart failure.⁵

Nephropathy due to renal artery stenosis is complex and is caused by hypoperfusion and chronic microatheroembolism. Renal artery stenosis leads to oxidative stress, inflammation, fibrosis in the stenotic kidney, and, over time, loss of kidney function. Hypoperfusion also leads to activation of the renin-angiotensin-aldosterone system, which plays a role in development of left ventricular hypertrophy.^{5,6}

Adequate blood pressure control, goal-directed lipid-lowering therapy, smoking cessation, and other preventive measures are the foundation of management.

RENAL ARTERY STENOSIS AND HYPERTENSION

Renal artery stenosis is a cause of secondary hypertension. The stenosis decreases renal perfusion pressure, activating the release of renin and the production of angiotensin II, which in

Renal artery stenting added to drug therapy can modestly improve blood pressure control, but has no significant effect on outcomes

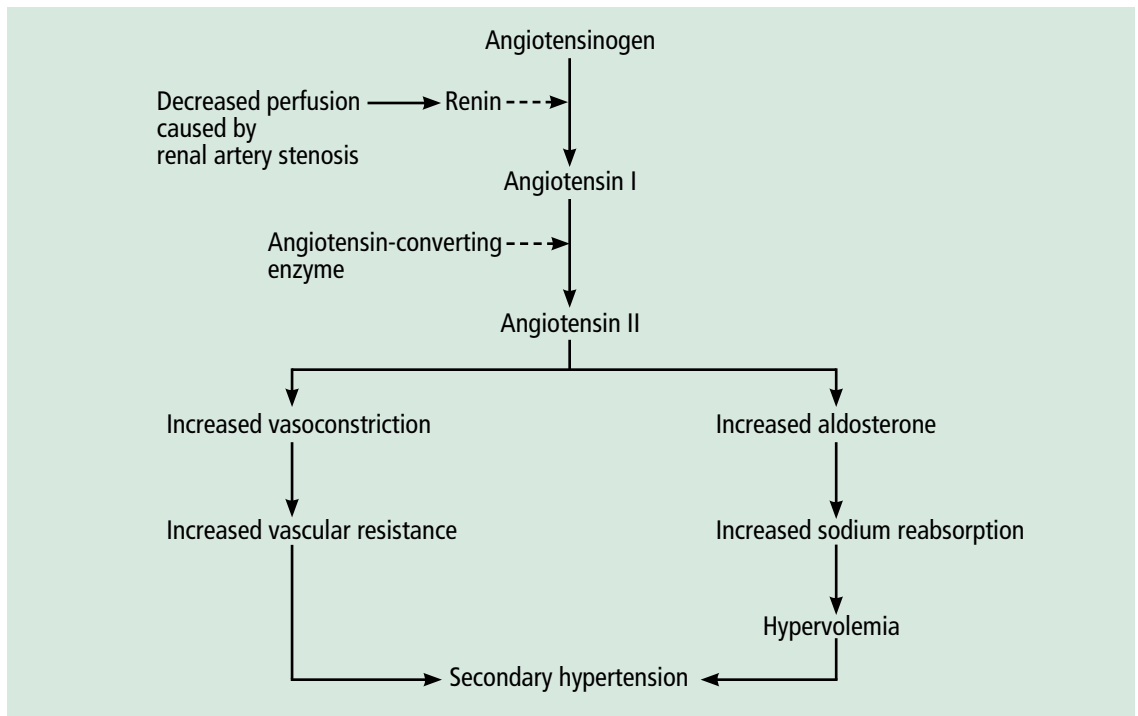


FIGURE 1. Pathophysiology of hypertension in renal artery stenosis.

Renal artery stenosis raises blood pressure both directly and indirectly

turn raises the blood pressure by two mechanisms (**Figure 1**): directly, by causing generalized vasoconstriction, and indirectly, by stimulating the release of aldosterone, which in turn increases the reabsorption of sodium and causes hypervolemia. These two mechanisms play a major role in renal vascular hypertension when renal artery stenosis is bilateral. In unilateral renal artery stenosis, pressure diuresis in the unaffected kidney compensates for the reabsorption of sodium in the affected kidney, keeping the blood pressure down. However, with time, the unaffected kidney will develop hypertensive nephropathy, and pressure diuresis will be lost.^{7,8} In addition, the activation of the renin-angiotensin-aldosterone system results in structural heart disease, such as left ventricular hypertrophy,⁵ and may shorten survival.

■ STENTING PLUS ANTIHYPERTENSIVE DRUG THERAPY

Because observational studies showed improvement in blood pressure control after endovascular stenting of atherosclerotic renal artery stenosis,^{9,10} this approach became a treatment option for uncontrolled hypertension in these patients. The 2005 joint guide-

lines of the American College of Cardiology and the American Heart Association¹¹ considered percutaneous revascularization a reasonable option (level of evidence B) for patients who meet one of the following criteria:

- Hemodynamically significant stenosis and accelerated, resistant, or malignant hypertension, hypertension with an unexplained unilateral small kidney, or hypertension with intolerance to medication
- Renal artery stenosis and progressive chronic kidney disease with bilateral stenosis or stenosis in a solitary functioning kidney
- Hemodynamically significant stenosis and recurrent, unexplained congestive heart failure or sudden, unexplained pulmonary edema or unstable angina.¹¹

However, no randomized study has shown a direct benefit of renal artery stenting on rates of cardiovascular events or renal function compared with drug therapy alone.

■ TRIALS OF STENTING VS MEDICAL THERAPY ALONE

Technical improvements have led to more widespread use of diagnostic and interventional endovascular tools for renal artery re-

vascularization. Studies over the past 10 years examined the impact of stenting in patients with uncontrolled hypertension.

The STAR trial

In the Stent Placement and Blood Pressure and Lipid-lowering for the Prevention of Progression of Renal Dysfunction Caused by Atherosclerotic Ostial Stenosis of the Renal Artery (STAR) trial,⁹ patients with creatinine clearance less than 80 mL/min/1.73 m², renal artery stenosis greater than 50%, and well-controlled blood pressure were randomized to either renal artery stenting plus medical therapy or medical therapy alone. The authors concluded that stenting had no effect on the progression of renal dysfunction but led to a small number of significant, procedure-related complications. The study was criticized for including patients with mild stenosis (< 50% stenosis) and for being underpowered for the primary end point.

The ASTRAL study

The Angioplasty and Stenting for Renal Artery Lesions (ASTRAL) study¹⁰ was a similar comparison with similar results, showing no benefit from stenting with respect to renal function, systolic blood pressure control, cardiovascular events, or death.

HERCULES

The Herculink Elite Cobalt Chromium Renal Stent Trial to Demonstrate Efficacy and Safety (HERCULES)¹² was a prospective multicenter study of the effects of renal artery stenting in 202 patients with significant renal artery stenosis and uncontrolled hypertension. It showed a reduction in systolic blood pressure from baseline ($P < .0001$). However, follow-up was only 9 months, which was insufficient to show a significant effect on long-term cardiovascular and cerebrovascular outcomes.

The CORAL trial

The Cardiovascular Outcomes in Renal Atherosclerotic Lesions (CORAL) trial¹³ used

more stringent definitions and longer follow-up. It randomized 947 patients to either stenting plus medical therapy or medical therapy alone. Patients had atherosclerotic renal artery stenosis, defined as stenosis of at least 80% or stenosis of 60% to 80% with a gradient of at least 20 mm Hg in the systolic pressure), and either systolic hypertension while taking two or more antihypertensive drugs or stage 3 or higher chronic kidney disease (glomerular filtration rate < 60 mL/min/1.73 m² as calculated by the Modification of Diet in Renal Disease formula).

Participants were followed for 43 months to detect the occurrence of adverse cardiovascular and renal events. There was no significant difference in primary outcome between stenting plus drug therapy and drug therapy alone (35.1% and 35.8%, respectively; $P = .58$). However, stenting plus drug therapy was associated with modestly lower systolic pressures compared with drug therapy alone (-2.3 mm Hg, 95% confidence interval -4.4 to -0.2 mm Hg, $P = .03$).¹³ This study provided strong evidence that renal artery stenting offers no significant benefit to patients with moderately severe atherosclerotic renal artery stenosis, and that stenting may actually pose an unnecessary risk.

■ COMPLICATIONS OF RENAL ARTERY STENTING

Complications of renal artery stenting are a limiting factor compared with drug therapy alone, especially since the procedure offers no significant benefit in outcome. Procedural complication rates of 10% to 15% have been reported.^{9,10,12} The CORAL trial reported arterial dissection in 2.2%, branch-vessel occlusion in 1.2%, and distal embolization in 1.2% of patients undergoing stenting.¹³ Other reported complications have included stent misplacement requiring an additional stent, access-vessel damage, stent embolization, renal artery thrombosis or occlusion, and death.^{10,12} ■

Complications of renal artery stenting are a limiting factor compared with drug therapy alone

■ REFERENCES

1. Kalra PA, Guo H, Kausz AT, et al. Atherosclerotic renovascular disease in United States patients aged 67 years or older: risk factors, revascularization, and prognosis. *Kidney Int* 2005; 68:293–301.
2. Hansen KJ, Edwards MS, Craven TE, et al. Prevalence of renovascular disease in the elderly: a population-based study. *J Vasc Surg* 2002; 36:443–451.
3. Uzu T, Takeji M, Yamada N, et al. Prevalence and outcome of renal artery stenosis in atherosclerotic patients with renal dysfunction. *Hypertens Res* 2002; 25:537–542.
4. Benjamin MM, Fazel P, Filardo G, Choi JW, Stoler RC. Prevalence of and risk factors of renal artery stenosis in

- patients with resistant hypertension. *Am J Cardiol* 2014; 113:687–690.
5. **Wu S, Polavarapu N, Stouffer GA.** Left ventricular hypertrophy in patients with renal artery stenosis. *Am J Med Sci* 2006; 332:334–338.
 6. **Lerman LO, Textor SC, Grande JP.** Mechanisms of tissue injury in renal artery stenosis: ischemia and beyond. *Prog Cardiovasc Dis* 2009; 52:196–203.
 7. **Black HR, Glickman MG, Schiff M Jr, Pingoud EG.** Renovascular hypertension: pathophysiology, diagnosis, and treatment. *Yale J Biol Med* 1978; 51:635–654.
 8. **Tobe SW, Burgess E, Lebel M.** Atherosclerotic renovascular disease. *Can J Cardiol* 2006; 22:623–628.
 9. **Bax L, Mali WP, Buskens E, et al; STAR Study Group.** The benefit of stent placement and blood pressure and lipid-lowering for the prevention of progression of renal dysfunction caused by atherosclerotic ostial stenosis of the renal artery. The STAR-study: rationale and study design. *J Nephrol* 2003; 16:807–812.
 10. **ASTRAL Investigators; Wheatley K, Ives N, Gray R, et al.** Revascularization versus medical therapy for renal-artery stenosis. *N Engl J Med* 2009; 361:1953–1962.
 11. **Hirsch AT, Haskal ZJ, Hertzner NR, et al.** ACC/AHA 2005 guidelines for the management of patients with peripheral arterial disease (lower extremity, renal, mesenteric, and abdominal aortic): executive summary. *J Am Coll Cardiol* 2006; 47:1239–1312.
 12. **Jaff MR, Bates M, Sullivan T, et al; HERCULES Investigators.** Significant reduction in systolic blood pressure following renal artery stenting in patients with uncontrolled hypertension: results from the HERCULES trial. *Catheter Cardiovasc Interv* 2012; 80:343–350.
 13. **Cooper CJ, Murphy TP, Cutlip DE, et al; CORAL Investigators.** Stenting and medical therapy for atherosclerotic renal-artery stenosis. *N Engl J Med* 2014; 370:13–22.
-
- ADDRESS:** M. Chadi Alraies, MD, FACP, Department of Medicine, Cardiovascular Division, University of Minnesota Medical Center, 420 Delaware Street SE, MMC 508, Minneapolis, MN 55455; e-mail: alrai005@umn.edu