

**RENATO V. SAMALA, MD, FACP**

Staff, Center for Connected Care, Cleveland Clinic;  
Medical Director, Cleveland Clinic Hospice at Home;  
Assistant Professor of Medicine, Cleveland Clinic Lerner  
College of Medicine of Case Western Reserve University,  
Cleveland, OH

**MELLAR P. DAVIS, MD, FCCP, FAAHPM**

Professor of Medicine, Cleveland Clinic Lerner School of Medi-  
cine Case Western Reserve University, Cleveland, OH; Director,  
Clinical Fellowship Program, Palliative Medicine and Supportive  
Oncology Services, Division of Solid Tumor, Taussig Cancer  
Institute, Cleveland Clinic

# Comprehensive wound malodor management: Win the RACE

## ABSTRACT

Complex wounds that give off a foul odor are common in various patient care settings. Wound malodor has grave effects, both physical and psychological, and its management presents a serious challenge for caregivers. Multiple factors and processes involved in malodor production need to be considered in designing a comprehensive treatment plan described by the acronym RACE: **r**emoval of necrotic tissue, **a**ntibacterials, **o**dor **c**oncealers, and **e**ducation and support. Improving quality of life is the outcome of winning the RACE against malodor.

## KEY POINTS

Necrotic tissue is a substrate for bacterial growth and should be debrided. A variety of methods can be used.

Malodor is most often from infection with anaerobic organisms, which topical metronidazole and other agents can help control.

An absorbent dressing should be used either as a primary dressing, or over a layer of topical metronidazole and a nonadherent primary dressing.

Foremost in formulating a patient- and family-centered malodor management strategy is to commit to controlling it as much as possible.

**W**OUNDS THAT FAIL TO HEAL become more than mere skin lesions. Pain, malodor, and the accompanying psychological distress often complicate nonhealing wounds and impair quality of life.<sup>1</sup> Management of malodor requires perseverance, sensitivity, and familiarity with tools and procedures that range from surgical debridement to medical-grade honey.

Chronic, nonhealing wounds are defined as persisting for more than 6 months.<sup>2</sup> These lesions are incapable of undergoing anatomic and functional repair on their own. Commonly encountered nonhealing wounds include pressure ulcers, venous stasis ulcers, arterial insufficiency ulcers, and malignant cutaneous wounds.

Typically, the patient with a nonhealing wound is frail, debilitated, medically complex, and often faced with one or more life-limiting illnesses. Complete wound healing may therefore be unrealistic, and optimal wound management becomes the goal of care.<sup>3,4</sup>

Healthcare providers encounter nonhealing wounds in varied settings—acute inpatient, outpatient, long-term, and home care. For instance, in the home care setting, a study of 383 patients enrolled in hospice found that 35% had skin ulcers and wounds.<sup>3</sup> Half of those affected had pressure ulcers, 20% had ischemic ulcers, and 30% had other skin disorders such as stasis ulcers, burns, skin tears, and tumors. A larger study, also in hospice patients, found that 26% had pressure ulcers and 10% more developed them within 6 months.<sup>5</sup>

While pressure ulcers are the most common nonhealing wounds, malignant or fungating wounds are found in 5% to 10% of patients with metastatic disease, usually with cancers of the breast, head, and neck.<sup>6</sup>

Maximizing wound care provides comfort, relieves suffering, and promotes quality of life.<sup>3,7</sup> To achieve these goals, clinicians must be familiar with strategies to manage complications associated with nonhealing wounds such as pain, malodor, and psychosocial adverse effects. Of these complications, malodor has been pointed out by both patients and caregivers as the most distressing.<sup>8</sup>

This article focuses on wound malodor, discusses the processes that cause wounds to emit an offensive smell, and outlines a comprehensive management approach.

## ■ MRS. A., AGE 61, WITH STAGE IV BREAST CANCER

Mrs. A., 61 years old, had a fungating mass in her left breast, which began as a small nodule and progressively enlarged to deform her breast over several months. Her oncologist subsequently staged the extent of her cancer as stage IV after workup revealed lung metastasis. Mrs. A. and her family decided to forgo cancer treatment, including radiotherapy, and to transition to hospice care after discussions with the oncologist.

Mrs. A. lived at home with her husband. Her daughter and three grandchildren all lived nearby.

When her hospice physician arrived at her home to meet her, a strong, pungent, and nauseating smell greeted him as he entered her bedroom. The patient said that for the past few months she had been increasingly distressed by the revolting odor. She rarely left home and had been ashamed to have people visit her, including her family.

On examination, the physician noticed a large fungating mass with yellowish discharge and necrotic tissue in her left breast. In addition to mild pain, she was immensely bothered by the strong odor coming from her breast.

## ■ THE IMPACT OF MALODOR

As seen in the case of Mrs. A., malodor has grave effects, both physical and psychological. Patients experience impaired or socially unacceptable body image, social rejection, personal shame, and embarrassment.<sup>9,10</sup> Feelings of fear, anxiety, and depression are common. If left uncontrolled, malodor results in

social isolation, reluctance to engage in social activities, diminished appetite, and nausea. In addition, malodor is a constant reminder of patients' pain and cancer, and it results in further suffering.<sup>11</sup>

Reactions of family members and caregivers can worsen the situation.<sup>9,12</sup> Expressions of revulsion limit contact and inhibit intimacy, especially near the end of life. Caregivers are often frustrated and distressed over their inability to control the malodor. The environment becomes uninhabitable, and the malodor can permeate clothing, furniture, and living quarters.

Managing malodor can be emotionally draining, physically daunting, and frustrating for healthcare professionals, as several methods are usually employed, often in a trial-and-error approach, to achieve an acceptable degree of odor control. In addition, clinicians must face the challenge of treating malodorous wounds at very close distance without reacting in a way that offends or alarms patients and family members.<sup>13</sup>

## ■ MALODOR PRODUCTION: WHERE IS THAT SMELL COMING FROM?

All wounds can produce an odor.<sup>14</sup> Wounds that are expected to heal typically emit a faint but not unpleasant odor, akin to fresh blood. Wounds colonized by *Pseudomonas aeruginosa* produce a fruity or grapelike odor that is tolerable. Malodor occurs with wounds infected by other gram-negative organisms or anaerobic bacteria.<sup>15</sup> Similarly, wounds covered by necrotic tissue smell like decaying flesh.

### Three major causes

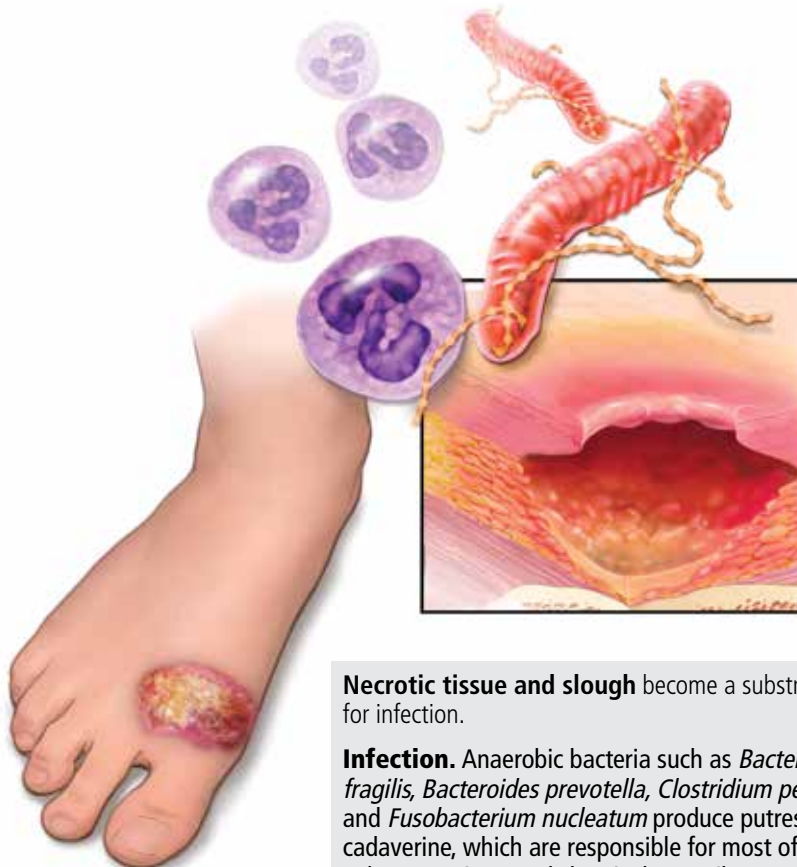
The three major causes of wound malodor are slough, infection, and exudate (**Figure 1**).

**Slough** is dead or necrotic tissue, usually resulting from vascular compromise. Arterial ulcers, pressure ulcers, and malignant wounds all form slough from capillary occlusion, subsequent ischemia, and tissue necrosis.

**Infection.** Devitalized tissue, an ideal medium in which bacteria thrive, becomes the source of infection. Anaerobic bacteria are usually implicated in malodor. These include *Bacteroides fragilis*, *Bacteroides prevotella*, *Clostridium perfringens*, and *Fusobacterium nucleatum*.<sup>16,17</sup> Anaerobic organisms produce

## Causes of wound malodor

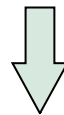
**Wounds** that can give rise to malodor include pressure ulcers, arterial ulcers, venous ulcers, and fungating tumors



**Necrotic tissue and slough** become a substrate for infection.

**Infection.** Anaerobic bacteria such as *Bacteroides fragilis*, *Bacteroides prevotella*, *Clostridium perfringens*, and *Fusobacterium nucleatum* produce putrescine and cadaverine, which are responsible for most of the odor. Other organisms and chemicals contribute.

**Exudates** accumulate in tissue that undergoes repeated cycles of inflammation, infection, and necrosis.



**Wound malodor**

CCF  
Medical Illustrator: Jeffrey Loerch ©2015

**FIGURE 1**

putrescine and cadaverine, which are largely responsible for the offensive odor.<sup>16,18</sup> Volatile fatty acids such as propionic, butyric, isovaleric, and valeric acid are formed from lipid catabolism by anaerobes and add to malodor.<sup>17</sup> Aerobic bacteria such as *Proteus*, *Klebsiella*, and *Pseudomonas* species supercolonize necrotic tissue as well and contribute to malodor.<sup>17,18</sup>

**Exudate.** Since nonhealing wounds undergo repeated cycles of inflammation, infection, and necrosis, accumulation of exudate becomes inevitable. Exudate typically is a pus-like fluid containing serum, fibrin, and white blood cells, which leak from blood vessels. In addition, bacteria that colonize chronic wounds filled with necrotic tissue activate proteases that de-

TABLE 1

## Comprehensive wound malodor management: The RACE strategy

### Removal of necrotic tissue

Cleanse and irrigate the wound with normal saline  
Autolytic debridement with hydrocolloid or hydrogel dressings

### Antibacterials, absorption

Metronidazole gel, cream, or crushed tablets  
Silver sulfadiazine; iodine-containing preparations; over-the-counter preparations containing bacitracin, neomycin, and polymyxin B; honey; yogurt; buttermilk  
Absorbent dressing with or without activated charcoal or sodium chloride

### Concealers

Scented candles, fragrant flowers and plants, air-freshener sprays, coffee beans, vanilla beans, cider vinegar, peppermint oil, oil of wintergreen  
Adsorbents (charcoal, baking soda, cat litter)

### Education and support

Commit to controlling malodor as much as possible  
Follow up regularly to check on new and existing concerns  
Address pain, bleeding, and sleep disturbance  
Provide audience-appropriate educational materials  
Anticipate and address questions and concerns about wound care  
Avoid expressing distress at odors in front of or within hearing distance of patients and families

grade and liquefy dead tissue, thereby forming extensive amounts of exudate.<sup>19</sup>

Apart from slough, infection, and exudate, poor general hygiene and dressings left on for too long may contribute to malodor.<sup>16</sup> Moisture-retentive dressings such as hydrocolloids leave an odor after removal. Dressings that liquefy upon contact with the wound surface leave a pus-like, potentially malodorous material.

### MALODOR ASSESSMENT: DO YOU SMELL SOMETHING?

Various ways to document wound malodor can prove useful in guiding assessment and treatment. Descriptions such as “foul,” “putrid,”

“fishy,” or “filled the room” vividly portray the initial presentation. A 10-point numerical scale similar to a numerical pain scale or a visual analogue scale can be used as a subjective measure.

Other grading methods, which to the authors’ knowledge are not validated, may be helpful. In a study that focused on patients suffering from malodorous gynecologic malignancies, von Gruenigen et al<sup>20</sup> used a 0-to-3 scale:

- 0 Absent
- 1 Not offensive
- 2 Offensive but tolerable
- 3 Offensive and intolerable.

A scale often adapted by other authors was devised by Baker and Haig,<sup>21</sup> which clearly defines four classes:

- 1 Strong—odor is evident upon entering the room (6 to 10 feet from the patient) with the dressing intact
- 2 Moderate—odor is evident upon entering the room with dressing removed
- 3 Slight—odor is evident at close proximity to the patient when the dressing is removed
- 4 No odor—no odor is evident, even at the patient’s bedside with the dressing removed.

### COMPREHENSIVE MANAGEMENT: HOW DO WE WIN THE ‘RACE’?

The acronym RACE outlines an approach to dealing with malodor. It stands for removal of necrotic tissue; antibacterials; odor concealers; and education and support (Table 1).

#### Remove necrotic tissue

An important step in eliminating malodor is to remove necrotic tissue. This starts with debridement, which decreases the incidence of infection and hastens wound closure.<sup>22,23</sup> Table 2 compares the different types of debridement.

**Sharp or surgical debridement** involves the use of a scalpel or scissors. This type of debridement may increase the risk of bleeding, pain, and malignant cell seeding in fungating wounds.<sup>4,24</sup>

**Enzymatic debridement** employs chemicals with proteolytic action (eg, collagenase) to digest extracellular proteins in wounds.<sup>18,25</sup>

**Mechanical debridement** involves aggressive therapies such as forceful irrigation and

TABLE 2

## Types of debridement

| Type   | Description  | Examples   | Advantages   | Disadvantages   |
|--|--|--|--|---|
| <b>Surgical</b> <sup>4,17,24,29</sup>        | Uses tools to remove nonviable tissue and debris until normal, well-vascularized tissue appears  | Scalpel<br>Forceps<br>Scissors<br>Curette  | Most rapid and precise method  | Often painful, even with local anesthetics<br>Bleeding can occur<br>Malignant cell seeding may take place in fungating wounds<br>Contraindicated in frail, older patients or in those with large wounds due to degree of trauma<br>Not recommended for arterial ulcers, which may desiccate and enlarge following debridement |
| <b>Enzymatic</b> <sup>18,25,29</sup>         | Uses chemicals that break down proteins, such as fibrin and collagen, in necrotic tissue and exudates  | Collagenase preparations   | Noninvasive  | May take several weeks to achieve desired effects<br>Burning sensation and erythema with application  |
| <b>Mechanical</b> <sup>18,26,29</sup>        | Uses mechanical force to remove necrotic tissue and debris   | Wet-to-dry dressing<br>Forceful irrigation<br>Whirlpool therapy<br>Ultrasound treatment<br>Vacuum-assisted closure | More rapid than autolytic and enzymatic debridement  | Fails to discriminate between necrotic and viable tissues<br>May be painful<br>May cause increased wound bleeding<br>May require considerable nursing time<br>May be more expensive than other types  |
| <b>Biological</b> <sup>4,24,27</sup>         | Uses organisms that ingest bacteria and devitalized tissue   | Larvae<br>Maggots  | Noninvasive<br>Maggots separate necrotic from living tissue, making surgical debridement easier  | May cause increased pain<br>Can result in increased bleeding<br>May be unacceptable aesthetically and psychologically for patients and families   |
| <b>Autolytic</b> <sup>4,15,17,24,28,29</sup> | Recommended for palliative care of chronic wounds if complete healing is not the primary goal<br><br>Uses occlusive moisture-retentive dressings that employ proteolytic enzymes and phagocytic cells present in the wound bed and wound fluid to clear devitalized tissue | Hydrocolloid dressings<br>Hydrogel preparations  | Easy<br>Inexpensive<br>Noninvasive<br>Painless<br><br>Less frequent dressing changes relative to standard or wet-to-dry dressings<br><br>Good for containing odor and low to moderate exudates | May take several weeks to achieve desired effects<br><br>Hydrocolloid dressings produce a brown, often malodorous exudate upon removal  |

Honey has been used for wound care since the era of the ancient Egyptians

hydrotherapy, which may fail to discriminate between necrotic and viable tissues.<sup>18,26</sup>

**Biological debridement** using maggots, which ingest bacteria and devitalized tissue, may cause increased wound bleeding and may be unacceptable for patients and families.<sup>24,27</sup>

**Autolytic debridement** is often recommended, particularly if complete healing is not the primary goal.<sup>17,24,28,29</sup> Autolysis uses proteolytic enzymes and phagocytic cells present in the wound bed and wound fluid to clear devitalized tissue. It is easy, inexpensive, noninvasive, and painless,<sup>4</sup> and it requires less frequent dressing changes relative to standard dressing or wet-to-dry dressing.

Autolytic debridement is commonly accomplished using hydrocolloid and hydrogel dressings.<sup>15,29</sup> Hydrocolloids are adhesive, occlusive, and conformable dressings that are suitable for wounds with low to moderate amounts of exudate. Upon contact with the wound surface, the dressing absorbs the exudate, forms a gel layer, and maintains a moist environment. Hydrocolloids are not recommended for infected wounds or for those with copious exudate as they may lead to maceration around the wound. A disadvantage of hydrocolloid dressings is their tendency to generate brown, often malodorous exudate when removed.

On the other hand, hydrogels in amorphous gel, dressing, sheet, or impregnated gauze form are water-based products that create a moist environment similar to hydrocolloids. Aside from causing minimal trauma to the wound bed when removed, the dressing's cooling effect may bring some pain relief. Hydrogels are appropriate for dry wounds and for those with minimal exudate.

After debridement, the wound is cleansed and irrigated. A number of cleansers and solutions are available, but normal saline is a cheap alternative. To irrigate, experts recommend an 18- or 20-gauge intravenous catheter attached to a 30- or 60-mL syringe.<sup>15</sup> This technique provides 8 to 15 psi of pressure, enough to cleanse the wound without causing tissue trauma.

## Antibacterials and absorption

**Antibacterials.** Topical antibiotics have several advantages over systemic antibiotics in treating chronic wounds.<sup>30,31</sup> These include a

high and sustained concentration of the antimicrobial at the site of infection, limited potential for systemic absorption and toxicity, reduced potential for antibiotic resistance, and drawing of the patient's and caregiver's attention to the wound.

**Metronidazole** is the most widely used topical antibacterial for malodor management. Its efficacy is likely due to the predominant involvement of anaerobic bacteria in foul-smelling wounds. Topical metronidazole is available as a gel and as a cream. A systematic review showed that on average, topical metronidazole was used once daily for 14 consecutive days.<sup>19</sup> The layer of topical metronidazole is typically covered with a nonadherent primary dressing followed by an absorbent secondary dressing.

The best clinical evidence for topical metronidazole consists of case reports and series.<sup>32-35</sup> The largest of these studies was done by Finlay et al, who treated 47 patients with malodorous benign and malignant cutaneous wounds with 0.75% metronidazole gel daily.<sup>32</sup> Forty-five (96%) of the patients reported significantly decreased odor by 14 days, as well as decreased pain, discharge, and surrounding cellulitis.

A randomized, placebo-controlled trial conducted by Bale et al had equivocal findings.<sup>9</sup> All 41 patients who received metronidazole gel reported a decrease in malodor within 3 days of starting it. However, 76% of patients who received placebo also reported malodor control; in the final analysis, no significant difference was noted in the success rate between the two groups.

Metronidazole tablets can be crushed and sprinkled over the wound. As with metronidazole gel or cream, the crushed tablets are applied daily and covered by a primary nonadherent dressing and an absorbent secondary dressing. This off-label use of metronidazole serves as a cheaper alternative to commercially available topical preparations. To our knowledge, there has been no head-to-head trial comparing the two topical strategies.

Systemic metronidazole, often given orally, has been recommended if evidence of deep tissue or systemic infection is noted<sup>15</sup> and in cases of fungating wounds with fistulas invading either the gastrointestinal or genitourinary tracts.<sup>18</sup> Side effects such as nausea, neuropathy,

thy, and alcohol intolerance (ie, disulfiram reaction) may occur, which are not seen with topical metronidazole.

Both topical and systemic metronidazole can be used together on a time-limited basis for extensive malodorous wounds, such as fungating malignant wounds or stage IV sacral pressure ulcers.

**Other antimicrobial agents** used to treat malodor include silver-containing products, iodine-containing topical agents, mupirocin, bacitracin, neomycin, and polymyxin B.

**Honey** was used for wound care by the ancient Egyptians, and it is still used.<sup>36</sup> Its beneficial effects include antimicrobial, debriding, deodorizing, anti-inflammatory, and granulation tissue-stimulating. Honey has even been shown to significantly decrease skin colonization with various kinds of bacteria, including methicillin-resistant *Staphylococcus aureus*.<sup>37</sup> Medical-grade honey is preferred over table honey, as the latter is nonsterile and can contain *Clostridium* spores, which contaminate the wound.<sup>38</sup>

**Yogurt and buttermilk** lower the pH of the wound and control bacterial proliferation to control malodor.<sup>39,40</sup> Either is applied for 10 to 15 minutes after the wound is cleansed and is then washed off thoroughly.

**Absorbent dressings** are used either over a layer of topical metronidazole and a nonadherent primary dressing or as a primary dressing itself. An absorbent dressing containing activated charcoal is used for rapid improvement, although cost may be prohibitive, especially in developing countries.<sup>13,19</sup> Another type of absorbent dressing, composed of polyester impregnated with sodium chloride, has been found to be useful in malodor control.<sup>41</sup> An important pointer is to maintain a tight seal around the absorbent dressing to prevent leakage of exudate.

### Concealers

Aromatics used to conceal malodor include scented candles, incense, fragrant flowers and plants, and air-freshener sprays. When circumstances allow, candles are good options since they conceal malodor by emitting fragrance, and the flame burns off foul-smelling chemicals. Aromatics such as coffee beans, vanilla beans, and cider vinegar can be placed in

a pan and left under the patient's bed or close to it. Drops of peppermint oil or oil of wintergreen can be placed on wound dressings.

Other odor concealers are adsorbent materials that attract and cause ions and molecules to adhere to their surface. Examples are charcoal, baking soda, and cat litter. As with other aromatics, these materials are placed in pans and left under the bed or near the patient.

Aromatics can have disadvantages, as certain scents, especially strong ones, can be nauseating for patients. Some fragrances trigger asthma or skin irritation. Patients and caregivers can be left with an unpleasant association of certain fragrances with malodor by conditioning.<sup>15,17,18</sup>

### Education and support

Concerns of the patient and family members need to be heard, addressed promptly, and reassessed with each visit, since uncontrolled malodor can be a chief source of caregiver fatigue.

Foremost in formulating a patient- and family-centered malodor management strategy is to commit to controlling malodor as much as possible. Regular follow-up appointments should be made, whether in the office or at home, to check on the patient's progress and address new and ongoing concerns. Symptoms accompanying malodor, such as pain, bleeding, and sleep disturbance, need to be addressed, as they all affect quality of life.<sup>1</sup> Audience-appropriate educational materials should be made available.<sup>26</sup> Online resources that patients and families can explore include the websites of the Wound Ostomy and Continence Nurses Society ([www.wocn.org](http://www.wocn.org)) and the Association for the Advancement of Wound Care ([aawconline.org](http://aawconline.org)).

Healthcare professionals need to be prepared to deal with problems and complications involving patients and family members that may arise in the course of treatment.<sup>12</sup> Problems include the cost and local unavailability of dressing supplies, insurance coverage for dressings and topical agents, lack of assistance at home, and fear of changing dressings. A cardinal rule for healthcare providers is to avoid expressing distress at odors in front of or within hearing of patients and families.

**Avoid expressing distress at odors in front of or within hearing of patients and families**

## OTHER STRATEGIES: WHAT ELSE CAN WE DO?

**Curcumin**, the main biologically active compound in the herb turmeric, applied directly to wounds three times daily as an ointment, has been shown to have odor-controlling properties.<sup>42</sup>

**Sugar paste** has been reported to control malodor by drawing out exudative and tissue fluid osmotically, and inhibiting bacterial growth.<sup>16,17</sup> Water is mixed with sugar (ie, granulated, caster, or powdered) to form a paste, with additives like glycerin and polyethylene glycol used to alter the consistency. Thick clay-like paste is good for wounds with large cavities, while thin paste is useful for wounds with small or superficial openings. The paste is applied twice daily and is covered by an absorbent dressing.

**Pressure relief** is vital in managing pressure ulcers.<sup>18,43</sup> Repositioning every 2 hours and using special devices, such as mattress overlays, alternating pressure mattresses, and low air loss mattresses, are frequently employed techniques.

If circumstances permit and when congruent with the patient's goals of care, **intra-arterial chemotherapy and radiotherapy** can be contemplated for malignant fungating wounds.<sup>44,45</sup>

**Other strategies** include opening the windows during dressing changes, increasing the frequency of dressing changes, promptly removing used dressings from the house, and ensuring good general hygiene.

## CASE RESOLUTION

After telling her that he was committed to control the malodor or, if possible, eliminate it, Mrs. A.'s doctor prepared two lists of materials—one for himself and one for Mrs. A.'s husband. He returned the next day, brought

out his supplies, asked Mrs. A. to lie in bed, and invited her husband to assist him.

He cleansed and irrigated the breast lesion with normal saline, making sure to remove as much dead tissue as he could. He applied a layer of metronidazole cream to the wound cavity, then covered it with a nonadherent dressing. He then covered the wound with gauze, sealed the edges with medical adhesive tape, and applied a few drops of oil of wintergreen to the surface. A pan of charcoal briquettes was put under the bed, and a candle with Mrs. A.'s favorite scent was lit by the bedside. The physician then instructed Mrs. A.'s husband to repeat the procedure once daily for 1 week.

After 2 weeks, Mrs. A. and her husband said the foul odor had greatly decreased. She appeared more cheerful and energetic, especially after her grandchildren visited a few days earlier. The physician then instructed the husband to stop using metronidazole cream and to apply a hydrocolloid dressing every 3 days instead. He advised them to continue the rest of the process of applying a few drops of oil of wintergreen on the dressing surface, placing a pan of charcoal briquettes under the bed, and lighting a scented candle by the bedside.

## FINISH THE RACE!

Complex nonhealing wounds are encountered across various healthcare settings. Wound malodor is an important component of nonhealing wounds, which adversely affects patients, families, and healthcare providers. Infection, slough, and exudate are the major causes of wound malodor. The essential steps to reduce malodor are to remove necrotic tissue, use antibacterial and odor-absorbing agents, apply appropriate odor "concealers," educate families, and formulate a patient- and family-centered strategy (Table 1).

**ACKNOWLEDGMENT:** The authors would like to thank Sue Reif, CNP, for her assistance in completing the manuscript.

## REFERENCES

1. Lo SF, Hayter M, Hu WY, Tai CY, Hsu MY, Li YF. Symptom burden and quality of life in patients with malignant fungating wounds. *J Adv Nurs* 2012; 68:1312–1321.
2. Lazarus GS, Cooper DM, Knighton DR, et al. Definitions and guidelines for assessment of wounds and evaluation of healing. *Arch Dermatol* 1994; 130:489–493.
3. Tippet AW. Wounds at the end of life. *Wounds* 2005; 17:91–98.
4. Burt T. Palliative care of pressure ulcers in long-term care. *Ann Long-Term Care* 2013; 21:20–28.
5. Reifsnnyder J, Magee HS. Development of pressure ulcers in patients receiving home hospice care. *Wounds* 2005; 17:74–79.
6. Haisfield-Wolfe ME, Rund C. Malignant cutaneous wounds: a management protocol. *Ostomy Wound Manage* 1997; 43:56–66.
7. O'Brien C. Malignant wounds: managing odour. *Can Fam Physician* 2012; 58:272–274.
8. Gethin G, Grocott P, Probst S, Clarke E. Current practice in the management of wound odour: an international survey. *Int J Nurs Stud* 2014; 51:865–874.
9. Bale S, Tebble N, Price P. A topical metronidazole gel used to treat

After 2 weeks, Mrs. A. and her husband said the foul odor had greatly decreased

- malodorous wounds. *Br J Nurs* 2004; 13:S4–S11.
10. **Hack A.** Malodorous wounds—taking the patient's perspective into account. *J Wound Care* 2003; 12:319–321.
11. **Price E.** Wound care. The stigma of smell. *Nurs Times* 1996; 92:71–72.
12. **Paul JC, Pieper BA.** Topical metronidazole for the treatment of wound odor: a review of the literature. *Ostomy Wound Manage* 2008; 54:18–27.
13. **Lee G, Anand SC, Rajendran S, Walker I.** Overview of current practice and future trends in the evaluation of dressings for malodorous wounds. *J Wound Care* 2006; 15:344–346.
14. **Cutting K, Harding K.** Criteria for identifying wound infection. *J Wound Care* 1994; 3:198–201.
15. **McDonald A, Lesage P.** Palliative management of pressure ulcers and malignant wounds in patients with advanced illness. *J Palliat Med* 2008; 9:285–295.
16. **Holloway S.** Recognising and treating the causes of chronic malodorous wounds. *Prof Nurse* 2004; 19:380–384.
17. **Haughton W, Young T.** Common problems in wound care: malodorous wounds. *Br J Nurs* 1995; 4:959–963.
18. **Alvarez OM, Kalinski C, Nusbaum J, et al.** Incorporating wound healing strategies to improve palliation (symptom management) in patients with chronic wounds. *J Palliat Med* 2007; 10:1161–1189.
19. **da Costa Santos CM, de Mattos Pimenta CA, Nobre MR.** A systematic review of topical treatments to control the odor of malignant fungating wounds. *J Pain Symptom Manage* 2010; 39:1065–1076.
20. **Von Gruenigen VE, Coleman RL, et al.** Bacteriology and treatment of malodorous lower reproductive tract in gynecologic cancer patients. *Obstet Gynecol* 2000; 96:23–27.
21. **Baker PG, Haig G.** Metronidazole in the treatment of chronic pressure sores and ulcers: a comparison with standard treatment in general practice. *Practitioner* 1981; 225:569–573.
22. **Whitney J, Phillips L, Aslam R, et al.** Guidelines for the treatment of pressure ulcers. *Wound Repair Regen* 2006; 14:663–679.
23. **Williams D, Enoch S, Miller D, Harris K, Price P, Harding KG.** Effect of sharp debridement using curette on recalcitrant nonhealing venous ulcers: a concurrently controlled, prospective cohort study. *Wound Repair Regen* 2005; 13:131–137.
24. **Bergstrom KJ.** Assessment and management of fungating wounds. *J Wound Ostomy Continence Nurs* 2011; 38:31–37.
25. **Sinclair RD, Ryan TJ.** Proteolytic enzymes in wound healing: the role of enzymatic debridement. *Australas J Dermatol* 1994; 35:35–41.
26. **Enoch S, Harding KG.** Wound bed preparation: the science behind the removal of barriers to healing. *Wounds* 2003; 15:213–229.
27. **Mumcuoglu KY.** Clinical applications for maggots in wound care. *Am J Clin Dermatol* 2001; 2:219–227.
28. **Langemo DK, Black J; National Pressure Ulcer Advisory Panel.** Pressure ulcers in individuals receiving palliative care: a National Pressure Ulcer Advisory Panel white paper. *Adv Skin Wound Care* 2010; 23:59–72.
29. **Fonder MA, Lazarus GS, Cowan DA, Aronson-Cook B, Kohli AR, Mamelak AJ.** Treating the chronic wound: a practical approach to the care of nonhealing wounds and wound care dressings. *J Am Acad Dermatol* 2008; 58:185–206.
30. **Lio PA, Kaye ET.** Topical antibacterial agents. *Infect Dis Clin North Am* 2004; 18:717–733.
31. **Gelmetti C.** Local antibiotics in dermatology. *Dermatol Ther* 2008; 21:187–195.
32. **Finlay IG, Bowszyc J, Ramlau C, Gwiedzinski Z.** The effect of topical 0.75% metronidazole gel on malodorous cutaneous ulcers. *J Pain Symptom Manage* 1996; 11:158–162.
33. **Bower M, Stein R, Evans TR, Hedley A, Pert P, Coombes RC.** A double-blind study of the efficacy of metronidazole gel in the treatment of malodorous fungating tumours. *Eur J Cancer* 1992; 28A:888–889.
34. **Kalinski C, Schnepf M, Laboy D, et al.** Effectiveness of a topical formulation containing metronidazole for wound odor and exudate control. *Wounds* 2005; 17:84–90.
35. **Kuge S, Tokuda Y, Ohta M, et al.** Use of metronidazole gel to control malodor in advanced and recurrent breast cancer. *Jpn J Clin Oncol* 1996; 26:207–210.
36. **Belcher J.** A review of medical-grade honey in wound care. *Br J Nurs* 2012; 21:S4–S9.
37. **Kwakman PH, Van den Akker JP, Güçlü A, et al.** Medical-grade honey kills antibiotic-resistant bacteria in vitro and eradicates skin colonization. *Clin Infect Dis* 2008; 46:1677–1682.
38. **Cooper RA, Jenkins L.** A comparison between medical grade honey and table honeys in relation to antimicrobial efficacy. *Wounds* 2009; 21:29–36.
39. **Patel B, Cox-Hayley D.** Managing wound odor #218. *J Palliat Med* 2010; 13:1286–1287.
40. **Schulte MJ.** Yogurt helps to control wound odor. *Oncol Nurs Forum* 1993; 20:1262.
41. **Upright CA, Salton C, Roberts F, Murphy J.** Evaluation of Mesalt dressings and continuous wet saline dressings in ulcerating metastatic skin lesions. *Cancer Nurs* 1994; 17:149–155.
42. **Kuttan R, Sudheeran PC, Joseph CD.** Turmeric and curcumin as topical agents in cancer therapy. *Tumori* 1987; 73:29–31.
43. **Bass MJ, Phillips LG.** Pressure sores. *Curr Probl Surg* 2007; 44:101–143.
44. **Bufill JA, Grace WR, Neff R.** Intra-arterial chemotherapy for palliation of fungating breast cancer: a case report and review of the literature. *Am J Clin Oncol* 1994; 17:118–124.
45. **Murakami M, Kuroda Y, Sano A, et al.** Validity of local treatment including intraarterial infusion chemotherapy and radiotherapy for fungating adenocarcinoma of the breast: case report of more than 8-year survival. *Am J Clin Oncol* 2001; 24:388–391.

ADDRESS: Renato V. Samala, MD, FACP, Center for Connected Care, S31, Cleveland Clinic, 9500 Euclid Avenue, Cleveland, OH 44195; e-mail: samalar@ccf.org