



**LEARNING OBJECTIVE:** Readers will assess the possible causes of acute monocular vision loss

**JUSTIN R. ABBATEMARCO, MD**  
Neurology Resident, Cleveland Clinic

**RUSHAD PATELL, MD**  
Internal Medicine Resident,  
Cleveland Clinic

**JANET BUCCOLA, MD**  
Department of Hospital Medicine,  
Medicine Institute, Cleveland Clinic;  
Clinical Assistant Professor, Cleveland Clinic  
Lerner College of Medicine of Case Western  
Reserve University, Cleveland, OH

**MARY ALISSA WILLIS, MD**  
Mellen Center for Multiple Sclerosis  
Treatment and Research, Neurological  
Institute, Cleveland Clinic; Assistant  
Professor, Cleveland Clinic Lerner College of  
Medicine of Case Western Reserve University,  
Cleveland, OH

# Acute monocular vision loss: Don't lose sight of the differential

**A**N 83-YEAR-OLD man presented to the emergency department with acute, painless loss of vision in his left eye. His vision in that eye had been normal in the middle of the night when he woke to use the restroom, but on awakening 6 hours later he could perceive only light or darkness.

He denied headache, scalp tenderness, jaw claudication, fever, weight loss, myalgia, or other neurologic symptoms. He had not experienced any recent change in his vision before this presentation, including halos around lights, floaters, eye pain, or redness. However, 6 months ago he had undergone left cataract surgery (left phacoemulsification with intraocular implant) without complications. And he said that when he was 3 years old, he had sustained a serious injury to his right eye.

His medical history included ischemic heart disease and hypertension. His medications included losartan, furosemide, amlodipine, atorvastatin, and aspirin.

## CAUSES OF ACUTE MONOCULAR VISION LOSS

**1** Which of the following is the *least* likely cause of this patient's acute monocular vision loss?

- Optic neuritis
- Retinal vein occlusion
- Retinal artery occlusion
- Pituitary apoplexy
- Retinal detachment

Acute vision loss is often so distressing to the patient that the emergency department may be the first step in evaluation. While its diagnosis and management often require an inter-

disciplinary effort, early evaluation and triage of this potential medical emergency is often done by clinicians without specialized training in ophthalmology.

The physiology of vision is complex and the list of possible causes of vision loss is long, but the differential diagnosis can be narrowed quickly by considering the time course of vision loss and the anatomic localization.<sup>1</sup>

**The time course** (including onset and tempo) of vision loss can be classified as:

- Transient (ie, vision returned to normal by the time seen by clinician)
- Acute (instantaneous onset, ie, within seconds to minutes)
- Subacute (progression over days to weeks)
- Chronic (insidious progression over months to years).

Although acute vision loss is usually dramatic, insidious vision loss may occasionally be unnoticed for a surprisingly long time until the normal eye is inadvertently shielded.

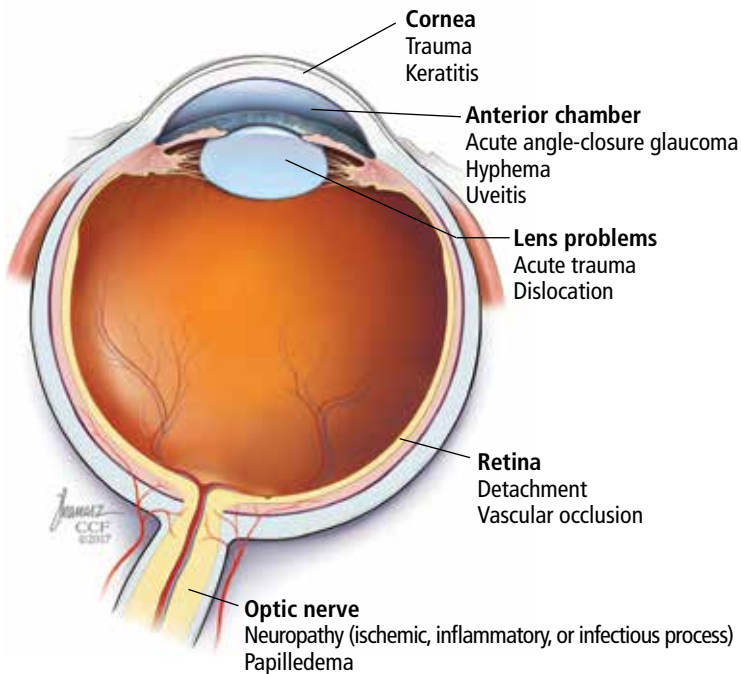
**Anatomic localization.** Lesions anterior to the optic chiasm cause monocular vision loss, whereas lesions at or posterior to the chiasm lead to bilateral visual field defects. Problems leading to monocular blindness can be broadly divided into 3 anatomic categories (**Figure 1**):

- Ocular medial (including the cornea, anterior chamber, and lens)
- Retinal
- Neurologic (including the optic nerve and chiasm).

## Clues from the history

A careful ophthalmic history is an essential initial step in the evaluation (**Table 1**). In addition, nonvisual symptoms can help narrow the differential diagnosis.

**He woke up that morning and could not see out of his left eye; 6 hours earlier it had been normal**



**FIGURE 1.** Common causes of monocular vision loss can arise in the media (cornea, anterior chamber, or lens), retina, or optic nerve.

**Insidious vision loss may be unnoticed for a surprisingly long time until the normal eye is inadvertently shielded**

Nausea and vomiting often accompany acute elevation of intraocular pressure.

Focal neurologic deficits or other neurologic symptoms can point to a demyelinating disease such as multiple sclerosis.

Risk factors for vascular atherosclerotic disease such as diabetes, hypertension, and coronary artery disease raise concern for retinal, optic nerve, or cerebral ischemia.

Medications with anticholinergic and adrenergic properties can also precipitate monocular vision loss with acute angle-closure glaucoma.

### Can we rule out anything yet?

Our patient presented with painless monocular vision loss. As discussed, causes of monocular vision loss can be localized to ocular abnormalities and prechiasmatic neurologic ones. Retinal detachment, occlusion of a retinal artery or vein, and optic neuritis are all important potential causes of acute monocular vision loss.

Pituitary apoplexy, on the other hand, is characterized by an acute increase in pituitary volume, often leading to compression of the optic chiasm resulting in a visual-field defect. It is most often characterized by binocular def-

icits (eg, bitemporal hemianopia) but is less likely to cause monocular vision loss.<sup>1</sup>

### ■ CASE CONTINUED: EXAMINATION

On examination, the patient appeared comfortable. His temperature was 97.6°F (36.4°C), pulse 59 beats per minute, respiratory rate 18 per minute, and blood pressure 153/56 mm Hg.

**Heart and lung examinations** were notable for a grade 3 of 6 midsystolic, low-pitched murmur in the aortic area radiating to the neck, bilateral carotid bruits, and clear lungs. The cardiac impulse was normal in location and character. There was no evidence of aortic insufficiency (including auscultation during exhalation phase while sitting upright).

**Eye examination.** Visual acuity in the right eye was 20/200 with correction (owing to his eye injury at age 3). With the left eye, he could see only light or darkness. The conjunctiva and sclera were normal.

The right pupil was irregular and measured 3 mm (baseline from his previous eye injury). The left pupil was 3.5 mm. The direct pupillary response was preserved, but a relative afferent pupillary defect was present: on the swinging flashlight test, the left pupil dilated when the flashlight was passed from the right to the left pupil. Extraocular movements were full and intact bilaterally. The rest of the neurologic examination was normal.

An ophthalmologist was urgently consulted. A dilated fundoscopic examination of the left eye revealed peripapillary atrophy, tortuous vessels, a cherry red macular spot, and flame hemorrhages, but no disc edema or pallor (**Figure 2**).

### ■ FURTHER WORKUP

**2** Which of the following investigations would be *least* useful and not indicated at this point for this patient?

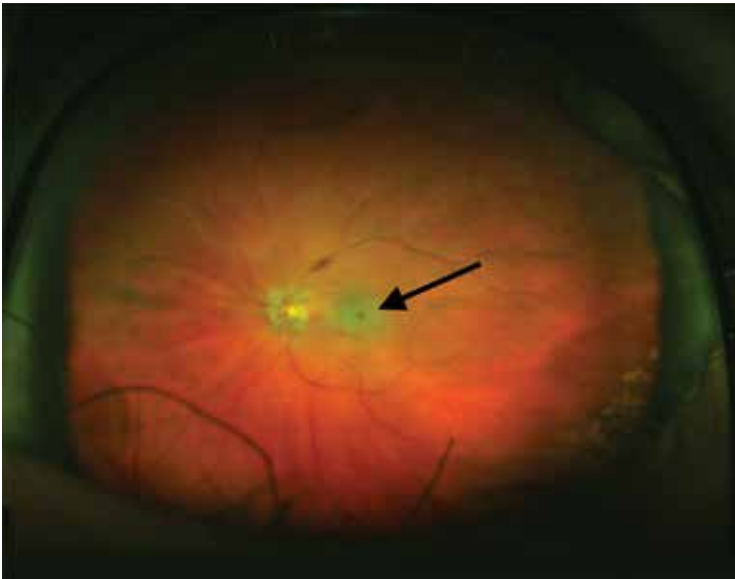
- Carotid ultrasonography
- Electrocardiography and echocardiography
- Magnetic resonance angiography of the brain
- Computed tomographic (CT) angiography of the head and neck
- Testing for the factor V Leiden and prothrombin gene mutations

TABLE 1

**Acute monocular vision loss: Diagnostic clues from the history**

Feature	Common conditions	Additional features
<b>Eye pain</b>	<b>Acute angle-closure glaucoma</b>	Age > 60 and family history Deep brow, headache with nausea and vomiting Halos around lights
	<b>Optic neuritis</b>	Pain worsens with eye movements Loss of color vision (red desaturation)
	<b>Keratitis</b> (inflammation of the cornea)	Sharp superficial pain ("grittiness") Discharge from the eye
<b>Conjunctival hyperemia</b> (red eye)	<b>Acute angle-closure glaucoma</b>	See above
	<b>Keratitis</b>	See above
	<b>Uveitis</b>	Redness prominent at limbus (convergence between cornea and sclera) Photophobia Systemic features suggesting autoimmune disease
<b>Headache</b>	<b>Giant cell arteritis</b>	Age > 50 Scalp tenderness (new onset, temporally based headache) Jaw claudication Proximal muscle pain
	<b>Migraine</b>	Younger patients Preceded by migraine prodrome Symptoms resolve within hour
<b>Photopsia</b> (flashes of bright light)	<b>Retinal detachment</b>	Myopia Recent history of ophthalmic procedures Partial loss of peripheral field
<b>Preceding trauma</b>	<b>Keratitis or uveitis</b>	Accompanying milder trauma
	<b>HypHEMA</b> (blood in the anterior chamber)	History of blunt trauma Recent history of ophthalmic procedures
	<b>Lens dislocation or rupture</b>	Predisposed by congenital conditions Associated small, irregular pupil

Information from references 2 and 3.



**FIGURE 2.** The patient’s funduscopy examination revealed a cherry red spot (arrow), a characteristic finding in central retinal artery occlusion.

**Central retinal artery occlusion can be either nonarteritic or arteritic**

A systematic ocular physical examination can offer important diagnostic information (Table 2). Ophthalmoscopy directly examines the optic disc, macula, and retinal vasculature. To interpret the funduscopy examination, we need a basic understanding of the vascular supply to the eye (Figure 3).

For example, the cherry red spot within the macula in our patient is characteristic of central retinal artery occlusion and highlights the relationship between anatomy and pathophysiology. The retina’s blood supply is compromised, leading to an ischemic, white background (secondary to edema of the inner third of the retina), but the macula continues to be nourished by the posterior ciliary arteries. This contrast in color is accentuated by the underlying structures composing the fovea, which lacks the nerve fiber layer and ganglion cell layer, making the vascular bed more visible.<sup>2,3</sup>

Also in our patient, the marked reduction in visual acuity and relative afferent pupillary defect in the left eye point to unilateral optic nerve (or retinal ganglion cell) dysfunction. The findings on direct funduscopy were consistent with acute central retinal artery ischemia or occlusion. Central retinal artery occlusion can be either arteritic (due to inflammation, most often giant cell arte-

ritis) or nonarteritic (due to atherosclerotic vascular disease).

Thus, carotid ultrasonography, electrocardiography, and transthoracic and transesophageal echocardiography are important components of the further workup. In addition, urgent brain imaging including either CT angiography or magnetic resonance angiography of the head and neck is indicated in all patients with central retinal artery occlusion.

Thrombophilia testing, including tests for the factor V Leiden and prothrombin gene mutations, is indicated in specific cases when a hypercoagulable state is suggested by components of the history, physical examination, and laboratory and radiologic testing. Thrombophilia testing would be low-yield and should not be part of the first-line testing in elderly patients with several atherosclerotic risk factors, such as our patient.

**■ CASE CONTINUED: LABORATORY AND IMAGING EVIDENCE**

Initial laboratory work showed:

- Mild microcytic anemia
- Erythrocyte sedimentation rate 77 mm/hour (reference range 1–10)
- C-reactive protein 4.0 mg/dL (reference range < 0.9).

The rest of the complete blood cell count and metabolic profile were unremarkable. His hemoglobin A<sub>1c</sub> value was 5.3% (reference range 4.8%–6.2%).

A neurologist was urgently consulted.

Magnetic resonance imaging of the brain without contrast revealed nonspecific white-matter disease with no evidence of ischemic stroke.

Magnetic resonance angiography of the head and neck with contrast demonstrated 20% to 40% stenosis in both carotid arteries with otherwise patent anterior and posterior circulation.

Continuous monitoring of the left carotid artery with transcranial Doppler ultrasonography was also ordered, and the study concluded there were no undetected microembolic events.

Transthoracic echocardiography showed

TABLE 2

**Key physical examination features in monocular vision loss**

Physical examination	Helpful techniques	Results
<b>Visual acuity</b>	Vision screening apps (eg, EyeChart Vision Screening App by Dok LLC) Use corrective lens or pinhole occluder	Pinhole test corrects refractory error by permitting central rays of light into the eye; will not correct underlying neurologic impairment
<b>Visual field</b>	Monocular assessment Confrontation visual field testing uses small-amplitude finger movements in all quadrants Central fields tested by Amsler grid	<b>Scotoma:</b> discrete area of visual impairment surrounded by intact vision; positive scotoma (seeing something that is not there) may be a sign of retinal damage; negative scotoma may indicate optic nerve dysfunction <b>Hemianopia:</b> bilateral visual impairment suggesting a lesion posterior to optic chiasm
<b>Color testing</b>	Use red objects (sharps container or bottle cap)	Unilateral color desaturation: optic nerve dysfunction
<b>Pupillary examination</b>	Examine for size, shape, symmetry Swinging flashlight examination: paradoxical dilation when stimulating ipsilateral eye after shining light into contralateral eye	Afferent pupillary defect: optic nerve dysfunction
<b>Red reflex</b>	Performed with ophthalmoscope when standing 1 foot away from patient	Loss of reflex: localizes to media and possibly retinal detachment
<b>Direct ophthalmoscopy</b>	Use dilating drops to enhance the examination Disc: neuroretinal fibers entering the eye Macula: located temporally to disc and lacking blood vessels	Cherry red macula: ischemic retina from central retinal artery occlusion that contrasts with nourished macula supplied by posterior ciliary arteries Hollenhorst plaque: cholesterol emboli signifies atherosclerotic disease in carotid or aortic arch Pale and swollen optic nerve head: ischemic optic neuropathy from posterior ciliary artery obstruction

Information from references 2 and 3.

aortic sclerosis with no other abnormalities.

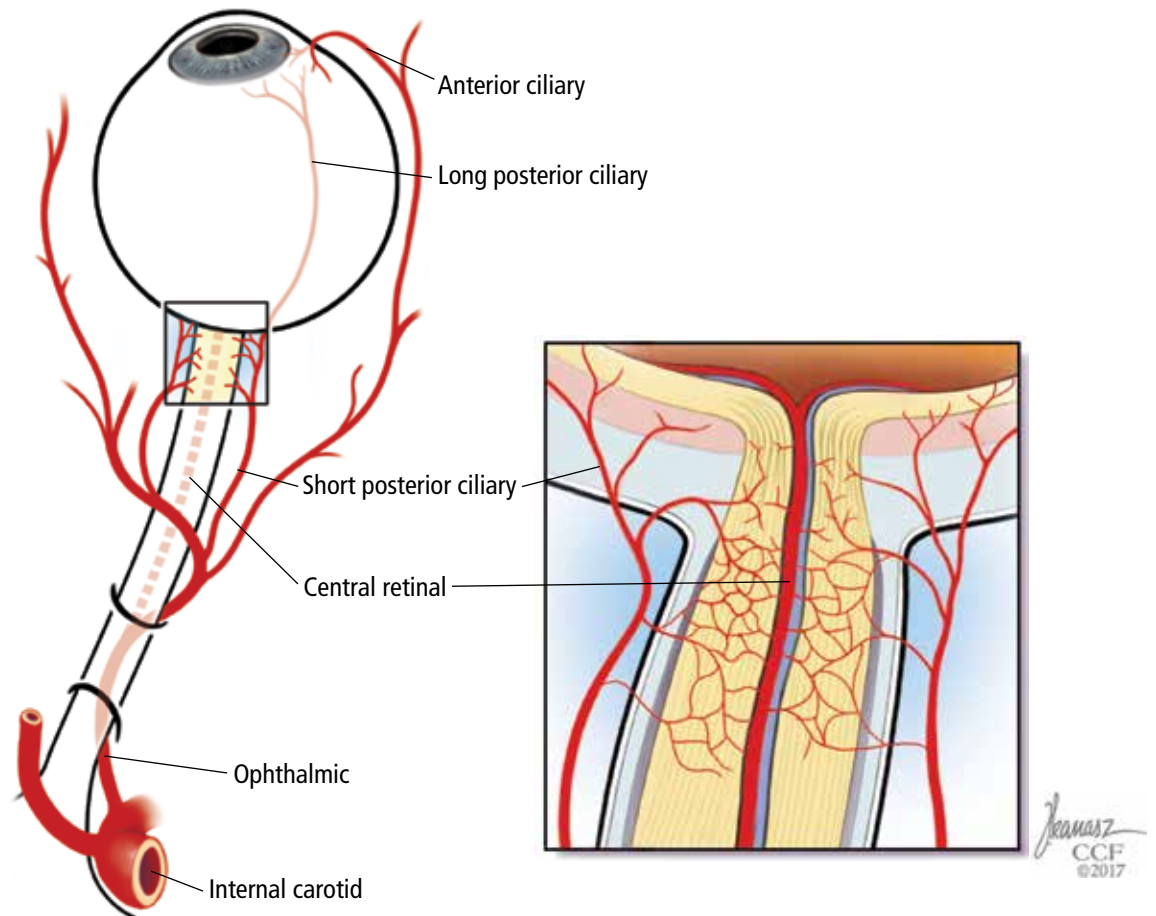
Ophthalmic fluorescein angiography was performed and showed patchy choroidal hypoperfusion, severe delayed filling, and extensive pruning of the arterial circulation with no involvement of the posterior ciliary arteries.

Given the elevated inflammatory markers, pulse-dose intravenous methylprednisolone was started, and a temporal artery biopsy was planned.

**CENTRAL RETINAL ARTERY OCCLUSION: NONARTERITIC VS ARTERITIC CAUSES**

**3** Which of the following is least useful to differentiate arteritic from nonarteritic causes of central retinal artery occlusion?

- Finding emboli in the retinal vasculature on funduscopy
- Temporal artery biopsy
- Measuring the C-reactive protein level



**FIGURE 3.** Vascular supply to the eye. The internal carotid artery's first major branch is the ophthalmic artery. Four major vessels break off from the ophthalmic artery:

- Central retinal artery:** large-diameter vessel that supplies the retina (vulnerable to embolic disease)
- Short and long posterior ciliary arteries:** small vessels that supply the optic nerve and macula (susceptible to small-vessel disease)
- Anterior ciliary arteries** supply the iris and ciliary body.

Information from references 4 and 5.

- and the erythrocyte sedimentation rate
- Echocardiography
- Positron-emission tomography (PET)
- Retinal fluorescein angiography

In patients diagnosed with central retinal artery occlusion, the next step is to differentiate between nonarteritic and arteritic causes, since separating them has therapeutic relevance.

The carotid artery is the main culprit for embolic disease affecting the central retinal artery, leading to the nonarteritic subtype. Thus, evaluation of acute retinal ischemia secondary

to nonarteritic central retinal artery occlusion is similar to the evaluation of patients with an acute cerebral stroke.<sup>4</sup> Studies have shown that 25% of patients diagnosed with central retinal artery occlusion have an additional ischemic insult in the cerebrovascular system, and these patients are at high risk of recurrent ocular or cerebral infarction. Workup includes diffusion-weighted MRI, angiography, echocardiography, and telemetry.<sup>5</sup>

Arteritic central retinal artery occlusion is most often caused by giant cell arteritis. The

American College of Rheumatology classification criteria for giant cell arteritis include 3 of the following 5:

- Age 50 or older
- New onset of localized headache
- Temporal artery tenderness or decreased temporal artery pulse
- Erythrocyte sedimentation rate 50 mm/hour or greater
- Positive biopsy findings.<sup>6</sup>

**Temporal artery biopsy** is the gold standard for the diagnosis of giant cell arteritis and should be done whenever the disease is suspected.<sup>7,8</sup> However, the test is invasive and imperfect, as a negative result does not completely rule out giant cell arteritis.<sup>9</sup>

Although a unilateral temporal artery biopsy can be falsely negative, several studies evaluating the efficacy of bilateral biopsies did not show significant improvement in the diagnostic yield.<sup>10,11</sup>

**Ophthalmic fluorescein angiography** is another helpful test for distinguishing nonarteritic from arteritic central retinal artery occlusion.<sup>12</sup> Involvement of the posterior ciliary arteries usually occurs in giant cell arteritis, and this leads to choroidal malperfusion with or without retinal involvement. The optic nerve may also be infarcted by closure of the paraoptic vessels fed by the posterior ciliary vessels.<sup>12,13</sup> Such involvement of multiple vessels would not be typical with nonarteritic central retinal artery occlusion. Thus, this finding is helpful in making the final diagnosis along with supplying possible prognostic information.<sup>13</sup>

**PET-CT** is emerging as a test for early inflammation in extracranial disease, but its utility for diagnosing intracranial disease is limited by high uptake of the tracer fluorodeoxyglucose by the brain and low resolution.<sup>14</sup> Currently, it has no established role in the evaluation of patients with central retinal artery occlusion and would have no utility in differentiating arteritic vs nonarteritic causes of central retinal artery occlusion.

If giant cell arteritis is suspected, it is essential to start intravenous pulse-dose methylprednisolone early to prevent further vision loss in the contralateral eye. Treatment should not be delayed for invasive testing or temporal artery biopsy. Improvement in headache, jaw

claudication, or scalp tenderness once steroids are initiated also helps support the diagnosis of giant cell arteritis.<sup>7</sup>

Unfortunately, visual symptoms may be irreversible despite treatment.

**Our patient’s central retinal artery occlusion**

This case highlights how difficult it is in practice to distinguish nonarteritic from arteritic central retinal artery occlusion.

Our patient had numerous cardiovascular risk factors, including known carotid and coronary artery disease, favoring a nonarteritic diagnosis.

On the other hand, his elevated inflammatory markers suggested an underlying inflammatory response. He lacked the characteristic headache and other systemic signs of giant cell arteritis, but this has been described in about 25% of patients.<sup>15</sup> If emboli are seen on funduscopy, further workup for arteritic central retinal artery occlusion is not warranted, but emboli are not always present. Then again, absence of posterior ciliary artery involvement on fluorescein angiography pointed away from giant cell arteritis.

■ **CASE CONTINUED: FINAL DIAGNOSIS**

Biopsy of the left temporal artery showed intimal thickening with focal destruction of the internal elastic lamina by dystrophic calcification with no evidence of inflammatory infiltrates, giant cells, or granulomata in the adventitia, media, or intima. Based on the results of biopsy study and fluorescein angiography, we concluded that this was nonarteritic central retinal artery occlusion related to atherosclerotic disease.

Methylprednisolone was discontinued. The patient was discharged on aspirin, losartan, furosemide, amlodipine, and high-dose atorvastatin for standard stroke prevention. He was followed by the medical team and the ophthalmology department. At 6 weeks, there was only marginal improvement in the visual acuity of the left eye.

■ **MANAGEMENT**

**4** Management of nonarteritic central retinal artery occlusion could include all of the following except which one?

**If giant cell arteritis is suspected, it is essential to start intravenous pulse-dose methylprednisolone early**

- Ocular massage
- Intravenous thrombolysis
- Intra-arterial thrombolysis
- Risk-factor modification
- Intraocular steroid injection

In patients with acute vision loss from nonarteritic central retinal artery occlusion, acute strategies to restore retinal perfusion include noninvasive “standard” therapies and thrombolysis (intravenous or intra-arterial). Unfortunately, consensus and guidelines are lacking.

**Traditional therapies** include sublingual isosorbide dinitrate, systemic pentoxifylline, inhalation of a carbogen, hyperbaric oxygen, ocular massage, intravenous acetazolamide and mannitol, anterior chamber paracentesis, and systemic steroids. However, none of these have been shown to be more effective than placebo.<sup>16</sup>

**Thrombolytic therapy**, analogous to the treatment of patients with ischemic stroke or myocardial infarction, is more controversial in acute central retinal artery occlusion.<sup>13</sup> Data from small case-series suggested that intra-arterial or intravenous thrombolysis might improve visual acuity with reasonable safety.<sup>17</sup> On the other hand, a randomized study from the United Kingdom that compared intra-arterial thrombolysis within a 24-hour window and conservative measures concluded that thrombolysis should not be used.<sup>18</sup>

Thrombolysis is thus used only in selected patients on a case-specific basis with involvement of a multispecialty team including stroke neurologists, especially if patients present within hours of onset and have concomitant neurologic symptoms.

Treatment beyond the acute phase focuses on preventing complications of the eye ischemia and aggressively managing systemic atherosclerotic risk factors to decrease the incidence of further ischemic events. Other interventions include endarterectomy for significant carotid stenosis and anticoagulation to prevent cardioembolic embolization (such as atrial fibrillation). Most experts agree on the addition of an antiplatelet agent.<sup>13,19</sup>

**Intraocular steroid injection** can be used in the management of some retinal disorders

but has no value in nonarteritic central retinal artery occlusion.

Vision recovery in nonarteritic central retinal artery occlusion is variable, but the prognosis is generally poor. The visual acuity on presentation, the onset of the symptoms, and collateral vessels are major factors influencing long-term recovery. Most of the recovery occurs within 7 days and involves peripheral vision rather than central vision. Several studies report some recovery in peripheral vision in approximately 30% to 35% of affected eyes.<sup>20–22</sup>

### ■ PROMPT ACTION MAY SAVE SIGHT

Vision loss is a common presenting symptom in the emergency setting. A meticulous history and systematic physical examination can narrow the differential diagnosis of this neuro-ophthalmologic emergency. Acute retinal ischemia from central retinal artery occlusion is the ocular equivalent of an ischemic stroke, and they share risk factors, diagnostic workup, and management approaches.

Both etiologic subtypes (ie, arteritic and nonarteritic) require prompt intervention by front-line physicians. If giant cell arteritis is suspected, corticosteroid therapy must be initiated to save the contralateral retina from ischemia. Suspicion of central retinal artery occlusion warrants immediate evaluation by a neurologist to consider thrombolysis. Prompt action and interdisciplinary care involving an ophthalmologist, neurologist, and emergency or internal medicine physician may save a patient from permanent visual disability.

### ■ KEY POINTS

- Monocular vision loss requires urgent evaluation with a multidisciplinary management approach.
- There are no consensus treatment guidelines for nonarteritic central retinal artery occlusion, but the workup includes a comprehensive stroke evaluation.
- Arteritic central retinal artery occlusion is most often due to giant cell arteritis, and when it is suspected, the patient should be empirically treated with steroids. ■

Suspicion of central retinal artery occlusion warrants immediate evaluation by a neurologist



REFERENCES

1. Glezer A, Bronstein MD. Pituitary apoplexy: pathophysiology, diagnosis and management. *Arch Endocrinol Metab* 2015; 59:259–264.
2. Campbell WW. *DeJong's The Neurologic Examination*. 7th ed. Philadelphia: Lippincott Williams & Wilkins, 2013.
3. Biller J. *Practical Neurology*. 4th ed. Philadelphia: Lippincott Williams & Wilkins, 2012.
4. Hayreh SS, Podhajsky PA, Zimmerman MB. Retinal artery occlusion: associated systemic and ophthalmic abnormalities. *Ophthalmology* 2009; 116:1928–1936.
5. Biousse V. Acute retinal arterial ischemia: an emergency often ignored. *Am J Ophthalmol* 2014; 157:1119–1121.
6. Hunder GG, Bloch DA, Michel BA, et al. American College of Rheumatology 1990 criteria for the classification of giant cell arteritis. *Arthritis Rheum* 1990; 33:1122–1128.
7. Smith JH, Swanson JW. Giant cell arteritis. *Headache* 2014; 54:1273–1289.
8. Hall S, Persellin S, Lie JT, O'Brien PC, Kurland LT, Hunder GG. The therapeutic impact of temporal artery biopsy. *Lancet* 1983; 2:1217–1220.
9. Gabriel SE, O'Fallon WM, Achkar AA, Lie JT, Hunder GG. The use of clinical characteristics to predict the results of temporal artery biopsy among patients with suspected giant cell arteritis. *J Rheumatol* 1995; 22:93–96.
10. Boyev LR, Miller NR, Green WR. Efficacy of unilateral versus bilateral temporal artery biopsies for the diagnosis of giant cell arteritis. *Am J Ophthalmol* 1999; 128:211–215.
11. Danesh-Meyer HV, Savino PJ, Eagle RC Jr, Kubis KC, Sergott RC. Low diagnostic yield with second biopsies in suspected giant cell arteritis. *J Neuroophthalmol* 2000; 20:213–215.
12. Cavallerano AA. Ophthalmic fluorescein angiography. *Optom Clin* 1996; 5:1–23.
13. Hayreh SS. Acute retinal arterial occlusive disorders. *Prog Retin Eye Res* 2011; 30:359–394.
14. Khan A, Dasgupta B. Imaging in giant cell arteritis. *Curr Rheumatol Rep* 2015; 17:52.
15. Biousse V, Newman N. Retinal and optic nerve ischemia. *Continuum (Minneapolis)* 2014; 20:838–856.
16. Fraser SG, Adams W. Interventions for acute non-arteritic central retinal artery occlusion. *Cochrane Database Syst Rev* 2009; 1:CD001989.
17. Beatty S, Au Eong KG. Local intra-arterial fibrinolysis for acute occlusion of the central retinal artery: a meta-analysis of the published data. *Br J Ophthalmol* 2000; 84:914–916.
18. Schumacher M, Schmidt D, Jurklics B, et al; EAGLE-Study Group. Central retinal artery occlusion: local intra-arterial fibrinolysis versus conservative treatment, a multicenter randomized trial. *Ophthalmology* 2010; 117:1367–1375.e1.
19. Antithrombotic Trialists' Collaboration. Collaborative meta-analysis of randomised trials of antiplatelet therapy for prevention of death, myocardial infarction, and stroke in high risk patients. *BMJ* 2002; 324:71–86.
20. Hayreh SS, Zimmerman MB. Central retinal artery occlusion: visual outcome. *Am J Ophthalmol* 2005; 140:376–391.
21. Augsburger JJ, Magargal LE. Visual prognosis following treatment of acute central retinal artery obstruction. *Br J Ophthalmol* 1980; 64:913–917.
22. Brown GC, Shields JA. Cilioretinal arteries and retinal arterial occlusion. *Arch Ophthalmol* 1979; 97:84–92.

---

ADDRESS: Mary Alissa Willis, MD, Mellen Center for Multiple Sclerosis, U10, Cleveland Clinic, 9500 Euclid Avenue, Cleveland, OH 44195; [Willism@ccf.org](mailto:Willism@ccf.org)