

YU LI, MD

Department of Emergency and Critical Care Medicine, Tokyo Bay Urayasu Ichikawa Medical Center, Chiba, Japan

HIRAKU FUNAKOSHI, MD, MPH, PhD

Department of Emergency and Critical Care Medicine, Tokyo Bay Urayasu Ichikawa Medical Center, Chiba, Japan

TAKASHI SHIGA, MD, MPH

Department of Emergency and Critical Care Medicine, Tokyo Bay Urayasu Ichikawa Medical Center, Chiba, Japan

SHIGEKI FUJITANI, MD, PhD

Department of Emergency and Critical Care Medicine, Tokyo Bay Urayasu Ichikawa Medical Center, Chiba, Japan

Iliopsoas abscess

A 52-YEAR-OLD WOMAN with diabetes mellitus presented with a 1-month history of pain in the right lower abdomen and right back. Although she had a fever when the pain started and her pain was aggravated by walking, her pain and fever had gotten better after taking antibiotics prescribed earlier.

On physical examination, a tender mass with slight warmth was felt in the right lower quadrant. Laboratory testing revealed an active inflammatory reaction: the white blood cell count was $54.8 \times 10^9/L$ (reference range 4.5–11.0), and the C-reactive protein level was 35.40 mg/dL (reference range < 0.9). Computed tomography showed an abscess in the iliopsoas muscle (**Figures 1 and 2**), with no evidence of pyogenic spondylitis or other vertebral involvement.

The patient was admitted to the hospital for percutaneous drainage, which produced 26 mL of pus on the first day and 320 mL on the next day; culture was positive for *Escherichia coli*. Urine culture was also positive for *E coli*; blood culture was not. We concluded that these results were secondary to pyelonephritis.

We started intravenous piperacillin-tazobactam 2.25 g every 8 hours for empiric therapy. We changed this to oral ampicillin-cloxacillin 2 g/day after *E coli* was cultured and pyelonephritis was suspected. The patient was discharged after a 2-week hospital stay, with no significant complications.

ILIOPSOAS ABSCESS: DIAGNOSTIC CLUES

Iliopsoas abscess can occur at any age.^{1–3} Pain is the most common symptom, occurring in more than 90% of patients.¹ Fever with temperatures over 38°C is less common at first, found in less than half of patients.^{1,2}

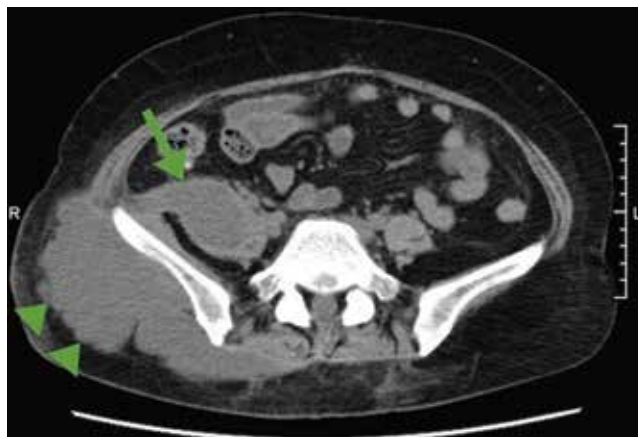


FIGURE 1. Computed tomography (horizontal plane) showed a low-density area 7 × 4 cm in the right psoas muscle (arrow) and a low-density area 16 × 6 cm in subcutaneous tissue connected to the psoas muscle (arrowheads).

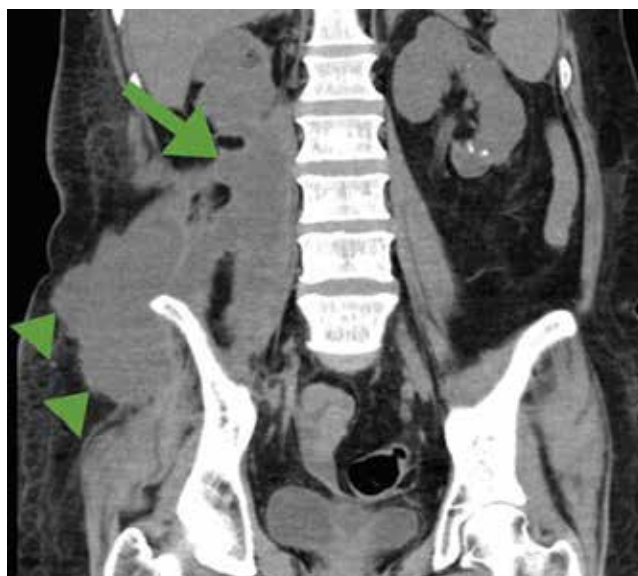

FIGURE 2. Computed tomography (coronal section) showed a low-density area 16 × 4 cm in the right psoas muscle (arrow), and a low-density area 11 × 7 cm in subcutaneous tissue connected to the psoas muscle (arrowheads).

Only 13% of patients with iliopsoas abscess may have a palpable mass on physical examination.¹ The psoas sign—a worsening of lower abdominal pain on the affected side with passive extension of the thigh while supine—has a sensitivity of only 24% for iliopsoas abscess; it can also indicate inflammation to the iliopsoas muscle in other conditions such as retrocecal appendicitis.³

Hip flexion deformity can be a helpful diagnostic feature, as 96% of patients with iliopsoas abscess hold the hip in flexion to relieve pain.⁴ But pain on hip flexion can also occur in conditions such as septic arthritis.⁴

Inflammatory markers such as erythrocyte sedimentation rate and C-reactive protein may be elevated in all patients with iliopsoas abscess, so if those markers are not elevated, we may have to consider other conditions such as cancer.¹ Computed tomography is nearly 100% sensitive for iliopsoas abscess and is the gold standard for diagnosis.³

TREATMENT

Inadequate treatment of iliopsoas abscess raises the risk of relapse and death.³ Drainage and appropriate antibiotic therapy have been shown to be effective.^{1,3}

Iliopsoas abscess can also be secondary to a number of conditions, eg, Crohn disease, appendicitis, intra-abdominal infection, and cancer,⁵ and the primary condition needs to be addressed. In addition, culture of a secondary abscess is more likely to grow mixed organisms.⁵

The average size of the abscess is 6 cm. Percutaneous drainage is required if the mass is larger than 3.5 cm.¹

TAKE-HOME MESSAGES

Iliopsoas abscess is difficult to diagnose because patients have few specific complaints. Checking for hip flexion deformity and inflammatory markers may help rule out the disease. When iliopsoas abscess is suspected, computed tomography is necessary to confirm the diagnosis. Drainage and appropriate antibiotics are effective treatment. ■

REFERENCES

1. Tabrizian P, Nguyen SQ, Greenstein A, Rajbeharrysingh U, Divino CM. Management and treatment of iliopsoas abscess. *Arch Surg* 2009; 144:946–949.
2. Shields D, Robinson P, Crowley TP. Iliopsoas abscess—a review and update on the literature. *Int J Surg* 2012; 10:466–469.
3. Huang JJ, Ruaan MK, Lan RR, Wang MC. Acute pyogenic iliopsoas abscess in Taiwan: clinical features, diagnosis, treatments and out-

come. *J Infect* 2000; 40:248–255.

4. Stefanich RJ, Moskowitz A. Hip flexion deformity secondary to acute pyogenic psoas abscess. *Orthop Rev* 1987; 16:67–77.
5. Ricci MA, Rose FB, Meyer KK. Pyogenic psoas abscess: worldwide variations in etiology. *World J Surg* 1986; 10:834–843.

ADDRESS: Yu Li, MD, Department of Emergency and Critical Care Medicine, Tokyo Bay Urayasu Ichikawa Medical Center, 3-4-32, Todaijima Urayasu, Chiba, Japan; kiaksoinkooy@gmail.com