



LEARNING OBJECTIVE: Readers will consider the differential diagnosis of shock in patients known to have cirrhosis

HOURIYA AYOUBIEH, MD
Assistant Professor, Department of
Hospital Medicine, University of New
Mexico, Albuquerque

EYAS ALKHALILI, MD
Department of Surgery, The Johns
Hopkins Hospital, Baltimore, MD

Another complication of cirrhosis

A 53-YEAR-OLD Native American woman with a history of liver cirrhosis secondary to alcohol abuse presents to the emergency department after 2 days of diffuse abdominal pain and weakness. The pain was sudden in onset and has progressed relentlessly over the last day, reaching 9 on a scale of 10 in severity. Family members say that her oral intake has been decreased for the last 2 days, but she has had no fever, vomiting, change in bowel habit, blood in stool, or black stool. She has never undergone surgery, and has had one uncomplicated pregnancy.

Physical examination

Vital signs:

- Blood pressure 82/57 mm Hg
- Heart rate 96 beats per minute
- Temperature 37.3°C (99.1°F)
- Respiratory rate 16 per minute
- Oxygen saturation 92% while receiving oxygen at 2 L/minute.

The patient is somnolent and has scleral icterus. Her cardiopulmonary examination is normal. Her abdomen is tense, distended, and diffusely tender. She has bilateral +2 pitting edema in her lower extremities. She is oriented to person only and is noted to have asterixis. Her baseline Model for End-stage Liver Disease score is 18 points on a scale of 6 (less ill) to 40 (gravely ill).

Laboratory studies:

- Hemoglobin 9.8 g/dL (reference range 11.5–15.5)
- Platelet count $100 \times 10^9/L$ (150–400)
- White blood cell count $9.9 \times 10^9/L$ (3.7–11.0)
- Serum creatinine 1.06 mg/dL (0.58–0.96)
- Bilirubin 6.3 mg/dL (0.2–1.3)
- International normalized ratio of the prothrombin time 2.15 (0.8–1.2)

- Blood urea nitrogen 13 mg/dL (7–21)
- Serum albumin 2.7 g/dL (3.9–4.9).

Intravenous fluid resuscitation is initiated but the patient remains hypotensive, and on repeat laboratory testing 4 hours later her hemoglobin level has dropped to 7.3 mg/dL.

DIFFERENTIAL DIAGNOSIS

1 Which of the following are likely causes of this patient's presentation?

- Splenic arterial aneurysm rupture
- Spontaneous bacterial peritonitis
- Variceal hemorrhage
- Portal vein thrombosis
- Abdominal aortic aneurysm rupture

Ruptured splenic artery aneurysm

Splenic artery aneurysms are the third most common intra-abdominal aneurysm, after those of the abdominal aorta and iliac artery.¹ They are often asymptomatic and are being detected more frequently because of increased use of computed tomography (CT).² Symptomatic splenic artery aneurysms may present with abdominal pain and have the potential to rupture, which can be life-threatening.^{3,4}

This patient may have a ruptured splenic artery aneurysm, given her hemodynamic shock.

Spontaneous bacterial peritonitis

Ten percent to 20% of hospitalized patients with cirrhosis and ascites develop spontaneous bacterial peritonitis. Patients may present with ascites and abdominal pain, tenderness to palpation, fever, encephalopathy, or worsening liver and renal function.

Diagnostic paracentesis is paramount to delineate the cause of ascites; one should calculate the serum-ascites albumin gradient and obtain a cell count and culture of the as-

A patient with cirrhosis presents with acute abdominal pain and shock—what is the cause?

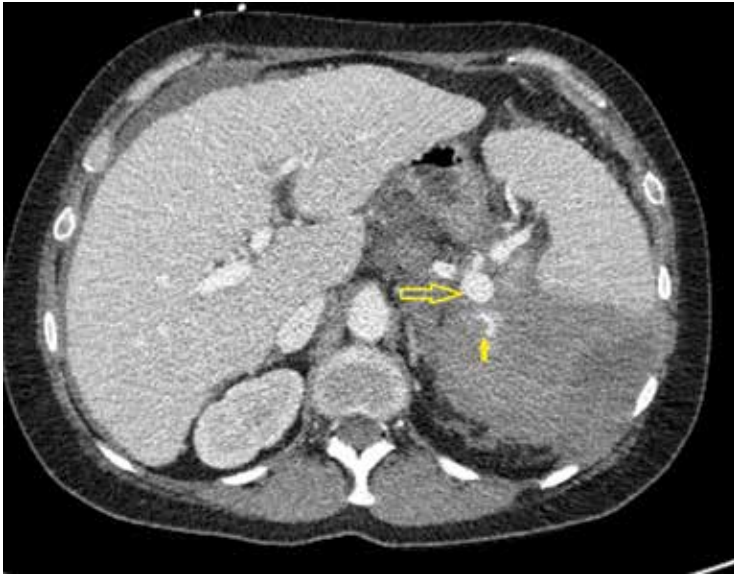

FIGURE 1. Computed tomography of the abdomen demonstrates splenic aneurysm (large arrow) with active extravasation of contrast (small arrow).

10%–20% of hospitalized patients with cirrhosis and ascites develop spontaneous bacterial peritonitis

citic fluid. The diagnosis of spontaneous bacterial peritonitis can be made if the ascitic fluid polymorphonuclear cell count is $0.25 \times 10^9/L$ or higher, even if the ascitic fluid culture is negative.^{5,6} Simultaneous blood cultures should also be collected, as 50% of cases are associated with bacteremia.

The in-hospital mortality rate of an episode of spontaneous bacterial peritonitis has been reduced to 10% to 20% thanks to prompt diagnosis and empiric treatment with third-generation cephalosporins.⁷

Five percent of cases of infected ascites fluid are due to secondary bacterial peritonitis from a perforated viscus or a loculated abscess, which cannot be differentiated clinically from spontaneous bacterial peritonitis but can be diagnosed with CT.⁸

This patient may be presenting with septic shock secondary to either of these causes.

Variceal hemorrhage

Half of patients with cirrhosis have gastroesophageal varices due to portal hypertension. Endoscopic surveillance is warranted, as the risk of hemorrhage is 12% to 15% per year, and the mortality rate approaches 15% to 20% with each episode. Prompt resuscitation, diagnosis, and control of bleeding is paramount.

Esophagogastroduodenoscopy is used for both diagnosis and intervention. Short-term prophylactic use of antibiotics improves survival by preventing infections in the event bleeding recurs.^{9–11}

Our patient may be presenting with hemodynamic shock from bleeding esophageal varices.

Portal vein thrombosis

Portal vein thrombosis is a common complication of cirrhosis, occurring in 5% to 28% of patients. The risk increases with the severity of liver disease and in association with hepatocellular carcinoma.¹² Forty-three percent of cases are discovered incidentally in asymptomatic patients during ultrasonography, 39% present with upper gastrointestinal bleeding, and 18% present with abdominal pain.^{13,14}

Portal vein thrombosis is the complete or partial obstruction of blood flow due to a thrombus in the lumen of the portal vein. Contrast ultrasonography and CT can be used to establish the diagnosis.¹⁵

Anticoagulation is recommended in cases of complete thrombosis in candidates for living-donor liver transplant and for those at risk of mesenteric ischemia because of the thrombus extending into the mesenteric veins. In symptomatic patients, the decision to initiate anticoagulation should be made on a case-by-case basis after appropriate screening and management of varices.^{16–18}

Our patient's thrombocytopenia reflects the severity of portal hypertension and increases her risk of portal vein thrombosis, but this is unlikely to be the sole cause of the hemodynamic compromise in this patient.

Ruptured abdominal aortic aneurysm

Rupture of an abdominal aortic aneurysm is a medical emergency, with a mortality rate approaching 90%. Risk factors for abdominal aortic aneurysms are smoking, male sex, age over 65, history of cardiovascular disease, hypertension, and a family history of abdominal aortic aneurysm, especially if a first-degree relative is affected.¹⁹ Endovascular repair is associated with lower rates of death and complications compared with open repair.²⁰

The patient does not have any of those risk factors, making this diagnosis less likely.

**■ CASE CONTINUED:
RUPTURED SPLENIC ARTERY ANEURYSM**

Emergency CT of the abdomen and pelvis with contrast enhancement shows a large left intraperitoneal hematoma with active extravasation from a ruptured splenic artery aneurysm (Figure 1). The patient receives packed red blood cells and fresh-frozen plasma before being transferred to our hospital.

2 Which of the following is *false* regarding splenic artery aneurysms?

- They are the most common type of splanchnic arterial aneurysm
- True aneurysms are more common than pseudoaneurysms
- Asymptomatic aneurysms are discovered incidentally during assessment for other radiographic indications
- Splenic artery aneurysm in portal hypertension is the result of atherosclerotic changes to the vascular intima

Splenic artery aneurysm in portal hypertension is not the result of atherosclerotic change to the vascular intima.

Splenic artery aneurysms are the most common type of splanchnic artery aneurysm.¹ True aneurysms involve all 3 layers of the arterial wall, ie, intima, media, and adventitia. Cirrhosis and portal hypertension are associated with true aneurysm formation. The proposed mechanism of aneurysm formation is increased splenic blood flow in response to portal congestion with resultant hemodynamic stress that disrupts arterial wall structure, leading to aneurysmal dilation.²¹

In earlier reports, the incidence of true splenic artery aneurysm in portal hypertension varied from 2.9% to 50%, the latter representing autopsy findings of small aneurysms that were found in the splenic hilum of patients with cirrhosis.²²⁻²⁵ The incidence of clinically significant aneurysms in cirrhosis is unknown but incidental asymptomatic aneurysm is being detected more frequently on imaging studies pursued for screening purposes.²⁶

The risk of rupture is low, only 2% to 10% in older studies and likely even lower now due to increased incidental detection in asymptomatic patients.²⁷ However, emergent man-

agement of rupture at a tertiary care facility is paramount, as the mortality rate of ruptured splenic artery aneurysm is 29% to 36%.^{1,26,28}

Splenic artery pseudoaneurysm is rarer and has a different pathophysiologic process than true aneurysm. It usually arises in the setting of trauma, pancreatitis, or postsurgery.^{29,30} Pseudoaneurysm is more likely to rupture, owing to compromise in the vascular wall integrity.^{4,21,28} As a result, treatment is indicated for every pseudoaneurysm regardless of size.

■ RISK FACTORS FOR SPLENIC ARTERY ANEURYSM

3 Which of the following is true regarding our patient's risk of splenic artery aneurysm?

- Liver cirrhosis and portal hypertension are her greatest risk factors for it
- Female sex and prior pregnancy are her greatest risk factors for it
- Being Native American makes it more likely that the patient has splenic artery aneurysm secondary to collagen vascular disease
- Her risk of rupture would diminish after receiving a liver transplant

Liver cirrhosis and portal hypertension are her greatest risk factors for splenic artery aneurysm.

Risk factors for true aneurysm include hypertension, atherosclerosis, portal hypertension with or without liver cirrhosis, liver transplant, third trimester of pregnancy, and multiparity.^{1,4,26,28,31} Splenic artery aneurysm is usually diagnosed in the sixth decade. It may be 4 times as common in women, given a hormonal influence.³² Cirrhosis is also associated with massive splenic artery aneurysm (≥ 5 cm). Although rare, massive splenic artery aneurysm is more frequent in men (the male-to-female ratio is 1.78:1) and has a heightened risk of rupture.²⁸ The incidence of rupture increases to around 3% to 4% after liver transplant.³³ Rare causes of true aneurysm include fibrodysplasia, collagen vascular disease (eg, Loeys-Dietz and type IV Ehler-Danlos syndromes), vasculitis (eg, polyarteritis nodosa due to amphetamine abuse), and mycotic aneurysms.^{24,25,28,29}

This patient's age, sex, and history of cir-

Half of patients with cirrhosis have gastroesophageal varices due to portal hypertension

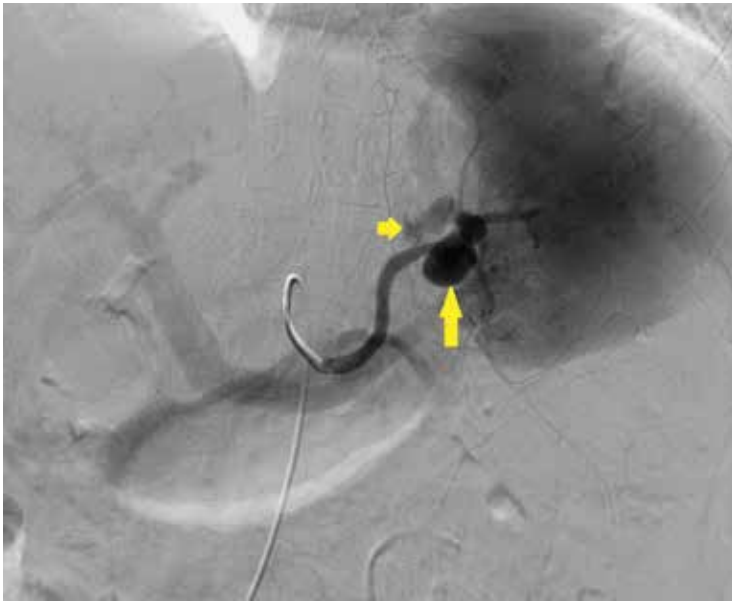

FIGURE 2. Angiography before treatment demonstrates splenic aneurysm (large arrow) with extravasation (small arrow).

Although splenic artery aneurysm rupture is rare, it has a high mortality rate and warrants a high index of suspicion

rhosis puts her at increased risk of splenic artery aneurysm. The risk of rupture is highest in the peripartum period and in patients with cirrhosis who become pregnant. Although being Native American portends an increased risk for collagen vascular disease, the latter is unlikely to be a contributing factor.

■ TREATMENT OF SPLENIC ARTERY ANEURYSM

4 Which of the following is *false* regarding treatment of splenic artery aneurysms?

- Aneurysms larger than 2 cm and those that are expanding require repair
- Treatment should be offered if the patient has symptoms attributable to the aneurysm
- Asymptomatic aneurysms in pregnant women can be followed with watchful waiting
- Minimally invasive therapies such as percutaneous embolization may be a good option in poor operative candidates

Asymptomatic aneurysms in pregnant women should not be followed with watchful waiting—they should be repaired, as rupture carries a maternal mortality rate of 75% and a fetal mortality rate of 95%.³⁴

Complications of splenic artery aneurysm depend on the type of aneurysm and its predisposing factors. Indications for treatment of true aneurysms include:

- Symptoms attributable to the aneurysm (hence, the second answer choice above is true)
- Diameter 2 cm or greater or enlarging diameter (hence, the first answer choice is true)
- Women of childbearing age in anticipation of pregnancy
- Need for surgical intervention such as portocaval shunt and liver transplant.

Conservative management is associated with a late mortality risk of 4.9%.² Interventional options include percutaneous embolization or stenting; or laparotomy with splenic artery ligation or excision with or without splenectomy.^{1,28,35–37}

Endovascular and open surgical repair have both been used to treat splenic artery aneurysms. The method used depends on the patient’s surgical history and aneurysm anatomy such as splenic artery tortuosity hindering passage of a catheter. Open surgery is associated with longer intraoperative time and length of hospital stay and higher rates of 30-day mortality and perioperative morbidity.^{38–41} With endovascular repair, the complication of persistent or recurrent flow occurs in 3% to 5% of cases by 30 days; hence, postprocedural surveillance is recommended.^{42–44} Endovascular repair has a higher reintervention rate but may still be more cost-effective than open surgical repair.

Because patients with cirrhosis have a higher risk of surgical complications,⁴⁵ elective endovascular treatment may be an option for patients with aneurysms at high risk of rupturing. Endovascular treatment of visceral aneurysms is associated with complications such as postembolization syndrome (fever, abdominal pain, pleural effusion, and pancreatitis), access site hematoma, splenic infarction, and persistent abdominal pain.⁴²

Patients with cirrhosis as the cause of splenic artery aneurysm tend to need longer hospitalization after endovascular treatment, but there is insufficient evidence to suggest that they are at higher risk of other complications.³⁷

**■ CASE CONTINUED:
SPLENIC ARTERY EMBOLIZATION**

The patient undergoes emergency splenic artery embolization, performed by an interventional radiology team (Figure 2 and Figure 3). Over the next few days, her mental status improves and her abdominal pain resolves. Her hemoglobin level remains stable after the procedure.

She is discharged home on day 5 but comes back 5 days later with recurrent abdominal pain. CT of the abdomen and pelvis with contrast shows a hematoma and hemoperitoneum with bleeding originating near the previously embolized splenic artery aneurysm and splenic infarction.

The surgical and interventional radiology teams discuss the risk of repeat intervention with the patient and her family, who prefer a nonoperative approach. She is managed supportively in the intensive care unit and is finally discharged home in stable condition and is scheduled for outpatient follow-up.

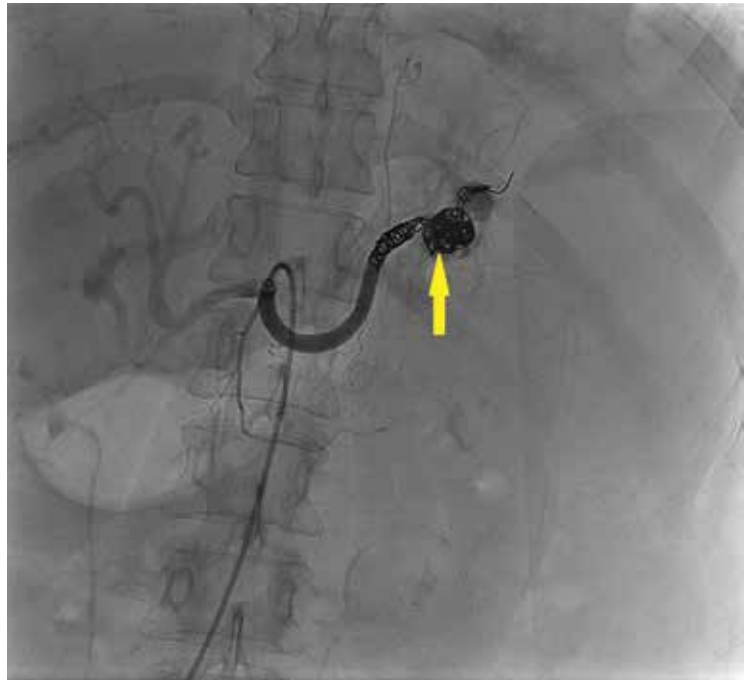


FIGURE 3. Angiography after embolization demonstrates coils in the embolized aneurysm without extravasation.

■ SUSPECT THIS FATAL CONDITION

The low prevalence of ruptured splenic artery aneurysm may lead physicians to attribute septic shock to spontaneous bacterial peritonitis or hemorrhagic shock from gastroesophageal varices in patients with cirrhosis, but a high index of suspicion and early recognition of this rare disease can lead to timely diagnosis and treatment of this highly fatal complication.

■ KEY POINTS

- Splenic artery aneurysm is a common complication of cirrhosis, often diagnosed incidentally.

■ REFERENCES

1. Bakhos CT, McIntosh BC, Nukta FA, et al. Staged arterial embolization and surgical resection of a giant splenic artery aneurysm. *Ann Vasc Surg* 2007; 21:208–210.
2. Hogendoorn W, Lavida A, Hunink MG, et al. Open repair, endovascular repair, and conservative management of true splenic artery aneurysms. *J Vasc Surg* 2014; 60:1667–1676.e1.
3. Algodkar A. Unruptured splenic artery aneurysm presenting as epigastric pain. *JRSM Short Rep* 2010; 1:24.
4. Abbas MA, Stone WM, Fowl RJ, et al. Splenic artery aneurysms: two decades experience at Mayo Clinic. *Ann Vasc Surg* 2002; 16:442–449.
5. Hoefs JC, Canawati HN, Sapico FL, Hopkins RR, Weiner J, Montgomery JZ. Spontaneous bacterial peritonitis. *Hepatology* 1982; 2:399–407.

- Elective embolization should be considered for asymptomatic splenic artery aneurysms larger than 2 cm in diameter, clinically symptomatic aneurysms, women of childbearing age, and patients who are candidates for liver transplant.
- Although splenic artery aneurysm rupture is rare, it has a high mortality rate and warrants a high index of suspicion to institute prompt specialized intervention.
- We recommend that physicians consider splenic artery aneurysm rupture in their differential diagnoses in patients with liver cirrhosis presenting with abdominal pain, altered mental status, and hemodynamic shock.

Flow persists or recurs in 3%–5% of cases by 30 days after endovascular repair

6. Runyon BA, Hoefs JC. Culture-negative neutrocytic ascites: a variant of spontaneous bacterial peritonitis. *Hepatology* 1984; 4:1209–1211.
7. Garcia-Tsao G. Spontaneous bacterial peritonitis: a historical perspective. *J Hepatol* 2004; 41:522–527.
8. Soriano G, Castellote J, Alvarez C, et al. Secondary bacterial peritonitis in cirrhosis: a retrospective study of clinical and analytical characteristics, diagnosis and management. *J Hepatol* 2010; 52:39–44.
9. D’Amico G, De Franchis R; Cooperative Study Group. Upper digestive bleeding in cirrhosis. Post-therapeutic outcome and prognostic indicators. *Hepatology* 2003; 38:599–612.
10. Garcia-Tsao G, Sanyal AJ, Grace ND, Carey WD; Practice Guidelines Committee of American Association for Study of Liver Diseases;

- Practice Parameters Committee of American College of Gastroenterology.** Prevention and management of gastroesophageal varices and variceal hemorrhage in cirrhosis. *Am J Gastroenterol* 2007; 102:2086–2102.
11. **Garcia-Tsao G, Sanyal AJ, Grace ND, Carey W; Practice Guidelines Committee of the American Association for the Study of Liver Diseases; Practice Parameters Committee of the American College of Gastroenterology.** Prevention and management of gastroesophageal varices and variceal hemorrhage in cirrhosis. *Hepatology* 2007; 46:922–938.
 12. **Tsochatzis EA, Senzolo M, Germani G, Gatt A, Burroughs AK.** Systematic review: portal vein thrombosis in cirrhosis. *Aliment Pharmacol Ther* 2010; 31:366–374.
 13. **Kobori L, van der Kolk MJ, de Jong KP, et al.** Splenic artery aneurysms in liver transplant patients. *Liver Transplant Group. J Hepatol* 1997; 27:890–893.
 14. **Manzano-Robleda Mdel C, Barranco-Fragoso B, Uribe M, Mendez-Sanchez N.** Portal vein thrombosis: what is new? *Ann Hepatol* 2015; 14:20–27.
 15. **Sarin SK, Philips CA, Kamath PS, et al.** Toward a comprehensive new classification of portal vein thrombosis in patients with cirrhosis. *Gastroenterology* 2016; 151:574–577.e3.
 16. **DeLeve LD, Valla DC, Garcia-Tsao G; American Association for the Study of Liver Diseases.** Vascular disorders of the liver. *Hepatology* 2009; 49:1729–1764.
 17. **Manzanet G, Sanjuan F, Orbis P, et al.** Liver transplantation in patients with portal vein thrombosis. *Liver Transpl* 2001; 7:125–131.
 18. **John BV, Konjeti R, Aggarwal A, et al.** Impact of untreated portal vein thrombosis on pre and post liver transplant outcomes in cirrhosis. *Ann Hepatol* 2013; 12:952–958.
 19. **Hirsch AT, Haskal ZJ, Hertzner NR, et al; American Association for Vascular Surgery/Society for Vascular Surgery; Society for Cardiovascular Angiography and Interventions; Society for Vascular Medicine and Biology; Society of Interventional Radiology; ACC/AHA Task Force on Practice Guidelines.** ACC/AHA Guidelines for the Management of Patients with Peripheral Arterial Disease (lower extremity, renal, mesenteric, and abdominal aortic): a collaborative report from the American Associations for Vascular Surgery/Society for Vascular Surgery, Society for Cardiovascular Angiography and Interventions, Society for Vascular Medicine and Biology, Society of Interventional Radiology, and the ACC/AHA Task Force on Practice Guidelines (writing committee to develop guidelines for the management of patients with peripheral arterial disease)—summary of recommendations. *J Vasc Interv Radiol* 2006; 17:1383–1397.
 20. **Schermerhorn ML, O'Malley AJ, Jhaveri A, Cotterill P, Pomposelli F, Landon BE.** Endovascular vs open repair of abdominal aortic aneurysms in the Medicare population. *N Engl J Med* 2008; 358:464–474.
 21. **Ohta M, Hashizume M, Ueno K, Tanoue K, Sugimachi K, Hasuo K.** Hemodynamic study of splenic artery aneurysm in portal hypertension. *Hepatogastroenterology* 1994; 41:181–184.
 22. **Sunagozaka H, Tsuji H, Mizukoshi E, et al.** The development and clinical features of splenic aneurysm associated with liver cirrhosis. *Liver Int* 2006; 26:291–297.
 23. **Manenti F, Williams R.** Injection studies of the splenic vasculature in portal hypertension. *Gut* 1966; 7:175–180.
 24. **Stanley JC, Fry WJ.** Pathogenesis and clinical significance of splenic artery aneurysms. *Surgery* 1974; 76:898–909.
 25. **Lee PC, Rhee RY, Gordon RY, Fung JJ, Webster MW.** Management of splenic artery aneurysms: the significance of portal and essential hypertension. *J Am Coll Surg* 1999; 189:483–490.
 26. **Al-Habbal Y, Christophi C, Muralidharan V.** Aneurysms of the splenic artery—a review. *Surgeon* 2010; 8:223–231.
 27. **Mattar SG, Lumsden AB.** The management of splenic artery aneurysms: experience with 23 cases. *Am J Surg* 1995; 169:580–584.
 28. **Akbulut S, Otan E.** Management of giant splenic artery aneurysm: comprehensive literature review. *Medicine (Baltimore)* 2015; 94:e1016.
 29. **Agrawal GA, Johnson PT, Fishman EK.** Splenic artery aneurysms and pseudoaneurysms: clinical distinctions and CT appearances. *AJR Am J Roentgenol* 2007; 188:992–999.
 30. **Tessier DJ, Stone WM, Fowl RJ, et al.** Clinical features and management of splenic artery pseudoaneurysm: case series and cumulative review of literature. *J Vasc Surg* 2003; 38:969–974.
 31. **Dave SP, Reis ED, Hossain A, Taub PJ, Kerstein MD, Hollier LH.** Splenic artery aneurysm in the 1990s. *Ann Vasc Surg* 2000; 14:223–229.
 32. **Parrish J, Maxwell C, Beecroft JR.** Splenic artery aneurysm in pregnancy. *J Obstet Gynaecol Can* 2015; 37:816–818.
 33. **Moon DB, Lee SG, Hwang S, et al.** Characteristics and management of splenic artery aneurysms in adult living donor liver transplant recipients. *Liver Transpl* 2009; 15:1535–1541.
 34. **Sadat U, Dar O, Walsh S, Varty K.** Splenic artery aneurysms in pregnancy—a systematic review. *Int J Surg* 2008; 6:261–265.
 35. **Geoghegan T, McAuley G, Snow A, Torreggiani WC.** Emergency embolization of multiple splenic artery pseudoaneurysms associated with portal hypertension complicating cystic fibrosis. *Australas Radiol* 2007; 51(suppl):B337–B339.
 36. **Jiang R, Ding X, Jian W, Jiang J, Hu S, Zhang Z.** Combined endovascular embolization and open surgery for splenic artery aneurysm with arteriovenous fistula. *Ann Vasc Surg* 2016; 30:311.e1–311.e4.
 37. **Naganuma M, Matsui H, Koizumi J, Fushimi K, Yasunaga H.** Short-term outcomes following elective transcatheter arterial embolization for splenic artery aneurysms: data from a nationwide administrative database. *Acta Radiol Open* 2015; 4:2047981615574354.
 38. **Batagini NC, El-Arousy H, Clair DG, Kirksey L.** Open versus endovascular treatment of visceral artery aneurysms and pseudoaneurysms. *Ann Vasc Surg* 2016; 35:1–8.
 39. **Marone EM, Mascia D, Kahlberg A, Brioschi C, Tshomba Y, Chiesa R.** Is open repair still the gold standard in visceral artery aneurysm management? *Ann Vasc Surg* 2011; 25:936–946.
 40. **Sticco A, Aggarwal A, Shapiro M, Pratt A, Rissuci D, D'Ayala M.** A comparison of open and endovascular treatment strategies for the management of splenic artery aneurysms. *Vascular* 2016; 24:487–491.
 41. **Hogendoorn W, Lavida A, Hunink MG, et al.** Cost-effectiveness of endovascular repair, open repair, and conservative management of splenic artery aneurysms. *J Vasc Surg* 2015; 61:1432–1440.
 42. **Fankhauser GT, Stone WM, Naidu SG, et al; Mayo Vascular Research Center Consortium.** The minimally invasive management of visceral artery aneurysms and pseudoaneurysms. *J Vasc Surg* 2011; 53:966–970.
 43. **Lagana D, Carrafiello G, Mangini M, et al.** Multimodal approach to endovascular treatment of visceral artery aneurysms and pseudoaneurysms. *Eur J Radiol* 2006; 59:104–111.
 44. **Guillon R, Garcier JM, Abergel A, et al.** Management of splenic artery aneurysms and false aneurysms with endovascular treatment in 12 patients. *Cardiovasc Intervent Radiol* 2003; 26:256–260.
 45. **Northup PG, Wanamaker RC, Lee VD, Adams RB, Berg CL.** Model for end-stage liver disease (MELD) predicts nontransplant surgical mortality in patients with cirrhosis. *Ann Surg* 2005; 242:244–251.

ADDRESS: Houriya Ayoubieh, MD, Assistant Professor, Department of Hospital Medicine, University of New Mexico, 915 Camino De Salud NE, MSC10 5550, 1 University of New Mexico, Albuquerque, NM 87131; h.ayoubieh@gmail.com