



**LEARNING OBJECTIVE:** Readers will recognize the current indications for endoscopic submucosal dissection in the evaluation and treatment of patients with early gastrointestinal neoplasms

**LADY KATHERINE MEJÍA-PÉREZ, MD**  
Department of Internal Medicine, Cleveland Clinic

**SEIICHIRO ABE, MD**  
Endoscopy Division, National Cancer Center Hospital, Tokyo, Japan

**TYLER STEVENS, MD**  
Department of Gastroenterology and Hepatology, Digestive Disease Institute, Cleveland Clinic; Associate Professor, Cleveland Clinic Lerner College of Medicine of Case Western Reserve University, Cleveland, OH

**MANSOUR A. PARSI, MD**  
Department of Gastroenterology and Hepatology, Digestive Disease Institute, Cleveland Clinic

**SUNGUK N. JANG, MD**  
Department of Gastroenterology and Hepatology, Digestive Disease Institute, Cleveland Clinic

**ICHIRO ODA, MD**  
Endoscopy Division, National Cancer Center Hospital, Tokyo, Japan

**JOHN J. VARGO, MD, MPH**  
Chairman, Department of Gastroenterology and Hepatology, Digestive Disease Institute, Cleveland Clinic; Associate Professor, Cleveland Clinic Lerner College of Medicine of Case Western Reserve University, Cleveland, OH

**YUTAKA SAITO, MD, PhD**  
Endoscopy Division, National Cancer Center Hospital, Tokyo, Japan

**AMIT BHATT, MD**  
Department of Gastroenterology and Hepatology, Digestive Disease Institute, Cleveland Clinic; Clinical Assistant Professor, Cleveland Clinic Lerner College of Medicine of Case Western Reserve University, Cleveland, OH

# A minimally invasive treatment for early GI cancers

## ABSTRACT

Endoscopic submucosal dissection (ESD) allows curative resection of early malignant gastrointestinal (GI) lesions, potentially avoiding open surgery. Unfortunately, awareness of this technique is low, and many patients undergo surgery without consideration of ESD. This article reviews the indications for ESD and its advantages and limitations, and guides internists in their approach to patients with early GI cancer.

## KEY POINTS

ESD is a minimally invasive endoscopic technique with curative potential for patients with superficial GI neoplasia.

ESD preserves the integrity of the organ while achieving curative resection of large neoplasms.

ESD is indicated rather than surgery in patients with early GI lesions with a negligible risk of lymph node metastasis.

Complications of the procedure include bleeding, perforation, and stenosis. Most of these respond to endoscopic treatment.

Successful ESD requires supportive teamwork among internists, gastroenterologists, pathologists, and surgeons.

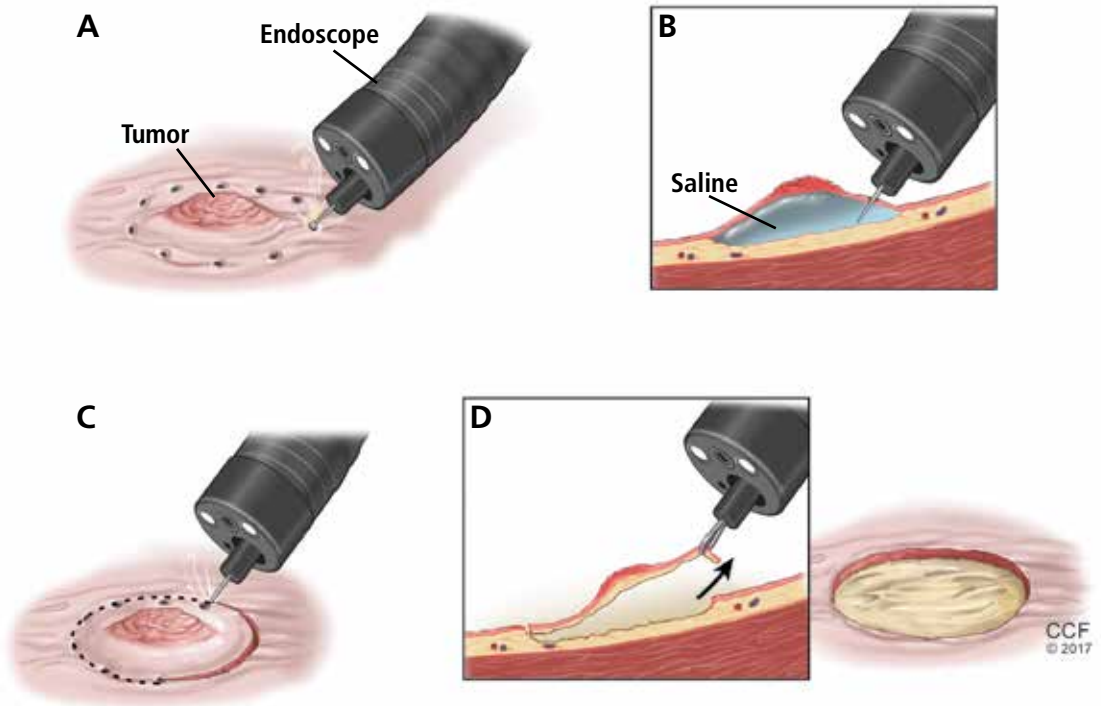
**T**HE TREATMENT OF early esophageal, gastric, and colorectal cancer is changing.<sup>1</sup> For many years, surgery was the mainstay of treatment for early-stage gastrointestinal cancer. Unfortunately, surgery leads to significant loss of function of the organ, resulting in increased morbidity and decreased quality of life.<sup>2</sup>

Endoscopic techniques, particularly endoscopic mucosal resection (EMR) and endoscopic submucosal dissection (ESD), have been developed and are widely used in Japan, where gastrointestinal cancer is more common than in the West. This article reviews the indications, complications, and outcomes of ESD for early gastrointestinal neoplasms, so that readers will recognize the subset of patients who would benefit from ESD in a Western setting.

## ■ ENDOSCOPIC MUCOSAL RESECTION AND SUBMUCOSAL DISSECTION

Since the first therapeutic polypectomy was performed in Japan in 1974, several endoscopic techniques for tumor resection have been developed.<sup>3</sup>

doi:10.3949/ccjm.84a.16063



**FIGURE 1.** Endoscopic submucosal dissection, a minimally invasive treatment for early-stage cancers of the gastrointestinal system, involves the following steps:

- A. Marking the circumference of the tumor
- B. Lifting the tumor by injecting saline or another inert substance beneath it
- C. Cutting around the outside of the tumor margin
- D. Dissecting and removing the tumor

**Western countries have been slow to adopt ESD**

EMR, one of the most successful and widely used techniques, involves elevating the lesion either with submucosal injection of a solution or with cap suction, and then removing it with a snare.<sup>4</sup> Most lesions smaller than 20 mm can be removed in one piece (en bloc).<sup>5</sup> Larger lesions are removed in multiple pieces (ie, piecemeal). Unfortunately, some fibrotic lesions, which are usually difficult to lift, cannot be completely removed by EMR.

ESD was first performed in the late 1990s with the aim of overcoming the limitations of EMR in resecting large or fibrotic tumors en bloc.<sup>6,7</sup> Since then, ESD technique has been standardized and training centers have been created, especially in Asia, where it is widely used for treatment of early gastric cancer.<sup>3,8-10</sup> Since 2012 it has been covered by the Japanese National Health Insurance for treatment of early gastric cancer, and since 2014 for treatment of colorectal malignant tumors measuring 2 to 5 cm.<sup>11</sup>

Adoption of ESD has been slow in Western countries, where many patients are still referred for surgery or undergo EMR for removal of superficial neoplasms. Reasons for this slow adoption are that gastric cancer is much less common in Western countries, and also that ESD demands a high level of technical skill, is difficult to learn, and is expensive.<sup>3,12,13</sup> However, small groups of Western endoscopists have become interested and are advocating it, first studying it on their own and then training in a Japanese center and learning from experts performing the procedure.

Therefore, in a Western setting, ESD should be performed in specialized endoscopy centers and offered to selected patients.<sup>1</sup>

**■ CANDIDATES SHOULD HAVE EARLY-STAGE, SUPERFICIAL TUMORS**

Ideal candidates for endoscopic resection are patients who have early cancer with a negligible risk of lymph node metastasis, such as

cancer limited to the mucosa (stage T1a).<sup>7</sup> Therefore, to determine the best treatment for a patient with a newly diagnosed gastrointestinal neoplasm, it is mandatory to estimate the depth of invasion.

The depth of invasion is directly correlated with lymph node involvement, which is ultimately the main predictive factor for long-term adverse outcomes of gastrointestinal tumors.<sup>4,14–17</sup> Accurate multidisciplinary preprocedure estimations are mandatory, as incorrect evaluations may result in inappropriate therapy and residual cancer.<sup>18</sup>

Other factors that have been used to predict lymph node involvement include tumor size, macroscopic appearance, histologic differentiation, and lymphatic and vascular involvement.<sup>19</sup> Some of these factors can be assessed by special endoscopic techniques (chromoendoscopy and narrow-band imaging with magnifying endoscopy) that allow accurate real-time estimation of the depth of invasion of the lesion.<sup>5,17,20–27</sup> Evaluation of microsurface and microvascular arrangements is especially useful for determining the feasibility of ESD in gastric tumors, evaluation of intracapillary loops is useful in esophageal lesions, and assessment of mucosal pit patterns is useful for colorectal lesions.<sup>21–29</sup>

Endoscopic ultrasonography is another tool that has been used to estimate the depth of the tumor. Although it can differentiate between definite intramucosal and definite submucosal invasive cancers, its ability to confirm minute submucosal invasion is limited. Its use as the sole tumor staging modality is not encouraged, and it should always be used in conjunction with endoscopic evaluation.<sup>18</sup>

Though the aforementioned factors help stratify patients, pathologic staging is the best predictor of lymph node metastasis. ESD provides adequate specimens for accurate pathologic evaluation, as it removes lesions en bloc.<sup>30</sup>

All patients found to have risk factors for lymph node metastasis on endoscopic, ultrasonographic, or pathologic analysis should be referred for surgical evaluation.<sup>9,19,31,32</sup>

## ■ ENDOSCOPIC SUBMUCOSAL DISSECTION

Before the procedure, the patient's physicians need to do the following:

**Determine the best type of intervention** (EMR, ESD, ablation, surgery) for the specific lesion.<sup>3</sup> A multidisciplinary approach is encouraged, with involvement of the internist, gastroenterologist, and surgeon.

**Plan** for anesthesia, additional consultations, pre- and postprocedural hospital admission, and need for special equipment.<sup>33</sup>

### During the procedure

The main steps of ESD are circumferential marking of the lesion, submucosal injection, circumferential incision, and submucosal dissection (**Figure 1**). The endoscopist must do the following:

**Define the lateral extent of the lesion** using magnification chromoendoscopy or narrow-band imaging. In the stomach, a biopsy sample should be taken from the worst-looking segment and from normal-looking mucosa. Multiple biopsies should be avoided to prevent subsequent fibrosis.<sup>33</sup> In the colon, biopsy should be avoided.<sup>34</sup>

**Identify and circumferentially mark the target lesion.** Cautery or argon plasma coagulation can be used for making markings at a distance of 5 to 10 mm from the edges.<sup>33</sup> This is done to recognize the borders of the lesion, because they can become distorted after submucosal injection.<sup>14</sup> This step is unnecessary in colorectal cases, as tumor margins can be adequately visualized after chromoendoscopy.<sup>16,35</sup>

**Lift the lesion** by injecting saline, 0.5% hyaluronate, or glycerin to create a submucosal fluid cushion.<sup>19,33</sup>

**Perform a circumferential incision** lateral to the mucosal margins to allow for a normal tissue margin.<sup>33</sup> Partial incision is performed for esophageal and colorectal ESD to avoid fluid leakage from the submucosal layer, achieving a sustained submucosal lift and safer dissection.<sup>16</sup>

**Submucosal dissection.** The submucosal layer is dissected with an electrocautery knife until the lesion is completely removed. Dissection should be done carefully to keep the submucosal plane.<sup>33</sup> Hemoclips or hemostat forceps can be used to control visible bleeding. The resected specimen is then stretched and fixed to a board using small pins for further histopathologic evaluation.<sup>35</sup>

**ESD should be done in specialized centers, in carefully selected patients**

TABLE 1

Indications for endoscopic resection for gastric tumors<sup>a</sup>

	Absolute indications for EMR or ESD		Expanded criteria for ESD	
<b>Histologic type</b>	Differentiated	Differentiated	Differentiated	Undifferentiated
<b>Tumor diameter</b>	≤ 2 cm	> 2 cm	≤ 3 cm	≤ 2 cm
<b>Ulcerative findings</b>	Negative	Negative	Positive	Negative
<b>Depth of invasion</b>	T1a	T1a	T1a	T1a

<sup>a</sup> Endoscopic resection here refers to endoscopic mucosal resection (EMR) or endoscopic submucosal dissection (ESD).

Based on information from the Japanese Gastric Cancer Association, reference 9.

**Postprocedural monitoring.** All patients should be admitted for overnight observation. Those who undergo gastric ESD should receive high-dose acid suppression, and the next day they can be started on a liquid diet.<sup>19</sup>

■ STOMACH CANCER

Indications for ESD for stomach cancer in the East

The incidence of gastric cancer is higher in Japan and Korea, where widespread screening programs have led to early identification and early treatment of this disease.<sup>36</sup>

Pathology studies<sup>37</sup> of samples from patients with gastric cancer identified the following as risk factors for lymph node metastasis, which would make ESD unsuitable:

- Undifferentiated type
- Tumors larger than 2 cm
- Lymphatic or venous involvement
- Submucosal invasion
- Ulcerative change.

Based on these findings, the situations in which there was no risk of lymph node involvement (ie, when none of the above factors are present) were accepted as absolute indications for endoscopic resection of early gastric cancer.<sup>38</sup> Further histologic studies identified a subset of patients with lesions with very low risk of lymph node metastasis, which outweighed the risk of surgery. Based on these findings, expanded criteria for gastric ESD were proposed,<sup>39,40</sup> and the Japanese gastric cancer treatment guidelines now include these expanded preoperative indications<sup>9,17</sup> (Table 1).

The Japanese Gastric Cancer Association has proposed a treatment algorithm based on the histopathologic evaluation after resection (Figure 2).<sup>9</sup>

Outcomes

In the largest series of patients who underwent curative ESD for early gastric cancer, the 5-year survival rate was 92.6%, the 5-year disease-specific survival rate was 99.9%, and the 5-year relative survival rate was 105%.<sup>41</sup>

Similarly, in a Japanese population-based survival analysis, the relative 5-year survival rate for localized gastric cancer was 94.4%.<sup>42</sup> Rates of en bloc resection and complete resection with ESD are higher than those with EMR, resulting in a lower risk of local recurrence in selected patients who undergo ESD.<sup>8,43,44</sup>

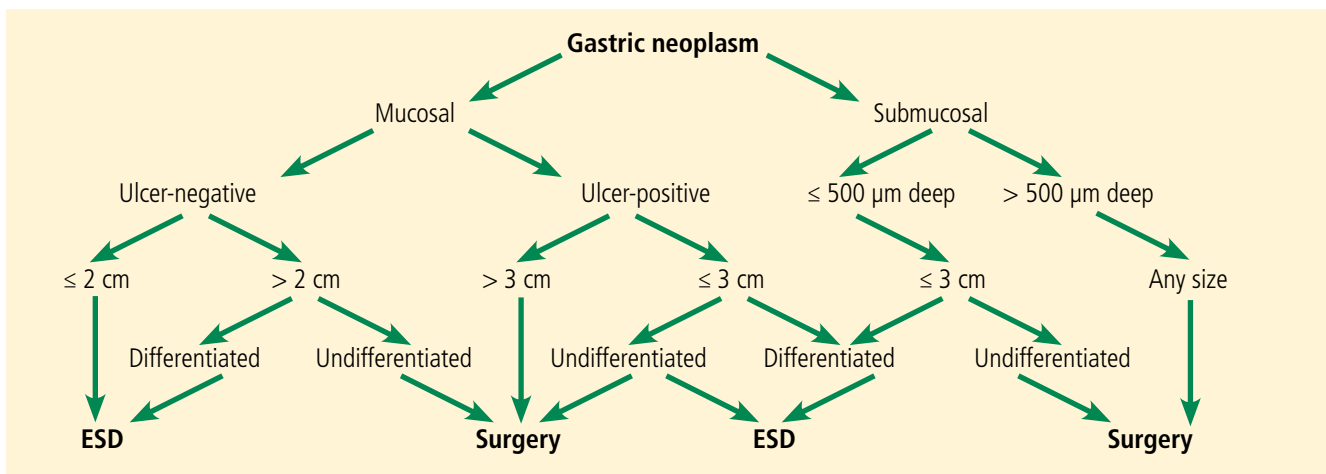
Although rare, local recurrence after curative gastric ESD has been reported.<sup>45</sup> The annual incidence of local recurrence has been estimated to be 0.84%.<sup>46</sup>

ESD entails a shorter hospital stay and requires fewer resources than surgery, resulting in lower medical costs (Table 2).<sup>44</sup> Additionally, as endoscopic resection is associated with less morbidity, fewer procedure-related adverse events, and fewer complications, ESD could be used as the standard treatment for early gastric cancer.<sup>47,48</sup>

The Western perspective on endoscopic submucosal dissection for gastric cancer

Since the prevalence of gastric cancer in Western countries is significantly lower than in Japan and Korea, local data and experience

Estimating the depth of invasion is mandatory



**FIGURE 2.** Treatment algorithm based on the histopathologic evaluation after resection of early gastric tumors.

Based on information from the Japanese Gastric Cancer Association, reference 9.

are scarce. However, experts performing ESD in the West have adopted the indications of the Japan Gastroenterological Endoscopy Society. The European Society of Gastrointestinal Endoscopy recommends ESD for excision of most superficial gastric neoplasms, with EMR being preferred only in lesions smaller than 15 mm, Paris classification 0 or IIA.<sup>5,32</sup>

Patients with gastric lesions measuring 15 mm or larger should undergo high-quality endoscopy, preferably chromoendoscopy, to evaluate the mucosal patterns and determine the depth of invasion. If superficial involvement is confirmed, other imaging techniques are not routinely recommended.<sup>5</sup> A surgery consult is also recommended.

## ■ ESOPHAGEAL CANCER

### Indications for ESD for esophageal cancer in the East

Due to the success of ESD for early gastric cancer, this technique is now also used for superficial esophageal neoplasms.<sup>19,49</sup> It should be done in a specialized center, as it is more technically difficult than gastric ESD: the esophageal lumen is narrow, the wall is thin, and the esophagus moves with respiration and heartbeat.<sup>50</sup> A multidisciplinary approach including an endoscopist, a surgeon, and a pathologist is highly recommended for evaluation and treatment.

EMR is preferred for removal of mucosal cancer, in view of its safety profile and success

rates. ESD can be considered in cases of lesions larger than 15 mm, poorly lifting tumors, and those with the possibility of submucosal invasion (Table 3).<sup>5,45,49,51</sup>

Circumference involvement is critical when determining eligible candidates, as a defect involving more than three-fourths of the esophageal circumference can lead to esophageal strictures.<sup>52</sup> Controlled prospective studies have shown promising results from giving intralesional and oral steroids to prevent stricture after ESD, which could potentially overcome this size limitation.<sup>53,54</sup>

### Outcomes for esophageal cancer

ESD has been shown to be safe and effective, achieving en bloc resection in 85% to 100% of patients.<sup>19,51</sup> Its advantages over EMR include en bloc resection, complete resection, and high curative rates, resulting in higher recurrence-free survival.<sup>2,55,56</sup> Although the incidence of complications such as bleeding, perforation, and stricture formation are higher with ESD, patients usually recover uneventfully.<sup>2,19,20</sup>

### ESD in the esophagus: The Western perspective

As data on the efficacy of EMR vs ESD for the treatment of Barrett esophagus with adenocarcinoma are limited, EMR is the gold standard endoscopic technique for removal of visible esophageal dysplastic lesions.<sup>5,51,57</sup> ESD can be considered for tumors larger than 15 mm, for poorly lifting lesions, and if there is suspicion of submucosal invasion.<sup>5</sup>

**Survival rates are high after ESD for stomach cancer**

**TABLE 2**

**Advantages and disadvantages of available treatments for early gastrointestinal neoplasms**

<b>Treatment category</b>	<b>Treatment</b>	<b>Advantages</b>	<b>Disadvantages</b>
<b>Endoscopic</b>	Endoscopic submucosal dissection (ESD)	Noninvasive Achieves en bloc resection of lesions regardless of size or fibrosis Allows margin evaluation Lower cost vs surgery	Higher cost compared with EMR Longer procedural time compared with EMR Specialized training and facilities needed Risk of recurrence
	Endoscopic mucosal resection (EMR)	Noninvasive Cost-effective Decreased procedural time Decreased length of stay More local experience and data than with ESD	No histologic margin control No resection of fibrotic lesions Risk of recurrence
<b>Surgical</b>	Surgical excision	Lower rates of recurrence Not limited by size, fibrosis, or depth of involvement	Invasive More procedure-associated comorbidity Longer hospital length of stay Higher cost

Patients should be evaluated by an experienced endoscopist, using an advanced imaging technique such as narrow-band imaging or chromoendoscopy. If suspicious features are found, endoscopic ultrasonography should be considered to confirm submucosal invasion or lymph node involvement.<sup>5</sup>

**■ COLORECTAL CANCER**

**Indications for ESD for colorectal cancer in the East**

Colon cancer is one of the leading causes of cancer-related deaths worldwide.<sup>58</sup> Since ESD has been found to be effective and safe in treating gastric cancer, it has also been used to remove large colorectal tumors.<sup>59</sup> However, ESD is not universally accepted in the treatment of colorectal neoplasms due to its greater technical difficulty, longer procedural time, and higher risk of perforating the thinner colonic wall compared with EMR.<sup>21,60</sup>

According to the Japanese Society of Gastroenterology, ESD should be reserved for lesions that are not amenable to snare removal (> 20 mm in size, intramucosal tumors with fibrosis, localized lesions that result from chronic inflammation, and local residual carcinoma) (Tables 4 and 5).<sup>21,61</sup> Colorectal ESD should be performed only by a trained endoscopist.<sup>11</sup>

**Outcomes for colorectal cancer**

Piecemeal resection is one of the predictors of recurrence after endoscopic removal of colorectal cancer.<sup>62</sup> Therefore, the cumulative rates of en bloc resection and curative resection are higher and the recurrence rate is lower for en bloc ESD than for EMR.<sup>62-65</sup> Complication rates and procedural time are higher for ESD than for EMR.<sup>59,66</sup>

Tumor size of 50 mm or larger is a risk factor for complications, while a high procedure volume at the center is a protective factor.<sup>60</sup>

## Endoscopic treatment of colorectal cancer: The Western perspective

EMR is the gold standard for removal of superficial colorectal lesions. However, ESD can be considered if there is suspicion of superficial submucosal invasion, especially for lesions larger than 20 mm that cannot be resected en bloc by EMR.<sup>32</sup> ESD can also be used for fibrotic lesions not amenable to complete EMR removal, or as a salvage procedure after recurrence after EMR.<sup>67</sup> Proper selection of cases is critical.<sup>1</sup>

Patients who have a superficial colonic lesion should be evaluated by means of high-definition endoscopy and chromoendoscopy to assess the mucosal pattern and establish feasibility of endoscopic resection. If submucosal invasion is suspected, staging with endoscopic ultrasonography or magnetic resonance imaging should be considered.<sup>5</sup>

### ■ FOLLOW-UP AFTER ESD

Endoscopic surveillance after the procedure is recommended, given the persistent risk of metachronous cancer after curative ESD due to its organ-sparing quality.<sup>68</sup> Surveillance endoscopy aims to achieve early detection and subsequent endoscopic resection of metachronous lesions.

Histopathologic evaluation assessing the presence of malignant cells in the margins of a resected sample is mandatory for determining the next step in treatment. If margins are negative, follow-up endoscopy can be done every 6 to 12 months. If margins are positive, the approach includes surgery, reattempting ESD or endoscopic surveillance in 3 or 6 months.<sup>3,32</sup> Although the surveillance strategy varies according to individual risk of metachronous cancer, it should be continued indefinitely.<sup>68</sup>

### ■ COMPLICATIONS OF ESD

The most common procedure-related complications of ESD are bleeding, perforation, and stricture. Most intraprocedural adverse events can be managed endoscopically.<sup>69</sup>

#### Bleeding

Most bleeding occurs during the procedure or early after it and can be controlled with electrocautery.<sup>49,69</sup> No episodes of massive bleeding, defined as causing clinical symptoms and

TABLE 3

### Indications for endoscopic resection of squamous cell cancer of the esophagus<sup>a</sup>

	Absolute indications	Relative indications
<b>Depth of invasion</b>	M1, M2	M3, SM1 ( $\leq 200 \mu\text{m}$ )
<b>Circumference</b>	$\leq 2/3$	$\leq 3/4$
<b>Paris classification</b>	0–II	

<sup>a</sup>Endoscopic resection here refers to endoscopic mucosal resection or endoscopic submucosal dissection.

M1 = intraepithelial carcinoma; M2 = tumor located between M1 and M3; M3 = tumor extremely close to or infiltrating the muscularis mucosa; SM1 = submucosally invasive tumor that extends up to 200  $\mu\text{m}$  below the lower border of the muscularis mucosa

Based on information from the Japan Esophageal Society, reference 15.

requiring transfusion or surgery, have been reported.<sup>20,43,55</sup>

In gastric ESD, delayed bleeding rates have ranged from 0 to 15.6%.<sup>69</sup> Bleeding may be prevented with endoscopic coagulation of visible vessels after dissection has been completed and by proton pump inhibitor therapy.<sup>70,71</sup> Excessive coagulation should be avoided to lower the risk of perforation.<sup>33</sup>

In colorectal ESD the bleeding rate has been reported to be 2.2%; applying coagulation to an area where a blood vessel is suspected before cutting (precoagulation) may prevent subsequent bleeding.<sup>21</sup>

#### Perforation

For gastric ESD, perforation rates range from 1.2% to 5.2%.<sup>69</sup> Esophageal perforation rates can be up to 4%.<sup>49</sup> In colorectal ESD, perforation rates have been reported to be 1.6% to 6.6%.<sup>60,72</sup>

Although most of the cases were successfully managed with conservative treatment, some required emergency surgery.<sup>60,73</sup>

#### Strictures

In a case series of 532 patients undergoing gastric ESD, stricture was reported in 5 patients, all of whom presented with obstructive symptoms.<sup>74</sup> Risk factors for post-ESD gastric stenosis are a mucosal defect with a circumferential extent of more than three-fourths or a longitudinal extent of more than 5 cm.<sup>75</sup>

**ESD for esophageal lesions is more technically challenging**

**TABLE 4**

**Indications for endoscopic resection of colorectal lesions**

Type of lesion	Tumor size (mm)			
	< 10	10–20	20–30	≥ 30
<b>LST-NG</b>	EMR	EMR	ESD	ESD
<b>LST-G</b>	EMR	EMR	EMR	ESD
<b>Intramucosal villous tumor</b>	EMR	EMR	EMR	ESD
<b>Intramucosal tumor with nonlifting sign</b>	EMR	EMR or ESD	ESD	ESD
<b>Rectal carcinoid tumor</b>	EMR	ESD or surgery	Surgery	Surgery

EMR = endoscopic mucosal resection; ESD = endoscopic submucosal dissection; LST-G = laterally spreading tumor, granular type; LST-NG = laterally spreading tumor, nongranular type

Based on information from the Japanese Society of Gastroenterology, reference 61.

**Endoscopic surveillance after the procedure is recommended**

Strictures are common after esophageal ESD, with rates ranging from 2% to 26%. The risk is higher when longer segments are removed or circumferential resection is performed. As previously mentioned, this complication may be reduced with ingestion or injection of steroids after the procedure.<sup>53,54</sup>

Surprisingly, ESD of large colorectal lesions involving more than three-fourths of the circumference of the rectum is rarely complicated by stenosis.<sup>76</sup>

**■ LIMITATIONS OF ESD**

ESD requires a high level of technical skill, is time-consuming, and has a higher rate of complications than conventional endoscopic resection. A standardized ESD training system is needed, as the procedure is more difficult than EMR. Training in porcine models has been shown to confer competency in ESD in a Western setting.<sup>13,16,33</sup>

Colorectal ESD is an even more challenging procedure, given the potential for complications related to its anatomy. Training centers in Japan usually have their trainees first master gastric ESD, then assist in more than 20 colorectal ESDs conducted by experienced endoscopists, and accomplish 30 cases before performing the procedure safely and independently.

As the incidence of gastric cancer is low in Western countries, trainees may also begin with lower rectal lesions, which are easier to remove.<sup>77</sup> Incorporation of ESD in the West would require a clear treatment algorithm. It is a complex procedure, with higher rates of complications, a prolonged learning curve, and prolonged procedure time. Therefore, it should be performed in specialized centers and under the special situations discussed here to ensure that the benefits for the patients outweigh the risks.

**■ VALUE OF ENDOSCOPIC SUBMUCOSAL DISSECTION**

The optimal method for resecting gastrointestinal neoplasms should be safe, cost-effective, and quick and should also completely remove the lesion. The best treatment strategy takes into account the characteristics of the lesion and the comorbidities and wishes of the patient. Internists should be aware of the multiple options available to achieve the best outcome for the patient.<sup>1</sup>

Endoscopic resection of superficial gastrointestinal neoplasms, including EMR and ESD, has been a subject of increasing interest due to its minimally invasive and potentially curative character. However, cancer can recur after endoscopic resection because the procedure is organ-sparing.



ESD allows resection of early gastrointestinal tumors with a minimally invasive technique. It can achieve higher curative resection rates and lower recurrence rates compared with EMR. Compared with surgery, ESD leads to less morbidity, fewer procedure-related complications, and lower medical costs. Indications should be rigorously followed to achieve successful treatments in selected patients.

Multiple variables have to be taken into account when deciding which treatment is best, such as tumor characteristics, the patient's baseline condition, physician expertise, and hospital resources.<sup>48</sup> Less-invasive treatments may improve the prognosis of patients. No matter the approach, patients should be treated in specialized treatment centers.

Internal medicine physicians should be aware of the advances in treatments for early gastrointestinal cancer so appropriate options can be considered. ■

## REFERENCES

1. **Burgess NG, Bourke MJ.** Endoscopic resection of colorectal lesions: the narrowing divide between East and West. *Dig Endosc* 2016; 28:296–305.
2. **Kim DH, Jung HY, Gong EJ, et al.** Endoscopic and oncologic outcomes of endoscopic resection for superficial esophageal neoplasm. *Gut Liver* 2015; 9:470–477.
3. **Draganov PV, Gotoda T, Chavalitdharmong D, Wallace MB.** Techniques of endoscopic submucosal dissection: application for the Western endoscopist? *Gastrointest Endosc* 2013; 78:677–688.
4. **Japanese Gastric Cancer Association.** Japanese classification of gastric carcinoma: 3rd English edition. *Gastric Cancer* 2011; 14:101–112.
5. **Pimentel-Nunes P, Dinis-Ribeiro M, Ponchon T, et al.** Endoscopic submucosal dissection: European Society of Gastrointestinal Endoscopy (ESGE) guideline. *Endoscopy* 2015; 47:829–854.
6. **Farhat S, Chaussade S, Ponchon T, et al; SFED ESD Study Group.** Endoscopic submucosal dissection in a European setting. A multi-institutional report of a technique in development. *Endoscopy* 2011; 43:664–670.
7. **Gotoda T, Jung H.** Endoscopic resection (endoscopic mucosal resection/endoscopic submucosal dissection) for early gastric cancer. *Dig Endosc* 2013; 25(suppl 1):55–63.
8. **Chung IK, Lee JH, Lee SH, et al.** Therapeutic outcomes in 1000 cases of endoscopic submucosal dissection for early gastric neoplasms: Korean ESD Study Group multicenter study. *Gastrointest Endosc* 2009; 69:1228–1235.
9. **Japanese Gastric Cancer Association.** Japanese gastric cancer treatment guidelines 2010 (ver. 3). *Gastric Cancer* 2011; 14:113–123.
10. **Ono H.** Endoscopic submucosal dissection for early gastric cancer. *Chin J Dig Dis* 2005; 6:119–121.
11. **Watanabe T, Itabashi M, Shimada Y, et al; Japanese Society for Cancer of the Colon and Rectum.** Japanese Society for Cancer of the Colon and Rectum (JSCCR) guidelines 2014 for treatment of colorectal cancer. *Int J Clin Oncol* 2015; 20:207–239.
12. **Oyama T, Yahagi N, Ponchon T, Kiesslich T, Berr F.** How to establish endoscopic submucosal dissection in Western countries. *World J Gastroenterol* 2015; 21:11209–11220.
13. **Bhatt A, Abe S, Kumaravel A, et al.** SU1575 Western skill training in endoscopic submucosal dissection (ESD)—an international remote

TABLE 5

### Indications for endoscopic submucosal dissection for colorectal cancer

#### Lesions for which en bloc resection with endoscopic mucosal resection is unlikely to succeed

- Laterally spreading tumor, nongranular type
- Lesions with a Vi-type pit pattern
- Carcinoma with shallow T1 invasion
- Large depressed-type tumors
- Large protruding-type tumors suspected to be malignant

#### Mucosal tumors with submucosal fibrosis

#### Sporadic localized tumors in conditions of chronic inflammation

#### Local residual or recurrent early carcinomas after endoscopic resection

Based on information from the Japan Gastroenterological Endoscopy Society, reference 32.

- video based study—the WEST ESD Study. *Gastrointest Endosc* 2015; 81(suppl):AB335–AB336.
- 14. **Sano T, Sasako M, Kinoshita T, Maruyama K.** Recurrence of early gastric cancer follow-up of 1475 patients and review of the Japanese literature. *Cancer* 1993; 72:3174–3178.
- 15. **Japan Esophageal Society.** Japanese classification of esophageal cancer, tenth edition: part I. *Esophagus* 2009; 6:1–25.
- 16. **Bhatt A, Abe S, Kumaravel A, Vargo J, Saito Y.** Indications and techniques for endoscopic submucosal dissection. *Am J Gastroenterol* 2015; 110:784–791.
- 17. **Eleftheriadis N, Inoue H, Ikeda H, et al.** Definition and staging of early esophageal, gastric and colorectal cancer. *J Tumor* 2014; 2:161–178.
- 18. **Yoshinaga S, Oda I, Nonaka S, Kushima R, Saito Y.** Endoscopic ultrasound using ultrasound probes for the diagnosis of early esophageal and gastric cancers. *World J Gastrointest Endosc* 2012; 4:218–226.
- 19. **Stahl M, Mariette C, Haustermans K, Cervantes A, Arnold D; ESMO Guidelines Working Group.** Oesophageal cancer: ESMO clinical practice guidelines for diagnosis, treatment and follow-up. *Ann Oncol* 2013; 24(suppl 6):vi51–vi56.
- 20. **Higuchi K, Tanabe S, Azuma M, et al.** A phase II study of endoscopic submucosal dissection for superficial esophageal neoplasms (KDOG 0901). *Gastrointest Endosc* 2013; 78:704–710.
- 21. **Sakamoto T, Mori G, Yamada M, et al.** Endoscopic submucosal dissection for colorectal neoplasms: a review. *World J Gastroenterol* 2014; 20:16153–16158.
- 22. **Ohta A, Tominaga K, Sakai Y.** Efficacy of magnifying colonoscopy for the diagnosis of colorectal neoplasia: comparison with histopathological findings. *Dig Endosc* 2004; 16:308–314.
- 23. **Katagiri A, Fu K, Sano Y, et al.** Narrow band imaging with magnifying colonoscopy as diagnostic tool for predicting histology of early colorectal neoplasia. *Aliment Pharmacol Ther* 2008; 27:1269–1274.
- 24. **Fu KI, Kato S, Sano Y, et al.** Staging of early colorectal cancers: magnifying colonoscopy versus endoscopic ultrasonography for estimation of depth of invasion. *Dig Dis Sci* 2008; 53:1886–1892.
- 25. **Uraoka T, Saito Y, Ikematsu H, Yamamoto K, Sano Y.** Sano's capillary pattern classification for narrow-band imaging of early colorectal lesions. *Dig Endosc* 2011; 23(suppl 1):112–115.
- 26. **Ikematsu H, Matsuda T, Emura F, et al.** Efficacy of capillary pattern type IIIA/IIIB by magnifying narrow band imaging for estimating

- depth of invasion of early colorectal neoplasms. *BMC Gastroenterol* 2010;10:33.
27. **Matsuda T, Fujii T, Saito Y, et al.** Efficacy of the invasive/non-invasive pattern by magnifying chromoendoscopy to estimate the depth of invasion of early colorectal neoplasms. *Am J Gastroenterol* 2008; 103:2700–2706.
  28. **Sato H, Inoue H, Ikeda H, et al.** Utility of intrapapillary capillary loops seen on magnifying narrow-band imaging in estimating invasive depth of esophageal squamous cell carcinoma. *Endoscopy* 2015; 8:122–128.
  29. **Muto M, Yao K, Kaise M, et al.** Magnifying endoscopy simple diagnostic algorithm for early gastric cancer (MESDA-G). *Dig Endosc* 2016; 28:379–393.
  30. **Waddell T, Verheij M, Allum W, Cunningham D, Cervantes A, Arnold D; European Society for Medical Oncology (ESMO); European Society of Surgical Oncology (ESSO); European Society of Radiotherapy and Oncology (ESTRO).** Gastric cancer: ESMO-ESSO-ESTRO clinical practice guidelines for diagnosis, treatment and follow-up. *Ann Oncol* 2013; 24(suppl 6):vi57–vi63.
  31. **Kuwano H, Nishimura Y, Ohtsu A, et al.** Guidelines for diagnosis and treatment of carcinoma of the esophagus. April 2007 edition: part I - Edited by the Japan Esophageal Society. *Esophagus* 2008; 5:61–73.
  32. **Tanaka S, Kashida H, Saito Y, et al.** JGES guidelines for colorectal endoscopic submucosal dissection/endoscopic mucosal resection. *Dig Endosc* 2015; 27:417–434.
  33. **Gotoda T, Ho KY, Soetikno R, Kaltenbach T, Draganov P.** Gastric ESD: current status and future directions of devices and training. *Gastrointest Endosc Clin North Am* 2014; 24:213–233.
  34. **Saito Y, Sakamoto T, Nakajima T, Matsuda T.** Colorectal ESD: current indications and latest technical advances. *Gastrointest Endosc Clin N Am* 2014; 24:245–255.
  35. **Saito Y, Otake Y, Sakamoto T, et al.** Indications for and technical aspects of colorectal endoscopic submucosal dissection. *Gut Liver* 2013; 7:263–269.
  36. **Saragoni L.** Upgrading the definition of early gastric cancer: better staging means more appropriate treatment. *Cancer Biol Med* 2015; 12:355–361.
  37. **Tsujitani S, Oka S, Saito H, et al.** Less invasive surgery for early gastric cancer based on the low probability of lymph node metastasis. *Surgery* 1999; 125:148–154.
  38. **Soetikno RM, Gotoda T, Nakanishi Y, Soehendra N.** Endoscopic mucosal resection. *Gastrointest Endosc* 2003; 57:567–579.
  39. **Hirasawa T, Gotoda T, Miyata S, et al.** Incidence of lymph node metastasis and the feasibility of endoscopic resection for undifferentiated-type early gastric cancer. *Gastric Cancer* 2009; 12:148–152.
  40. **Gotoda T, Yanagisawa A, Sasako M, et al.** Incidence of lymph node metastasis from early gastric cancer: estimation with a large number of cases at two large centers. *Gastric Cancer* 2000; 3:219–225.
  41. **Suzuki H, Oda I, Abe S, et al.** High rate of 5-year survival among patients with early gastric cancer undergoing curative endoscopic submucosal dissection. *Gastric Cancer* 2016; 19:198–205.
  42. **Matsuda T, Ajiki W, Marugame T, Ioka A, Tsukuma H, Sobue T; Research Group of Population-Based Cancer Registries of Japan.** Population-based survival of cancer patients diagnosed between 1993 and 1999 in Japan: a chronological and international comparative study. *Jpn J Clin Oncol* 2011; 41:40–51.
  43. **Ahn JY, Jung HY, Choi KD, et al.** Endoscopic and oncologic outcomes after endoscopic resection for early gastric cancer: 1370 cases of absolute and extended indications. *Gastrointest Endosc* 2011; 74:485–493.
  44. **Kim Y, Kim YW, Choi JJ, et al.** Cost comparison between surgical treatments and endoscopic submucosal dissection in patients with early gastric cancer in Korea. *Gut Liver* 2015; 9:174–180.
  45. **Abe S, Oda I, Nakajima T, et al.** A case of local recurrence and distant metastasis following curative endoscopic submucosal dissection of early gastric cancer. *Gastric Cancer* 2015; 18:188–192.
  46. **Hahn KY, Park JC, Kim EH, et al.** Incidence and impact of scheduled endoscopic surveillance on recurrence after curative endoscopic resection for early gastric cancer. *Gastrointest Endosc* 2016; 84:628–638.e1.
  47. **Wang S, Zhang Z, Liu M, Li S, Jiang C.** Endoscopic resection compared with gastrectomy to treat early gastric cancer: a systematic review and meta-analysis. *PLoS One* 2015; 10:e0144774.
  48. **Kondo A, de Moura EG, Bernardo WM, et al.** Endoscopy vs surgery in the treatment of early gastric cancer: systematic review. *World J Gastroenterol* 2015; 21:13177–13187.
  49. **Kothari S, Kaul V.** Endoscopic mucosal resection and endoscopic submucosal dissection for endoscopic therapy of Barrett's esophagus-related neoplasia. *Gastroenterol Clin North Am* 2015; 44:317–335.
  50. **Yamashita T, Zeniya A, Ishii H, et al.** Endoscopic mucosal resection using a cap-fitted panendoscope and endoscopic submucosal dissection as optimal endoscopic procedures for superficial esophageal carcinoma. *Surg Endosc* 2011; 25:2541–2546.
  51. **Kagemoto K, Oka S, Tanaka S, et al.** Clinical outcomes of endoscopic submucosal dissection for superficial Barrett's adenocarcinoma. *Gastrointest Endosc* 2014; 80:239–245.
  52. **Katada C, Muto M, Manabe T, Boku N, Ohtsu A, Yoshida S.** Esophageal stenosis after endoscopic mucosal resection of superficial esophageal lesions. *Gastrointest Endosc* 2003; 57:165–169.
  53. **Hanaoka N, Ishihara R, Takeuchi Y, et al.** 1139: A single session of intralesional steroid injection to prevent esophageal stricture after endoscopic submucosal dissection for esophageal squamous cell carcinoma. *Gastrointest Endosc* 2012; 75(suppl):AB175.
  54. **Yamaguchi N, Isomoto H, Nakayama T, et al.** Usefulness of oral prednisolone in the treatment of esophageal stricture after endoscopic submucosal dissection for superficial esophageal squamous cell carcinoma. *Gastrointest Endosc* 2011; 73:1115–1121.
  55. **Ono S, Fujishiro M, Niimi K, et al.** Long-term outcomes of endoscopic submucosal dissection for superficial esophageal squamous cell neoplasms. *Gastrointest Endosc* 2009; 70:860–866.
  56. **Katada C, Muto M, Manabe T, Ohtsu A, Yoshida S.** Local recurrence of squamous-cell carcinoma of the esophagus after EMR. *Gastrointest Endosc* 2005; 61:219–225.
  57. **Hirasawa K, Kokawa A, Oka H, et al.** Superficial adenocarcinoma of the esophagogastric junction: long-term results of endoscopic submucosal dissection. *Gastrointest Endosc* 2010; 72:960–966.
  58. **Jemal A, Bray F, Center MM, Ferlay J, Ward E, Forman D.** Global cancer statistics. *CA Cancer J Clin.* 2011; 61:69–90.
  59. **Nakajima T, Saito Y, Tanaka S, et al.** Current status of endoscopic resection strategy for large, early colorectal neoplasia in Japan. *Surg Endosc* 2013; 27:3262–3770.
  60. **Saito Y, Uraoka T, Yamaguchi Y, et al.** A prospective, multicenter study of 1111 colorectal endoscopic submucosal dissections (with video). *Gastrointest Endosc* 2010; 72:1217–1225.
  61. **Tanaka S, Saitoh Y, Matsuda T, et al; Japanese Society of Gastroenterology.** Evidence-based clinical practice guidelines for management of colorectal polyps. *J Gastroenterol* 2015; 50:252–260.
  62. **Oka S, Tanaka S, Saito Y, et al; Colorectal Endoscopic Resection Standardization Implementation Working Group of the Japanese Society for Cancer of the Colon and Rectum, Tokyo, Japan.** Local recurrence after endoscopic resection for large colorectal neoplasia: a multicenter prospective study in Japan. *Am J Gastroenterol* 2015; 110:697–707.
  63. **Saito Y, Fukuzawa M, Matsuda T, et al.** Clinical outcome of endoscopic submucosal dissection versus endoscopic mucosal resection of large colorectal tumors as determined by curative resection. *Surg Endosc* 2010; 24:343–352.
  64. **Makazu M, Sakamoto T, So E, et al.** Relationship between indeterminate or positive lateral margin and local recurrence after endoscopic resection of colorectal polyps. *Endosc Int Open* 2015; 3:E252–E257.
  65. **Belderbos TD, Leenders M, Moons LM, Siersema PD.** Local recurrence after endoscopic mucosal resection of nonpedunculated colorectal lesions: systematic review and meta-analysis. *Endoscopy* 2014; 46:388–402.
  66. **Fujiya M, Tanaka K, Dokoshi T, et al.** Efficacy and adverse events of EMR and endoscopic submucosal dissection for the treatment of colon neoplasms: a meta-analysis of studies comparing EMR and endo-

- scopic submucosal dissection. *Gastrointest Endosc* 2015; 81:583–595.
67. **Rahmi G, Tanaka S, Ohara Y, et al.** Efficacy of endoscopic submucosal dissection for residual or recurrent superficial colorectal tumors after endoscopic mucosal resection. *J Dig Dis* 2015; 16:14–21.
  68. **Abe S, Oda I, Suzuki H, et al.** Long-term surveillance and treatment outcomes of metachronous gastric cancer occurring after curative endoscopic submucosal dissection. *Endoscopy* 2015; 47:1113–1118.
  69. **Oda I, Suzuki H, Nonaka S, Yoshinaga S.** Complications of gastric endoscopic submucosal dissection. *Dig Endosc* 2013; 25(suppl 1):71–78.
  70. **Takizawa K, Oda I, Gotoda T, et al.** Routine coagulation of visible vessels may prevent delayed bleeding after endoscopic submucosal dissection—an analysis of risk factors. *Endoscopy* 2008; 40:179–183.
  71. **Uedo N, Takeuchi Y, Yamada T, et al.** Effect of a proton pump inhibitor or an H<sub>2</sub>-receptor antagonist on prevention of bleeding from ulcer after endoscopic submucosal dissection of early gastric cancer: a prospective randomized controlled trial. *Am J Gastroenterol* 2007; 102:1610–1616.
  72. **Hayashi N, Tanaka S, Nishiyama S, et al.** Predictors of incomplete resection and perforation associated with endoscopic submucosal dissection for colorectal tumors. *Gastrointest Endosc* 2014; 79:427–435.
  73. **Suzuki H, Oda I, Sekiguchi M, et al.** Management and associated factors of delayed perforation after gastric endoscopic submucosal dissection. *World J Gastroenterol* 2015; 21:12635–12643.
  74. **Tsunada S, Ogata S, Mannen K, et al.** Case series of endoscopic balloon dilation to treat a stricture caused by circumferential resection of the gastric antrum by endoscopic submucosal dissection. *Gastrointest Endosc* 2008; 67:979–983.
  75. **Coda S, Oda I, Gotoda T, Yokoi C, Kikuchi T, Ono H.** Risk factors for cardiac and pyloric stenosis after endoscopic submucosal dissection, and efficacy of endoscopic balloon dilation treatment. *Endoscopy* 2009; 41:421–426.
  76. **Abe S, Sakamoto T, Takamaru H, et al.** Stenosis rates after endoscopic submucosal dissection of large rectal tumors involving greater than three quarters of the luminal circumference. *Surg Endosc* 2016; 30:5459–5464.
  77. **Sakamoto T, Saito Y, Fukunaga S, Nakajima T, Matsuda T.** Learning curve associated with colorectal endoscopic submucosal dissection for endoscopists experienced in gastric endoscopic submucosal dissection. *Dis Colon Rectum* 2011; 54:1307–1312.

---

**ADDRESS:** Amit Bhatt, MD, Department of Gastroenterology and Hepatology, Digestive Disease Institute, A30, Cleveland Clinic, 9500 Euclid Avenue, Cleveland, OH 44195; [bhatta3@ccf.org](mailto:bhatta3@ccf.org)