

THE CLINICAL PICTURE

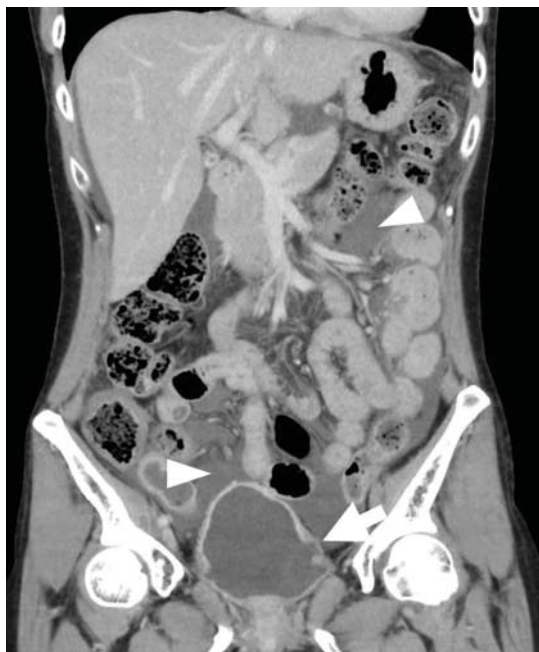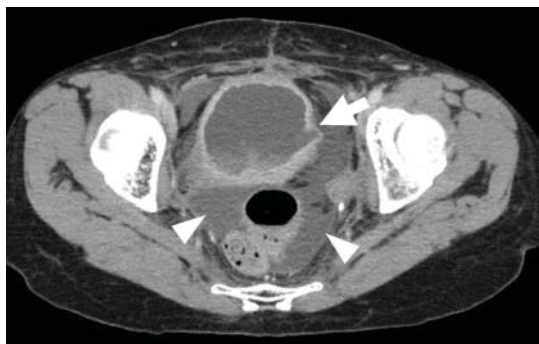
TATSUYA FUJIKAWA, MD, PhD

Department of General Internal Medicine,
Mitoyo General Hospital, Kanonji, Kagawa, Japan

YASUHARU TOKUDA, MD, PhD

Muribushi Project for Teaching Hospitals,
Okinawa, Japan

Ascites from intraperitoneal urine leakage after pelvic radiation



The effects of radiation therapy on the bladder may be seen 2 or 10 or even 40 years after therapy is completed

Figure 1. Contrast-enhanced computed tomography of the abdomen showed massive ascites (arrowheads) and irregularity in the bladder wall (arrow).

A 44-YEAR-OLD WOMAN was admitted to the hospital for the second time in 2 months with acute onset of severe abdominal pain. She had a history of cervical cancer treated with total hysterectomy with bilateral salpingo-oophorectomy, chemotherapy, and radiotherapy at age 38.

Abdominal examination revealed shifting dullness and tenderness without guarding. Massive ascites and irregularity in the bladder wall were detected on ultrasonography and follow-up computed tomography (**Figure 1**). Ascitic fluid collected during the previous admission had shown an elevated ascitic fluid-serum creatinine ratio (4.37) (reference range ≤ 1.0), highly suggestive of intraperitoneal urine leakage.¹ Thus, ascites was assumed to represent intraperitoneal urine leakage due to bladder rupture.

Cystoscopy revealed thinning of the bladder wall with a fistula, and cystography confirmed intraperitoneal leakage of contrast medium from the bladder (**Figure 2**). This led to the diagnosis of urinary ascites from spontaneous bladder rupture following radiation therapy for cervical cancer. She chose conservative treatment (night-time urinary catheterization without surgery), as the bladder wall was diffusely thinned, making surgery difficult. Outpatient follow-up was uneventful.

LONG-TERM EFFECTS OF RADIATION ON THE BLADDER

Urinary ascites from intraperitoneal urine leakage is a rare but clinically important sequel to bladder fistula or bladder wall rupture. Fistula or rupture can be caused by pelvic irradiation, blunt trauma, or surgical procedures, but may also be spontaneous.²

When the total radiation dose to the blad-

doi:10.3949/ccjm.85a.17028

Update on VTE

SUPPLEMENT 3 DECEMBER 2017

In the article, “Update on the management of venous thromboembolism” (Bartholomew JR, *Cleve Clin J Med* 2017; 84[Suppl 3]:39–46), 2 sentences in the text regarding dose reduction for body weight have errors. The corrected sentences follow:

On page 42, left column, the last 5 lines should read: “The recommended dose should

be reduced to 2.5 mg twice daily in patients that meet 2 of the following criteria: age 80 or older; body weight of 60 kg or less; or with a serum creatinine 1.5 mg/dL or greater.”

And on page 42, right column, the sentence 10 lines from the top should read: “Edoxaban is given orally at 60 mg once daily but reduced to 30 mg once daily if the CrCL is 30 mL/min to 50 mL/min, if body weight is 60 kg or less, or with use of certain P-glycoprotein inhibitors.”