

## THE CLINICAL PICTURE

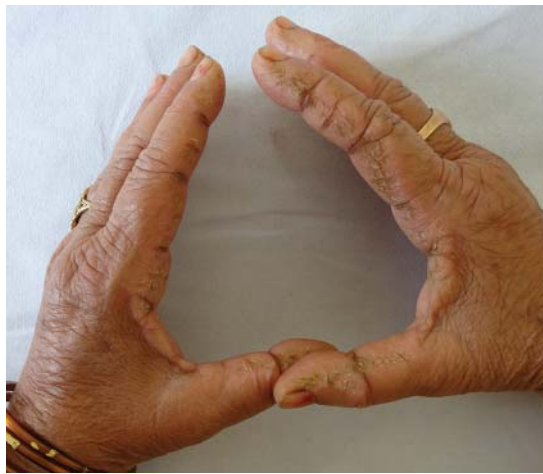
**ANURADHA BISHNOI, MD**

Department of Dermatology, Venereology, and Leprology, Postgraduate Institute of Medical Education and Research, Chandigarh, India

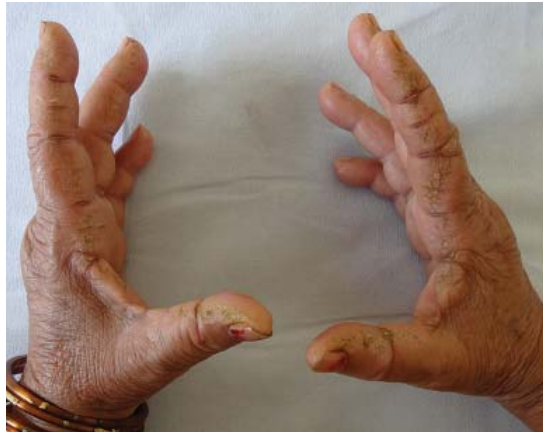**DAVINDER PARSAD, MD**

Department of Dermatology, Venereology, and Leprology, Postgraduate Institute of Medical Education and Research, Chandigarh, India

# Hyperkeratotic fissured plaques on both hands: Mechanic's hands



This sign is seen in about 30% of patients with antisynthetase syndrome



**Figure 1.** Both hands had symmetrical, linear, hyperkeratotic, fissured, scaly plaques on the radial aspect of the index fingers and ulnar aspect of thumbs, including the web area. Fissures were hyperpigmented. The palmar aspect of the fingers was not affected. The radial aspect of the middle fingers was minimally involved.

doi:10.3949/ccjm.85a.17045

A HOUSEWIFE in her 50s presented with photosensitivity and recent-onset roughness on her index fingers and thumbs. Examination showed asymptomatic, bilaterally symmetrical, hyperkeratotic, scaly, fissured plaques with hyperpigmentation on the radial aspect of the index finger of both hands, extending to the ulnar aspect of the thumbs and sparing the palmar aspect of both (**Figure 1**). Palms, soles, and other fingers were normal.

Nail fold capillaroscopy did not reveal telangiectasia or ragged cuticles. Further examination of the skin showed confluent macular violaceous erythema on the eyelids (suggestive of the heliotrope sign), V area of the neck, upper arms, and back.

She also had a low-grade intermittent fever for the past 2 months, as well as difficulty in getting up from a squatting position and combing her hair, dyspnea on exertion, blue discoloration of the fingers on exposure to cold, and intermittent pain, stiffness, and swelling in the small joints of both hands that was worse in the morning and seemed to be relieved by activity. She had no history of dysphagia or nasal regurgitation of food. Strength against resistance was reduced in both arms and knee extensors. A diagnosis of dermatomyositis with “mechanic’s hands” was considered.

Laboratory testing was negative for anti-nuclear antibodies and showed elevated creatine kinase and positive anti-Jo-1 antibodies. High-resolution computed tomography of the chest showed evidence of interstitial lung disease. Features were consistent with antisynthetase syndrome and dermatomyositis. An age-appropriate malignancy screen was normal.

The patient was started on oral prednisolone 60 mg, hydroxychloroquine 300 mg, and azathioprine 100 mg. For her hands, topical clobetasol propionate 0.05% with 3% salicylic acid and emollients were advised. Her muscle weakness improved considerably after 2 months, but the photosensitivity and mechanic's hands improved only minimally.

## ■ ANTISYNTHEASE SYNDROME

Antisynthetase syndrome is a subset of idiopathic inflammatory myopathies characterized by fever, Raynaud phenomenon, arthritis, myositis, interstitial lung disease, and mechanic's hands. It is associated with myositis-specific antibodies directed against aminoacyl-tRNA synthetases, of which anti-Jo-1 is the most common. Other antibodies including anti-PL-7 and anti-PL-12 may be present, whereas antinuclear antibodies may be negative.

Mechanic's hands is seen in about 30% of patients with antisynthetase syndrome and is an important physical sign, as its presence in a patient with myositis and arthritis prompts an evaluation to exclude interstitial lung disease. Its onset later in the disease course may herald the flare-up of interstitial lung disease.<sup>1</sup> A similar hyperkeratosis may also affect the feet, and the importance of a careful cutaneous examination of the hands and feet should be stressed in patients presenting with polymyositis and dermatomyositis.

In contrast, hyperkeratotic eczema of the hand is usually pruritic, and involvement of the tips and palmar aspects of the fingers and palms is characteristic.<sup>2,3</sup> Vesicles (pompholyx) and coarse pitting of the nails may also be seen in eczema. Other features that help rule out

eczema are the development of these features over a short period of time, asymptomatic nature, presence of systemic symptoms, and involvement of only the lateral margins of the index fingers, with no involvement of the palmar aspects and other fingers.

Degenerative collagenous plaque, closely resembling mechanic's hands, is common in elderly people with photodamaged skin. It is asymptomatic, is not associated with systemic illness, and features clumping and thickening of elastic fibers on histopathology.

## Association with cancer risk

Though antisynthetase syndrome was not previously considered to be associated with an increased risk of malignancy, a retrospective review of 124 patients with antisynthetase syndrome recently showed a malignancy risk of 6.5%.<sup>4</sup> Overall, the data regarding the association of malignancy and antisynthetase syndrome are conflicting, and this needs further study. Therefore, an age-appropriate malignancy screen is recommended.<sup>4-6</sup> Also, the presence of malignancy and interstitial lung disease is associated with a poor prognosis in these patients.

## Treatment

Glucocorticoids are the mainstay of treatment, and azathioprine and methotrexate are important steroid-sparing agents.<sup>5,7</sup> Use of methotrexate warrants caution in patients with interstitial lung disease, since methotrexate itself can cause pulmonary fibrosis.

In our patient, prednisolone was slowly tapered to 20 mg/day, and hydroxychloroquine and azathioprine were continued at 300 mg/day and 100 mg/day, respectively. Topical treatment for mechanic's hands was continued, with only minimal improvement. ■

## ■ REFERENCES

1. Bartoloni E, Gonzalez-Gay MA, Scire C, et al. Clinical follow-up predictors of disease pattern change in anti-Jo1 positive anti-synthetase syndrome: results from a multicenter, international and retrospective study. *Autoimmun Rev* 2017; 16(3):253–257. doi: 10.1016/j.autrev.2017.01.008.
2. Bachmeyer C, Tillie-Leblond I, Lacert A, Cadranet J, Aractingi S. "Mechanic's hands": a misleading cutaneous sign of the antisynthetase syndrome. *Br J Dermatol* 2007; 156(1):192–194. doi: 10.1111/j.1365-2133.2006.07593.x.
3. Mii S, Kobayashi R, Nakano T, et al. A histopathologic study of mechanic's hands associated with dermatomyositis: a report of five cases. *Int J Dermatol* 2009; 48(11):1177–1182. doi: 10.1111/j.1365-4632.2009.04164.x.
4. Shi J, Li S, Yang H, et al. Clinical profiles and prognosis of patients with distinct antisynthetase autoantibodies. *J Rheumatol* 2017; 44(7):1051–1057. doi: 10.3899/jrheum.161480.
5. Chatterjee S, Prayson R, Farver C. Antisynthetase syndrome: not just an inflammatory myopathy. *Cleve Clin J Med* 2013; 80(10):655–666. doi: 10.3949/ccjm.80a.12171.
6. Boleto G, Perotin JM, Eschard JP, Salmon JH. Squamous cell carcinoma of the lung associated with anti-Jo1 antisynthetase syndrome: a case report and review of the literature. *Rheumatol Int* 2017; 37(7):1203–1206. doi: 10.1007/s00296-017-3728-z.
7. Mirrakhimov AE. Antisynthetase syndrome: a review of etiopathogenesis, diagnosis and management. *Curr Med Chem* 2015; 22(16):1963–1975. doi: 10.2174/0929867322666150514094935.

ADDRESS: Davinder Parsad, MD, Department of Dermatology, Venereology, and Leprology, Postgraduate Institute of Medical Education and Research, Sector 12, Chandigarh 160012 India; parsad@me.com