

**CHRISTINE LARA KLASSEN, MD**  
Assistant Professor of Medicine, Division  
of General Internal Medicine, Mayo Clinic,  
Rochester, MN

**STEPHANIE L. HINES, MD**  
Assistant Professor of Medicine,  
Division of General Internal Medicine,  
Mayo Clinic, Jacksonville, FL

**KARTHIK GHOSH, MD**  
Professor of Medicine, Division of  
General Internal Medicine, Mayo Clinic,  
Rochester, MN

# Common benign breast concerns for the primary care physician

## ABSTRACT

Women often visit their primary care physician because of breast concerns such as masses, pain, and nipple discharge. Most breast problems are benign, but it is important to know how to manage these and other breast problems and when to refer patients for further testing.

## KEY POINTS

The two most common breast symptoms are lumps and pain.

Most breast problems are not caused by cancer.

Evaluation of any breast problem begins with a focused history followed by a breast examination and, when necessary, imaging.

If the results of the breast examination and imaging suggest a benign cause, no further follow-up is necessary.

If there is discordance between imaging and breast examination results, or if there is a high clinical suspicion of cancer, then consider serial follow-up examinations at short intervals, referral to a breast surgeon for excision, or both.

**B**REAST CONCERNS account for approximately 3% of all female visits to a primary care practice.<sup>1</sup> The most common symptoms are breast lumps and breast pain.

Because breast cancer is the most common malignancy in women in the United States, affecting nearly 1 in 8 women in their lifetime, women with breast problems often fear the worst. However, only about 3.5% of women reporting a concern have cancer; most problems are benign (Table 1).<sup>1</sup>

Here, we present an evidence-based review of common breast problems in primary care practice and discuss how to evaluate and manage them.

## ■ GENERAL APPROACH

The evaluation of a breast concern requires a systematic approach, beginning with a history that documents the onset, severity, and frequency of symptoms. If the concern is a lump or mass, ask whether it becomes more tender or increases in size at any point during the menstrual cycle.

Focus the physical examination on the cervical, supraclavicular, infraclavicular, and axillary lymph nodes and on the breast itself. Assess breast symmetry, note any skin changes such as dimpling, and check the nipples for discharge and inversion. Palpate the breasts for masses.

## ■ PALPABLE BREAST MASS: IMAGING NEEDED

If a mass is present, it is more likely to be malignant if any of the following is true:

- Firm to hard texture or indistinct margins
- Attached to the underlying deep fascia or skin

**TABLE 1**

**Benign causes of common breast symptoms**

Symptom	Causes
<b>Breast pain</b>	Cystic lesions Fibrocystic disease Stretching of Cooper ligaments Mastitis Duct ectasia Postsurgical pain
<b>Nipple discharge</b>	Hypothyroidism Galactorrhea Intraductal papilloma Periductal mastitis Duct ectasia
<b>Breast mass</b>	Cyst Fibroadenoma Prominent fibroglandular ridge Fat lobule Intramammary lymph node

**Breast pain is rarely due to cancer**

- Associated nipple inversion or skin dimpling.<sup>2</sup>

Breast masses are more likely benign if they have discrete, well-defined margins, are mobile with a soft to rubbery consistency, and change with the menstrual cycle. However, clinical features are unreliable indicators of cause, and thus additional investigation with breast imaging is warranted.

**Mammography** remains the diagnostic test of choice for all women age 30 or older who have a palpable breast mass. It is less effective in younger women because they are more likely to have extremely dense fibroglandular tissue that will limit its sensitivity to imaging.

Order diagnostic mammography, which includes additional views focused on the area of concern, rather than screening mammography, which includes only standard cranio-caudal and mediolateral oblique views. A skin marker should be applied over the palpable lump to aid imaging. Because a breast that contains a mass may be denser than the opposite breast or may show asymmetry, both breasts should be imaged. The sensitivity of diagnostic mammography varies from 85% to 90%, so a negative mammogram does not rule out malignancy.<sup>2,3</sup>

**Targeted ultrasonography** of the palpable

mass helps identify solid masses such as fibroadenomas or malignant tumors, classifies the margins (lobulated, smooth, or irregular), and assesses vascularity. Ultrasonography is particularly useful for characterizing cystic lesions (eg, simple, septated, or clustered cysts) and cysts with internal echoes. It can also identify lipomas or sebaceous cysts.

If the findings on both mammography and ultrasonography are benign, the likelihood of cancer is very low, with an estimated negative predictive value of 97% to 100%.<sup>2,3</sup> Additionally, the likelihood of nonmalignant findings on biopsy after benign imaging is approximately 99%.<sup>3</sup>

Although radiologic imaging can define palpable masses, it is intended as a clinical aid. Suspicious findings on clinical examination should never be ignored even if findings on imaging are reassuring, as studies have documented that about 5% of breast cancers may be detected on clinical breast examination alone.<sup>4</sup>

Other imaging tests such as magnetic resonance imaging may be considered occasionally if clinical suspicion remains high after negative mammography and ultrasonography, but they cannot confirm a diagnosis of malignancy. In that case, refer the patient to a surgeon for consideration of excisional biopsy.

Patients with an indeterminate lesion can return in 3 to 12 weeks for a follow-up examination and repeat imaging, which helps assess interval clinical stability. The latter option is especially helpful for patients with masses that are of low suspicion or for patients who prefer to avoid invasive tissue biopsy.

Patients with clinical and radiologic findings that suggest a benign cause can return for short-term follow-up in 6 months or in 12 months for their regular mammogram.

**■ BREAST PAIN: RARELY MALIGNANT**

More than 50% of women experience breast pain at some point in their life.<sup>5</sup> Of these, 35% report that the pain adversely affects their sleep, and 41% note that the pain detrimentally affects their sexual quality of life. Up to 66% of breast pain correlates directly with the patient's menstrual cycle.<sup>5</sup> Breast pain is rarely associated with malignancy.

Regardless of its severity and the low likelihood of malignancy, breast pain can be a significant source of distress for the patient, primarily because of concerns about underlying malignancy. If the patient has a focal area of pain on examination, order mammography in combination with targeted ultrasonography. The sensitivity and negative predictive value of benign findings on combination mammography and ultrasonography in this setting are as high as 100%. The incidence of underlying cancer in patients with focal breast pain and no palpable mass is approximately 1.2%.<sup>6</sup>

The long-term prognosis in women with diffuse, often bilateral breast pain (in the absence of additional clinical findings) is excellent. In one study, the incidence of a breast cancer diagnosis was 1.8% after a median of 51 months of follow-up.<sup>7</sup> Therefore, patients presenting with diffuse pain, no palpable abnormalities, and benign imaging can be safely reassured. Magnetic resonance imaging is rarely indicated in patients with breast pain unless other clinical findings, such as a mass or skin changes, are noted and the results of mammography and ultrasonography are negative.

### Treating breast pain

Treating breast pain remains a challenge. The first step is to reassure the patient about her prognosis and help her make appropriate lifestyle modifications.

**A well-fitting bra.** Suggest getting a professional bra fitting. Wearing a well-fitted bra that offers lift, support, and compression and reduces excess motion can help improve benign breast pain. A bra fitting is especially important for women with large breasts because it can be difficult for these women to get an accurate size. Wearing a lightly fitted bra at night may also provide comfort if there is nighttime pain with breast tissue movement.

**Reducing daily caffeine** intake is often advised for pain management, but strong evidence of its efficacy is lacking.

**Anti-inflammatory drugs** can be beneficial if used short-term, especially if costochondritis is suspected.

**Danazol** improves pain in more than 70% of patients with cyclical symptoms and in up to 48% of those with noncyclical symptoms.

**Bromocriptine** is effective in up to 54% of

those with cyclical symptoms and in up to 33% of those with noncyclical symptoms.<sup>8</sup> However, the US Food and Drug Administration (FDA) withdrew approval for this indication because of adverse effects.

**Tamoxifen**, in contrast, provides relief in 94% of those with cyclical symptoms and in 56% of those with noncyclical symptoms.<sup>9</sup>

Adverse effects, however, limit the use of danazol, bromocriptine, and tamoxifen, and they should be prescribed only for short-term use (3 to 6 months) and only in women with chronic debilitating pain.

A few small studies have evaluated alternative options.

**Toremifene** is a triphenylethylene derivative similar to tamoxifen that is also used in the adjuvant treatment of postmenopausal breast cancer (but with fewer adverse effects). It has been documented to have a significant effect on premenstrual breast pain, with a 64% reduction in breast pain scores compared with a 26% reduction with placebo.<sup>10</sup> However, the FDA has not approved it for this indication, and it can be cost-prohibitive.

**Over-the-counter medications** that may provide relief for cyclic breast pain include vitamin E or B<sub>6</sub>, products containing oil of *Vitex agnus castus* (chaste tree or chasteberry), and flaxseed.<sup>11,12</sup>

**Acupuncture** has been evaluated in patients with noncyclic breast pain and was found to reduce pain by 56% to 67% in one study,<sup>13</sup> although it did not affect quality of life.

### ■ NIPPLE DISCHARGE

From 5% to 7% of women seek medical attention for nipple discharge.<sup>14,15</sup> Breast cancer is found in 5% to 15% of women who undergo surgery for nipple discharge.<sup>16,17</sup>

Review the patient's current medications and inquire about health conditions such as thyroid dysfunction or visual field changes that suggest a pituitary mass (which can lead to nipple discharge by causing hormonal dysregulation or hyperprolactinemia).

Palpate the breasts for an underlying mass, look for lesions on the nipple, and assess the color of the fluid. Also note whether there is discharge from one or both breasts, whether it is spontaneous or expressive, and whether it

**Patients with diffuse pain, no palpable abnormalities, and benign imaging can be reassured**

**TABLE 2**

**BI-RADS breast density categories**

Category	Description
<b>A</b>	Almost entirely fatty
<b>B</b>	Scattered areas of fibroglandular density
<b>C</b>	Heterogeneously dense, which may lower the sensitivity of mammography
<b>D</b>	Extremely dense, which lowers the sensitivity of mammography

BI-RADS = Breast Imaging Reporting and Data System

**Pathologic discharge is often unilateral and persistent, occurring spontaneously from a solitary duct, and may be bloody or serous**

occurs from a single or multiple ducts. Nipple lesions may require further testing with punch biopsy.

Nonlactational nipple discharge is classified as physiologic or pathologic. Physiologic nipple discharge is typically bilateral, involving multiple ducts, and is often clear or straw-colored but may also be green, gray, or brown.

White, opaque fluid is often related to galactorrhea as a result of hyperprolactinemia, hypothyroidism, or medications such as antipsychotic drugs (eg, haloperidol and fluphenazine) and gastrointestinal motility agents such as metoclopramide. Discharge also commonly results from benign underlying ductal abnormalities such as intraductal papilloma, periductal mastitis, and duct ectasia.

Pathologic nipple discharge is often unilateral and persistent, occurring spontaneously from a solitary duct, and may be bloody or serous.

For women with pathologic nipple discharge who are 30 or older, diagnostic imaging with mammography and subareolar ultrasonography is recommended. If the patient is younger than 30, ultrasonography of the subareolar region alone can be used. Targeted ultrasonography of any palpable area is also advised.

Cytologic assessment of the fluid is not recommended because it can often lead to a false-positive finding of atypical cells. Imaging studies such as ductography, duct lavage, ductoscopy, and magnetic resonance imaging are also generally unnecessary; instead, a persistent clinical concern should prompt a surgical referral for consideration of duct excision.

When a patient has pathologic nipple discharge with a negative physical examination

and breast imaging, studies have shown that the risk of cancer is 3% or less.<sup>18</sup>

Patients with spontaneous bloody or serous single-duct discharge with negative results on mammography and ultrasonography should be reassured that they have a low risk of underlying cancer. If the patient prefers, one approach to management is follow-up mammography and ultrasonography at 6 months and clinical examination for up to 2 years or until the discharge resolves on its own.

On the other hand, if the discharge is distressing to the patient, subareolar duct excision can be performed with both a diagnostic and therapeutic purpose.

**■ NIPPLE-AREOLAR RASH: CONSIDER PAGET DISEASE**

A rash on the nipple or areolar region warrants careful evaluation because it may be the first sign of Paget disease of the breast.

In the clinical breast examination, assess the extent of the rash and the presence of any underlying breast mass or nipple discharge. Dermatitis often starts on the areola and resolves quickly with topical therapy. However, Paget disease tends to start directly on the nipple itself, is unresponsive or only partially responsive to topical therapy, and progresses gradually, leading to erosions and ultimately effacement of the nipple itself.

If the clinical examination suggests mild dermatitis and the results of breast imaging are negative, treat the patient with a topical medication because benign conditions such as dermatitis and eczema are common. However, continued follow-up is mandatory until the rash completely resolves: Paget disease sometimes initially improves with topical therapy due to its inflammatory nature.

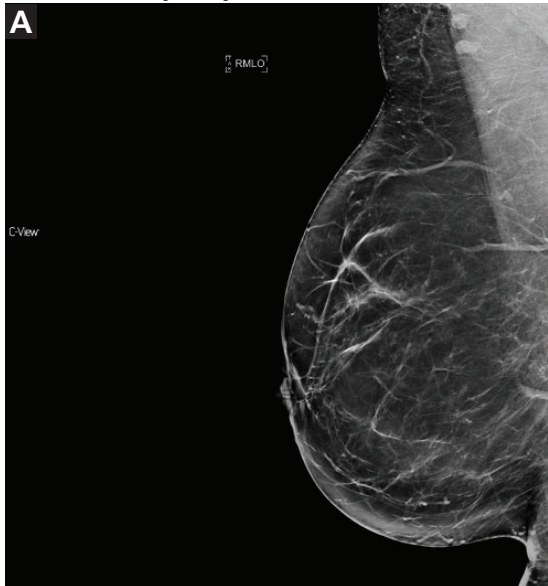If you suspect Paget disease or the rash does not fully resolve after 2 to 3 weeks of topical therapy, refer the patient to a dermatologist for full-thickness punch biopsy to establish the diagnosis.

Paget disease of the breast may or may not be associated with underlying ductal carcinoma in situ or invasive breast cancer.<sup>19</sup> The absence of clinical or imaging abnormalities in a patient with Paget disease does not rule out underlying malignancy.<sup>20</sup>

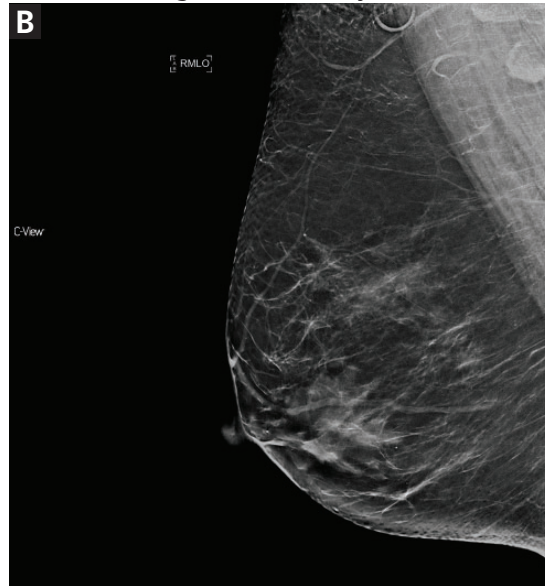


**Breast density categories**

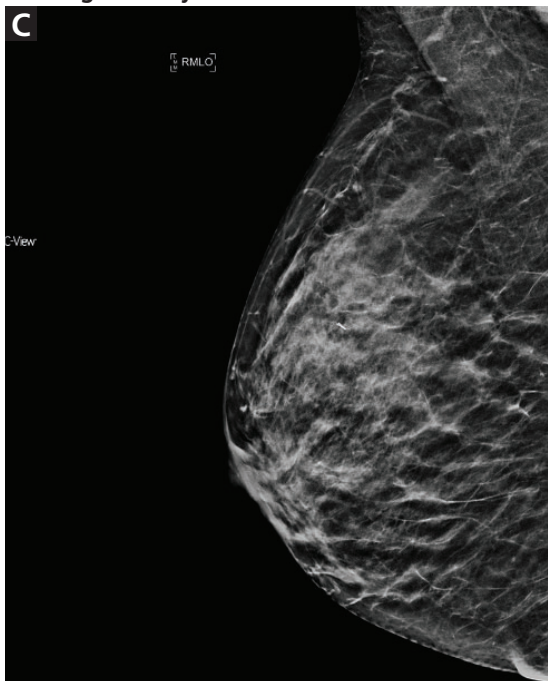
Almost entirely fatty



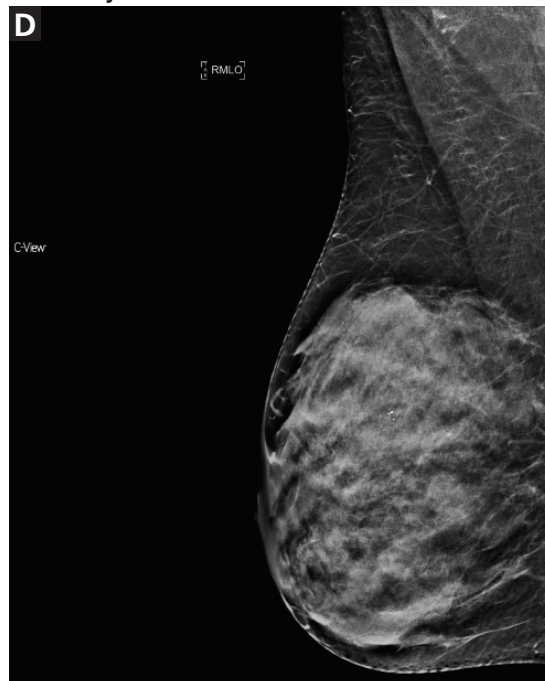
Scattered fibroglandular density



Heterogeneously dense



Extremely dense



**Nearly 80% of women fall into category B or C**

**Figure 1.**

**DENSE BREASTS**

From 35% to 50% of all women have dense breast tissue.<sup>21,22</sup> Breast density is defined as the ratio of stromal and glandular tissues (which appear radio-opaque on mammography) to radiolucent fat. The Breast Imaging Reporting and Data System (BI-RADS), fifth edition,

recognizes 4 categories of density, designated A through D (Table 2 and Figure 1).<sup>23</sup>

Nearly 80% of women fall into category B (scattered areas of fibroglandular density) and category C (heterogeneously dense), with significant interreader variation. One study showed that 13% to 19% of women were re-

**TABLE 3**

**BI-RADS categories of screening mammography and their management**

Categories	Assessment	Recommendation	Risk of malignancy
0	Incomplete	Diagnostic imaging or comparison films needed	Not applicable
1	Negative	Routine screening	Essentially 0%
2	Benign	Routine screening	Essentially 0%
3	Probably benign	Follow up at 6 months	> 0% but ≤ 2%
4	Suspicious a = low b = moderate c = high	Biopsy	4a > 2% to ≤ 10% 4b > 10% to ≤ 50% 4c > 50% to ≤ 95%
5	Highly suspicious	Biopsy	≤ 95%
6	Known cancer	Treatment, as appropriate	Not applicable

BI-RADS = Breast Imaging Reporting and Data System

Based on information in reference 23.

**Dense breasts reduce the sensitivity of mammography to about 25%–50%**

classified from dense to nondense or vice versa on subsequent mammograms.<sup>22</sup>

Increased breast density has been shown to be a risk factor for breast cancer and may be prognostically useful when combined with the Tyrer-Cuzick model or the Gail model of breast cancer risk.<sup>24</sup>

Additionally, increased density can mask cancers on mammography, significantly reducing its sensitivity. In women with heterogeneously or extremely dense breasts, the sensitivity of mammography for detecting cancer is only 25% to 50%.<sup>21</sup> Due to this low sensitivity, supplemental imaging is helpful, particularly in women already at risk of breast cancer based on family history.

**Supplemental screening**

**Digital mammography with tomosynthesis** was approved by the FDA in 2011 for use in combination with standard digital mammography for breast cancer screening. Compared with traditional 2-dimensional mammography alone, adding 3-D tomosynthesis decreases the recall rate and increases the cancer detection rate.<sup>25</sup>

Tomosynthesis tends to perform better in women with heterogeneously dense breasts (BI-RADS category C). There is no significant im-

provement in cancer detection in women with extremely dense breasts (BI-RADS category D).<sup>26</sup>

Depending on the methodology, radiation exposure can be either higher or lower than with traditional mammography. However, in all forms, the very small amount of radiation is considered safe.

**Whole breast ultrasonography.** When whole breast ultrasonography is used to supplement mammography, the recall rate is higher than when mammography is used alone (14% vs 7%–11%).<sup>22</sup> It also increases the cancer detection rate by 4.4 additional cancers per 1,000 examinations. However, the false-positive rate with whole breast ultrasonography is higher; the positive predictive value of combined mammography and ultrasonography is 11.2% vs 22.6% for mammography alone.<sup>22</sup> Therefore, we do not generally recommend whole breast ultrasonography as a supplement to mammography in women with dense breast tissue unless other studies are not an option.

**Molecular breast imaging** is not widely available because it requires special equipment, injection of a radiopharmaceutical (technetium Tc 99m sestamibi), and a radiologist who specializes in breast imaging to interpret the results. When it is available, however, it increases the cancer detection

TABLE 4

**Management of benign breast disease found on core-needle biopsy**

Type of lesion	Pathology	Management
<b>Nonproliferative</b> (Relative risk [RR] of subsequent breast cancer 1.2–1.4) <sup>28,29</sup>	Simple cyst	Observation or aspiration
	Usual ductal hyperplasia (mild)	Observation
	Columnar cell change	Observation
	Apocrine metaplasia	Observation
<b>Proliferative without atypia</b> (RR 1.7–2.1) <sup>28,29</sup>	Fibroadenoma	Observation, consider excision if > 2 cm
	Radial scar	< 1 cm: observation if solitary ≥ 1 cm: surgical consultation
	Intraductal papilloma	Surgical consultation if > 1 cm, atypical, or multiple
	Usual ductal hyperplasia (moderate to florid)	Observation
<b>Proliferative with atypia</b> (RR 4.2) <sup>28,29</sup>	Atypical ductal hyperplasia	Surgical consultation
	Atypical lobular hyperplasia	Observation, offer chemoprevention
	Lobular carcinoma in situ	Surgical consultation

rate by 8.8 in 1,000 examinations; the positive predictive value is similar to that of screening mammography alone.<sup>21</sup> It is particularly useful in patients with dense breasts who do not qualify for screening magnetic resonance imaging (lifetime risk of < 20% to 25%).

Technetium sestamibi is associated with a minimal amount of radiation exposure (2.4 mSv vs 1.2 mSv with standard mammography). However, this exposure is much less than background radiation exposure and is considered safe.<sup>21</sup>

**IF THE PATIENT HAS AN ABNORMAL SCREENING MAMMOGRAM**

Screening mammography can disclose abnormalities such as calcifications, masses, asymmetry, or architectural distortion.<sup>27</sup> Abnormalities are reported using standardized BI-RADS categories designated with the numbers 0 through 6 (Table 3).<sup>23</sup>

A report of BI-RADS category 0 (incomplete), 4 (suspicious), or 5 (highly suspicious) requires additional workup.

Category 1 (negative) requires no further

follow-up, and the patient should resume age-appropriate screening.

For patients with category 2 (benign) findings, routine screening is recommended, whereas patients with category 3 (probably benign) are advised to come back in 6 months for follow-up imaging.

Diagnostic mammography includes additional assessments for focal symptoms or areas of abnormality noted on screening imaging or clinical examination. These may include spot magnification views of areas of asymmetry, mass, architectural distortion, or calcifications. Ultrasonography of focal breast abnormalities can help determine if there is an underlying cyst or solid mass.

**MANAGEMENT OF BENIGN FINDINGS ON BREAST BIOPSY**

Benign breast disease is diagnosed when a patient with a palpable or radiographic abnormality undergoes breast biopsy with benign findings.<sup>28,29</sup> It can be largely grouped into 3 categories: nonproliferative, proliferative without atypia, and proliferative with atypia (Table 4).<sup>28,29</sup>

**A report of BI-RADS category 0 (incomplete), 4 (suspicious), or 5 (highly suspicious) requires additional workup**

If core-needle biopsy study results are benign, the next step is to establish radiologic-pathologic and clinical-pathologic concordance. If the findings on clinical examination or imaging are not consistent with those on pathologic study, excisional biopsy should be performed, as imaging-directed biopsy may not have adequately sampled the lesion.<sup>30</sup>

**Nonproliferative lesions** account for about 65% of findings on core-needle biopsy and include simple cysts, fibroadenomas, columnar cell changes, apocrine metaplasia, and mild ductal hyperplasia of the usual type. These lesions do not significantly increase the risk of breast cancer; the relative risk is 1.2 to 1.4.<sup>28,29</sup> Additionally, the risk of “upstaging” after excisional biopsy—ie, to a higher-risk lesion or to malignancy—is minimal. Therefore, no additional action is necessary when these findings alone are noted on core-needle biopsy.

**Proliferative lesions without atypia** account for about 30% of biopsy results and include usual ductal hyperplasia, sclerosing adenosis, columnar hyperplasia, papilloma, and radial scar. Generally, there is a slightly increased risk of subsequent breast cancer, with a relative risk of 1.7 to 2.1.<sup>28</sup> Usual ductal hyperplasia and columnar hyperplasia have little risk of upstaging with excision, and therefore, surgical consultation is not recommended.

Previously, surgical excision was recommended for any intraductal papilloma due to risk of upgrade in pathologic diagnosis at the time of excision. However, more recent data suggest that the upgrade rate is about 2.2% for a solitary papilloma that is less than 1 cm in diameter and without associated mass lesion (either clinically or radiographically), is concordant with radiographic findings, and has no associated atypical cells on biopsy.<sup>31</sup> In this case, observation and short-interval clinical follow-up are reasonable. If there are multiple papillomas, the patient has symptoms such as persistent bloody nipple discharge, or any of the above criteria are not met, surgical excision is recommended.<sup>28</sup>

Similarly, radial scars and complex sclerosing lesions are increasingly likely to be associated with malignancy based on size. Upstaging ranges from 0% to 12%. It is again important when evaluating radial scars that there is

pathologic concordance and that there were no associated high-risk lesions on pathology. If this is the case, it is reasonable to clinically monitor patients with small radial scars, particularly in those who do not have an elevated risk of developing breast cancer.<sup>30</sup>

For all patients who have undergone biopsy and whose pathology study results are benign, a thorough risk evaluation should be performed, including calculation of their lifetime risk of breast cancer. This can be done with the National Cancer Institute Breast Cancer Risk Assessment Tool, the International Breast Cancer Intervention Study (IBIS) risk calculator, or other model using family history as a basis for calculations. Patients found to have a lifetime risk of breast cancer of greater than 20% to 25% should be offered annual screening with magnetic resonance imaging in addition to mammography.

#### ■ **ATYPICAL HYPERPLASIA: INCREASED RISK**

When biopsy study shows atypical ductal hyperplasia or atypical lobular hyperplasia, there is an increased risk of breast cancer.<sup>28,32</sup> The absolute overall risk of developing breast cancer in 25 years is 30%, and that risk is further stratified based on the number of foci of atypia noted in the specimen.<sup>29</sup>

When core-needle biopsy study reveals atypical ductal hyperplasia in the tissue, there is a 15% to 30% risk of finding breast cancer with surgical excision.<sup>28</sup> Surgical excision is therefore recommended for atypical ductal hyperplasia noted on core-needle biopsy.<sup>28</sup>

In contrast, when atypical lobular hyperplasia alone is noted, the risk of upstaging to malignancy varies widely—from 0% to 67%—although recent studies have noted risks of 1% to 3%.<sup>33,34</sup> Thus, the decision for surgical excision is more variable. Generally, if the atypical lobular hyperplasia is noted incidentally, is not associated with a higher grade lesion, and is concordant with imaging, it is reasonable to closely monitor with serial imaging and physical examination. Excision is unnecessary.<sup>35</sup>

Patients found to have atypical hyperplasia on breast biopsy should receive counseling about risk-reducing medications. Selective estrogen receptor modulators such as tamoxifen

**Nonproliferative lesions do not significantly increase the risk of breast cancer**



and raloxifene have been shown to reduce the risk of breast cancer by as much as 86% in patients with atypical hyperplasia.<sup>36</sup> Similarly,

aromatase inhibitors such as exemestane and anastrozole reduce breast cancer risk by approximately 65%.<sup>37</sup>

REFERENCES

1. Eberl MM, Phillips RL Jr, Lamberts H, Okkes I, Mahoney MC. Characterizing breast symptoms in family practice. *Ann Fam Med* 2008; 6(6):528–533. doi:10.1370/afm.905
2. Harvey JA, Mahoney MC, Newell MS, et al. ACR appropriateness criteria palpable breast masses. *J Am Coll Radiol* 2013; 10(10):742–749. e3. doi:10.1016/j.jacr.2013.06.013
3. Ha R, Kim H, Mango V, Wynn R, Comstock C. Ultrasonographic features and clinical implications of benign palpable breast lesions in young women. *Ultrasonography* 2015; 34(1):66–70. doi:10.14366/usg.14043
4. Provencher L, Hogue JC, Desbiens C, et al. Is clinical breast examination important for breast cancer detection? *Curr Oncol* 2016; 23(4):e332–e339. doi:10.3747/co.23.2881
5. Scurr J, Hedger W, Morris P, Brown N. The prevalence, severity, and impact of breast pain in the general population. *Breast J* 2014; 20(5):508–513. doi:10.1111/tbj.12305
6. Leddy R, Irshad A, Zerwas E, et al. Role of breast ultrasound and mammography in evaluating patients presenting with focal breast pain in the absence of a palpable lump. *Breast J* 2013; 19(6):582–589. doi:10.1111/tbj.12178
7. Noroozian M, Stein LF, Gaetke-Udager K, Helvie MA. Long-term clinical outcomes in women with breast pain in the absence of additional clinical findings: mammography remains indicated. *Breast Cancer Res Treat* 2015; 149(2):417–424. doi:10.1007/s10549-014-3257-3
8. Gateley CA, Miers M, Mansel RE, Hughes LE. Drug treatments for mastalgia: 17 years experience in the Cardiff Mastalgia Clinic. *J R Soc Med* 1992; 85(1):12–15. PMID:1548647
9. Fentiman IS, Caleffi M, Hamed H, Chaudary MA. Dosage and duration of tamoxifen treatment for mastalgia: a controlled trial. *Br J Surg* 1988; 75(9):845–846. PMID:3052691
10. Oksa S, Luukkaala T, Mäenpää J. Toremifene for premenstrual mastalgia: a randomised, placebo-controlled crossover study. *BJOG* 2006; 113(6):713–718. doi:10.1111/j.1471-0528.2006.00943.x
11. Mirghafourvand M, Mohammad-Alizadeh-Charandabi S, Ahmadpour P, Javadzadeh Y. Effects of Vitex agnus and flaxseed on cyclic mastalgia: a randomized controlled trial. *Complement Ther Med* 2016; 24:90–95. doi:10.1016/j.ctim.2015.12.009
12. Shobeiri F, Oshvandi K, Nazari M. Clinical effectiveness of vitamin E and vitamin B6 for improving pain severity in cyclic mastalgia. *Iran J Nurs Midwifery Res* 2015; 20(6):723–727. doi:10.4103/1735-9066.170003
13. Thicke LA, Hazelton JK, Bauer BA, et al. Acupuncture for treatment of noncyclic breast pain: a pilot study. *Am J Chin Med* 2011; 39(6):1117–1129. doi:10.1142/S0192415X11009445
14. Santen RJ, Mansel R. Benign breast disorders. *N Engl J Med* 2005; 353(3):275–285. doi:10.1056/NEJMra035692
15. Gülay H, Bora S, Kiliçturgay S, Hamaloglu E, Göksel HA. Management of nipple discharge. *J Am Coll Surg* 1994; 178(5):471–474. PMID:8167884
16. Murad TM, Contesso G, Mouriesse H. Nipple discharge from the breast. *Ann Surg* 1982; 195(3):259–264. PMID:6277258
17. Sakorafas GH. Nipple discharge: current diagnostic and therapeutic approaches. *Cancer Treat Rev* 2001; 27(5):275–282. doi:10.1053/ctrv.2001.0234
18. Ashfaq A, Senior D, Pockaj BA, et al. Validation study of a modern treatment algorithm for nipple discharge. *Am J Surg* 2014; 208(2):222–227. doi:10.1016/j.amjsurg.2013.12.035
19. Chen CY, Sun LM, Anderson BO. Paget disease of the breast: changing patterns of incidence, clinical presentation, and treatment in the US. *Cancer* 2006; 107(7):1448–1458. doi:10.1002/cncr.22137
20. Kollmorgen DR, Varanasi JS, Edge SB, Carson WE 3rd. Paget's disease of the breast: a 33-year experience. *J Am Coll Surg* 1998; 187(2):171–177. PMID:9704964
21. Hruska CB. Molecular breast imaging for screening in dense breasts: state of the art and future directions. *AJR Am J Roentgenol* 2017; 208(2):275–283. doi:10.2214/AJR.16.17131
22. Melnikow J, Fenton JJ, Whitlock EP, et al. Supplemental screening for breast cancer in women with dense breasts: a systematic review for the US Preventive Services Task Force. *Ann Intern Med* 2016; 164(4):268–278. doi:10.7326/M15-1789
23. American College of Radiology. Breast imaging reporting and data system (BI-RADS). Reston, VA: American College of Radiology; 2013.
24. Brentnall AR, Harkness EF, Astley SM, et al. Mammographic density adds accuracy to both the Tyrer-Cuzick and Gail breast cancer risk models in a prospective UK screening cohort. *Breast Cancer Res* 2015; 17(1):147. doi:10.1186/s13058-015-0653-5
25. Friedewald SM, Rafferty EA, Rose SL, et al. Breast cancer screening using tomosynthesis in combination with digital mammography. *JAMA* 2014; 311(24):2499–2507. doi:10.1001/jama.2014.6095
26. Rafferty EA, Durand MA, Conant EF, et al. Breast cancer screening using tomosynthesis and digital mammography in dense and nondense breasts. *JAMA* 2016; 315(16):1784–1786. doi:10.1001/jama.2016.1708
27. Venkatesan A, Chu P, Kerlikowske K, Sickles EA, Smith-Bindman R. Positive predictive value of specific mammographic findings according to reader and patient variables. *Radiology* 2009; 250(3):648–657. doi:10.1148/radiol.2503080541
28. Hartmann LC, Sellers TA, Frost MH, et al. Benign breast disease and the risk of breast cancer. *N Engl J Med* 2005; 353(3):229–237. doi:10.1056/NEJMoa044383
29. Hartmann LC, Degnim AC, Santen RJ, DuPont WD, Ghosh K. Atypical hyperplasia of the breast—risk assessment and management options. *N Engl J Med* 2015; 372(1):78–89. doi:10.1056/NEJMsr1407164
30. Neal L, Sandhu NP, Hieken TJ, et al. Diagnosis and management of benign, atypical, and indeterminate breast lesions detected on core needle biopsy. *Mayo Clin Proc* 2014; 89(4):536–547. doi:10.1016/j.mayocp.2014.02.004
31. Nakhlis F, Ahmadiyeh N, Lester S, Raza S, Lotfi P, Golshan M. Papilloma on core biopsy: excision vs observation. *Ann Surg Oncol* 2015; 22(5):1479–1482. doi:10.1245/s10434-014-4091-x
32. Degnim AC, Dupont WE, Radisky DC, et al. Extent of atypical hyperplasia stratifies breast cancer risk in 2 independent cohorts of women. *Cancer* 2016; 122(19):2971–2978. doi:10.1002/cncr.30153
33. Sen LQ, Berg WA, Hooley RJ, Carter GJ, Desouki MM, Sumkin JH. Core breast biopsies showing lobular carcinoma in situ should be excised and surveillance is reasonable for atypical lobular hyperplasia. *AJR Am J Roentgenol* 2016; 207(5):1132–1145. doi:10.2214/AJR.15.15425
34. Nakhlis F, Gilmore L, Gelman R, et al. Incidence of adjacent synchronous invasive carcinoma and/or ductal carcinoma in situ in patient with lobular neoplasia on core biopsy: results from a prospective multi-institutional registry (TBCRC 020). *Ann Surg Oncol* 2016; 23(3):722–728. doi:10.1245/s10434-015-4922-4
35. Racz JM, Carter JM, Degnim AC. Lobular neoplasia and atypical ductal hyperplasia on core biopsy: current surgical management recommendations. *Ann Surg Oncol* 2017; 24(10):2848–2854. doi:10.1245/s10434-017-5978-0
36. Fisher B, Costantino JP, Wickerham DL, et al. Tamoxifen for the prevention of breast cancer: report of the National Surgical Adjuvant Breast and Bowel Project P-1 Study. *J Natl Cancer Inst* 1998; 90:1371–1388. doi:10.1093/jnci/dj1372
37. Goss PE, Ingle JN, Alés-Martínez JE, et al. Exemestane for breast-cancer prevention in postmenopausal women. *N Engl J Med* 2011; 364(25):2381–2391. doi:10.1056/NEJMoa1103507

ADDRESS: Christine Lara Klassen, MD, Division of General Internal Medicine, Mayo Clinic, 200 First Street SW, Rochester, MN 55905; [klassen.christine@mayo.edu](mailto:klassen.christine@mayo.edu)