

## THE CLINICAL PICTURE

### BURKE A. CUNHA, MD, MACP

Chief, Infectious Disease Division, NYU Winthrop Hospital, Mineola, NY; Professor of Medicine, State University of New York School of Medicine, Stony Brook, NY

### NONSO OSAKWE, MD

Infectious Disease Division, NYU Winthrop Hospital, Mineola, NY

# Flu or strep? Rapid tests can mislead

A 62-YEAR-OLD WOMAN PRESENTED to our emergency department with fever, chills, hoarseness, pain on swallowing, and a painful neck. Her symptoms had begun 1 day earlier. Because acetaminophen brought no improvement, she went to an urgent care facility, where a nasal swab polymerase chain reaction test was positive for influenza A, and a throat swab rapid test was positive for group A streptococci. She was then referred to our emergency department.

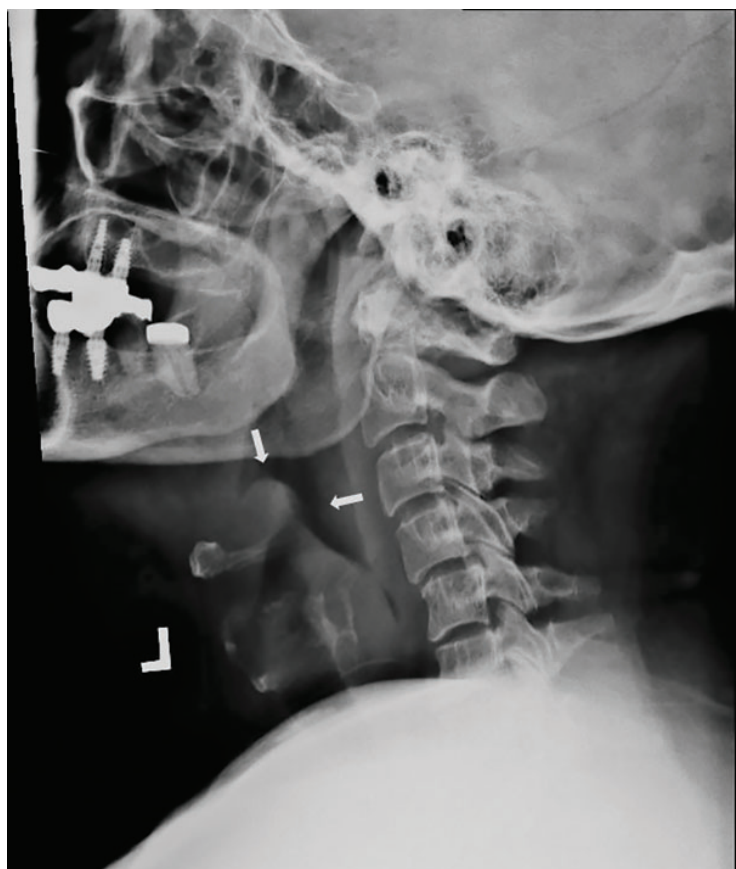
She reported no pre-existing conditions predisposing her to infection. Her temperature was 99.9°F (37.7°C), pulse 112 beats per minute, and respiratory rate 24 breaths per minute. The physical examination was unremarkable except for bilateral anterior cervical adenopathy and bilateral anterior neck tenderness. Her pharynx was not injected, and no exudate, palatal edema, or petechiae were noted.

Results of initial laboratory testing were as follows:

- White blood cell count  $20.5 \times 10^9/L$  (reference range 3.9–11)
- Neutrophils 76% (42%–75%)
- Bands 15% (0%–5%)
- Lymphocytes 3% (21%–51%)
- Erythrocyte sedimentation rate 75 mm/h (< 20 mm/h)
- C-reactive protein 247.14 mg/L ( $\leq 3$  mg/L)
- Serum aminotransferase levels were normal.
- Polymerase chain reaction testing of a nasal swab was negative for viral infection.

Throat swabs and blood samples were sent for culture.

Laryngoscopy revealed a normal oropharynx, hypopharynx, and larynx, but an



**FIGURE 1.** Enlarged epiglottis (arrows) visible on lateral neck radiography.

erythematous and edematous epiglottis with postcricoid edema. Lateral radiography of the neck revealed an enlarged epiglottis (**Figure 1**).

She was started on ceftriaxone 1 g intravenously every 24 hours, with close observation in the medical intensive care unit, where she was admitted because of epiglottitis. On hospital day 3, the throat culture was reported as

doi:10.3949/ccjm.86a.18094

negative, but the blood culture was reported as positive for *Haemophilus influenzae*. Thus, the clinical diagnosis was acute epiglottitis due to *H influenzae*, not group A streptococci.

The patient completed 10 days of ceftriaxone therapy; her recovery was uneventful, and she was discharged on hospital day 10.

### INFLUENZA: CHALLENGES TO PROMPT, ACCURATE DIAGNOSIS

During influenza season, emergency departments are inundated with adults with influenza A and other viral respiratory infections. This makes prompt, accurate diagnosis a challenge,<sup>1</sup> given the broad differential diagnosis.<sup>2,3</sup> Adults with influenza and its complications as well as unrelated conditions can present a special challenge.<sup>4</sup>

Our patient presented with acute-onset influenza A and was then found to have acute epiglottitis, an unexpected complication of influenza A.<sup>5</sup> A positive rapid test for group A streptococci done at an urgent care facility led

emergency department physicians to assume that the acute epiglottitis was due to group A streptococci. Unless correlated with clinical findings, results of rapid diagnostic tests may mislead the unwary practitioner. Accurate diagnosis should be based mainly on the history and physical findings. Results of rapid diagnostic tests can be helpful if interpreted in the clinical context.<sup>6-8</sup>

The rapid test for streptococci is appropriate for the diagnosis of pharyngitis due to group A streptococci in people under age 30 with acute-onset sore throat, fever, and bilateral acute cervical adenopathy, without fatigue or myalgias. However, the rapid test does not differentiate colonization from infection. Group A streptococci are common colonizers with viral pharyngitis. In 30% of cases of Epstein-Barr virus pharyngitis, there is colonization with group A streptococci. A positive rapid test in such cases can result in the wrong diagnosis, ie, pharyngitis due to group A streptococci rather than Epstein-Barr virus.

### REFERENCES

1. **Cunha BA.** The clinical diagnosis of severe viral influenza A. *Infection* 2008; 36(1):92–93. doi:10.1007/s15010-007-7255-9
2. **Cunha BA, Klein NC, Strollo S, Syed U, Mickail N, Laguerre M.** Legionnaires' disease mimicking swine influenza (H1N1) pneumonia during the "herald wave" of the pandemic. *Heart Lung* 2010; 39(3):242–248. doi:10.1016/j.hrtlng.2009.10.009
3. **Cunha BA, Raza M.** During influenza season: all influenza-like illnesses are not due to influenza: dengue mimicking influenza. *J Emerg Med* 2015; 48(5):e117–e120. doi:10.1016/j.jemermed.2014.12.051
4. **Cunha CB.** Infectious disease differential diagnosis. In: Cunha CB, Cunha BA, eds. *Antibiotic Essentials*. Jaypee Brothers Medical Pub: New Delhi, India; 2017:493–526.
5. **Cunha BA.** Pharyngitis. In: Cunha CB, Cunha BA, eds. *Antibiotic Essentials*. Jaypee Brothers Medical Pub: New Delhi, India; 2017:42–47.
6. **Cohen JF, Chalumeau M, Levy C, et al.** Effect of clinical spectrum, inoculum size and physician characteristics on sensitivity of rapid antigen detection test for group A streptococcal pharyngitis. *Eur J Clin Microbiol Infect Dis* 2013; 32(6):787–793. doi:10.1007/s10096-012-1809-1
7. **Dimatteo LA, Lowenstein SR, Brimhall B, Reiquam W, Gonzales R.** The relationship between the clinical features of pharyngitis and the sensitivity of a rapid antigen test: evidence of spectrum bias. *Ann Emerg Med* 2001; 38(6):648–652. doi:10.1067/mem.2001.119850
8. **Cunha BA.** A positive rapid strep test in a young adult with acute pharyngitis: be careful what you wish for! *IDCases* 2017; 10:58–59. doi:10.1016/j.idcr.2017.08.012

ADDRESS: Burke A. Cunha, MD, MACP, Infectious Disease Division, NYU Winthrop Hospital, 222 Station Plaza North (Suite #432), Mineola, NY 11501; burke.cunha@nyuwinthrop.org