

GREGORY W. RUTECKI, MD, Section Editor

WILLIAM C. LIPPERT, MD, MPH

Instructor of Internal Medicine, Department of Internal Medicine, Section of Hospital Medicine, Wake Forest Baptist Medical Center, Winston-Salem, NC

EUN Y. LEE, MD

Professor and Director of Anatomic Pathology, Department of Pathology and Laboratory Medicine, University of Kentucky Medical Center, Lexington, KY

AIBEK E. MIRRAKHIMOV, MD

Assistant Professor of Medicine, Division of Hospital Medicine, University of Kentucky Medical Center, Lexington, KY

A woman, age 35, with new-onset ascites

A 35-YEAR-OLD woman is admitted to the hospital with a 5-day history of abdominal distention and jaundice. She reports no history of fever, chills, night sweats, abdominal pain, nausea, vomiting, diarrhea, changes in urine color, change in stool color, weight loss, weight gain, or loss of appetite.

She is petite, with a body mass index of 19.4 kg/m². She has no known history of medical conditions or surgery and is not taking any medications. Her family history is unremarkable, and she denies current or past tobacco, alcohol, or illicit drug use.

RECENT TRAVEL

She says that during a trip to Central America several months ago, she had suffered a seizure and was taken to a local hospital, where laboratory testing revealed elevated aspartate aminotransferase (AST) and alanine aminotransferase (ALT) levels. She says that the rest of the workup at that time was normal.

About 1 week after that incident, she returned home and saw her primary care physician, who ordered further testing, which showed mild hyperbilirubinemia and mild elevation of AST and ALT levels. Her physician attributed the elevations to atovaquone, which she had been taking for malaria prophylaxis, as repeat testing 2 weeks later showed improvement in AST and ALT levels.

The patient says she returned to her normal state of health until about 5 days ago, when she noticed jaundice and abdominal distention, but without abdominal pain, dark urine, or clay-colored stools. She became concerned and went to her local hospital. Testing there

noted mild elevation of AST and ALT, as well as an elevated international normalized ratio (INR) and hyperbilirubinemia. Computed tomography of the abdomen and pelvis showed hepatomegaly with possible fatty liver. Because of these results, the patient was transferred to our institution for further evaluation.

EVALUATION AT OUR INSTITUTION

On examination at our institution, she is afebrile, and vital signs are within normal ranges. She has bilateral scleral icterus and diffuse jaundice, but no other skin finding such as rash or spider angioma. She has no lymphadenopathy. Her abdomen is distended, with tense ascites, and her liver is tender to palpation. The tip of the spleen is not palpable.

The cardiovascular examination reveals no murmurs, rubs, or gallops, but she has jugular venous distention and +2 pitting edema of both lower extremities.

On respiratory examination, there is dullness to percussion, with slight crackles on auscultation at the right lung base. The neurological examination is normal.

Table 1 shows the results of initial laboratory testing.

1 Which study would provide the most information on the cause of ascites?

- ☐ Abdominal ultrasonography
- ☐ Abdominal paracentesis with ascitic fluid analysis
- ☐ Chest radiography
- ☐ Echocardiography
- ☐ Urine protein-to-creatinine ratio

Abdominal paracentesis with ascitic fluid analysis is the essential study for any patient

A serum-ascites albumin gradient ≥ 1.1 g/dL indicates portal hypertension

doi:10.3949/ccjm.86a.17082

TABLE 1

Results of initial laboratory testing

Test	Result ^a	Reference range
White blood cell count	17.3 x 10⁹/L	(3.7–10.3)
Neutrophil count	82%	
Hemoglobin	8.8 g/dL	(11.2–15.7)
Hematocrit	24.0%	(34%–45%)
Platelet count	112 x 10⁹/L	(155–369)
Sodium	128 mmol/L	(136–145)
Potassium	3.2 mmol/L	(3.7–4.8)
Chloride	86 mg/dL	(101–108)
Blood urea nitrogen	16 mg/dL	(7–21)
Creatinine	0.62 mg/dL	(0.60–1.10)
Glucose	91 mg/dL	(74–99)
Aspartate aminotransferase	97 U/L	(11–32)
Alanine aminotransferase	24 U/L	(8–33)
Alkaline phosphatase	224 U/L	(35–104)
Gamma-glutamyltransferase	996 U/L	(7–36)
Total bilirubin	17.0 mg/dL	(0.2–1.1)
Total protein	4.9 g/dL	(6.3–7.9)
Albumin	2.2 g/dL	(3.3–4.6)
Total calcium	7.3 mg/dL	(8.9–10.2)
Erythrocyte sedimentation rate	16 mm/h	(0–20)
C-reactive protein	4.2 mg/dL	(0–0.9)
Brain natriuretic protein	445 pg/mL	(0–449)
Alpha-1 antitrypsin	2.8 ng/mL	(0.9–9.0)
Ceruloplasmin	30 mg/dL	(18–53)
Ferritin	302 ng/dL	(13–150)
Hepatitis panel (A, B, C)	Negative	
Prothrombin time	20.2 sec	(12.3–14.8)
International normalized ratio	1.7 sec	(0.9–1.1)
Partial thromboplastin time	38 sec	(25–36)
Thyroid-stimulating hormone	3.9 µU/mL	(0.4–4.2)

^aAbnormal results in boldface type.

with clinically apparent new-onset ascites.^{1–3} It is the study that provides the most information on the cause of ascites.

In our patient, abdominal paracentesis yields 1,000 mL of straw-colored ascitic fluid, and analysis shows 86 nucleated cells, 28 of which are polymorphonuclear cells, and 0 red blood cells, with negative Gram stain and culture. The ascitic albumin level is 0.85 g/dL, with an ascitic protein of 1.1 g/dL.

Abdominal ultrasonography shows a diffusely echogenic liver, no focal lesions, moderate ascites, normal portal vein flow, no intrahepatic or extrahepatic biliary duct dilation,

normal kidney sizes, no hydronephrosis, and no intra-abdominal mass. Chest radiography is clear with no sign of consolidation, edema, or effusion. Echocardiography shows a normal left ventricular ejection fraction with no valvular disease or pericardial effusion. A random urine protein-creatinine ratio is normal at 0.1 (reference range < 0.2).

2 What is the most likely cause of her ascites based on the workup to this point?

- ☐ Cirrhosis
- ☐ Heart failure
- ☐ Nephrotic syndrome
- ☐ Portal vein thrombus
- ☐ Abdominal malignancy
- ☐ Malaria

An initial approach to ascitic fluid analysis is to calculate the serum-ascites albumin gradient (SAAG). The SAAG is calculated as the serum albumin level minus the ascitic fluid albumin level.^{4,5} This is useful in determining the cause of the ascites (**Figure 1**).^{4,5} A gradient of 1.1 g/dL or higher indicates portal hypertension.^{4,5}

Common causes of portal hypertension include cirrhosis, alcoholic hepatitis, heart failure, vascular occlusion syndromes (eg, Budd-Chiari syndrome, portal vein thrombosis), idiopathic portal fibrosis, and metastatic liver disease.^{5,6}

If portal hypertension is present based on the SAAG, the next step is to review the ascitic protein level to help distinguish between a hepatic and a cardiac etiology of the ascites. An ascitic protein level less than 2.5 g/dL indicates a primary liver pathology (eg, cirrhosis). An ascitic protein level of 2.5 g/dL or greater typically indicates a cardiac condition (eg, heart failure, pericardial disease) with secondary congestive hepatopathy.^{5,6}

If the SAAG is less than 1.1 g/dL, the ascites is likely not from portal hypertension. Typical causes of a low SAAG include infection, malignancy, pancreatic ascites, and nephrotic syndrome.^{5,6}

In our patient, the SAAG is 1.35 g/dL (2.2 g/dL minus 0.85 g/dL), ie, elevated and due to portal hypertension. With an SAAG of 1.1 g/dL or greater and an ascitic fluid protein level less than 2.5 g/dL, as in our patient, the most likely cause is cirrhosis.

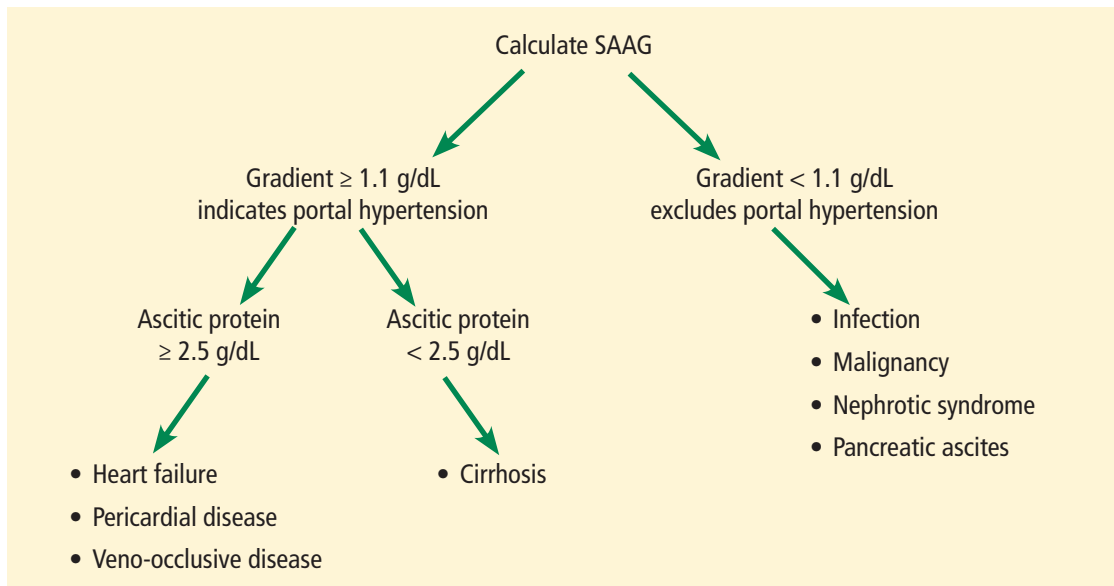


Figure 1. Interpreting the serum-ascites albumin gradient (SAAG) and ascitic protein levels.

Heart failure is unlikely based on her normal brain natriuretic peptide level, an ascitic fluid protein level below 2.5 g/dL, and normal results on echocardiography. Nephrotic syndrome is also very unlikely based on the patient's normal random urine protein-creatinine ratio. Portal vein thrombus and abdominal malignancy are essentially ruled out by the negative results of Doppler abdominal ultrasonography, with normal venous flow and no intra-abdominal mass and coupled with an elevated SAAG.

Although the patient has a history of travel, the incubation period for malaria would not fit the time frame of presentation. Also, she did not have typical malarial symptoms, her rapid malaria test was negative, and a peripheral blood smear for blood parasites was negative. It should be noted, however, that *Plasmodium malariae* infection classically presents with flulike symptoms and can resemble nephrotic syndrome, including peripheral edema, ascites, heavy proteinuria, hypoalbuminemia, and hyperlipidemia.⁷

3 In which patients is antibiotic prophylaxis against spontaneous bacterial peritonitis (SBP) appropriate?

- ☐ Any patient with cirrhosis
- ☐ Any patient with cirrhosis who is hospitalized

- ☐ Any patient with cirrhosis and an ascitic fluid protein level below 2.0 g/dL
- ☐ Any patient with cirrhosis and a history of SBP

Any patient with cirrhosis and a history of SBP should receive prophylactic antibiotics,⁸ as should any patient deemed at high risk of SBP. It is indicated in the following patients:

- Patients with cirrhosis and gastrointestinal bleeding^{9,10}
- Patients with cirrhosis and a previous episode of SBP⁸
- Patients with cirrhosis and an ascitic fluid protein level less than 1.5 g/dL with either impaired renal function (creatinine ≥ 1.2 mg/dL, blood urea nitrogen level ≥ 25 mg/dL, or serum sodium ≤ 130 mmol/L) or liver failure (Child-Pugh score ≥ 9 and a bilirubin ≥ 3 mg/dL)⁹
- Patients with cirrhosis who are hospitalized for other reasons and have an ascitic protein level < 1.0 g/dL.⁹

Our patient has no signs or symptoms of gastrointestinal bleeding and no history of SBP. Her ascitic fluid protein level is 1.1 g/dL, and she has normal renal function. However, her Child-Pugh score is 12 (3 points for total bilirubin > 3 mg/dL, 3 points for serum albumin < 2.8 g/dL, 2 points for an INR 1.7 to 2.2, 3 points for moderate ascites, and 1 point for no encephalopathy),

Transjugular biopsy confirmed alcoholic hepatitis, despite the patient's initial denial of alcohol use

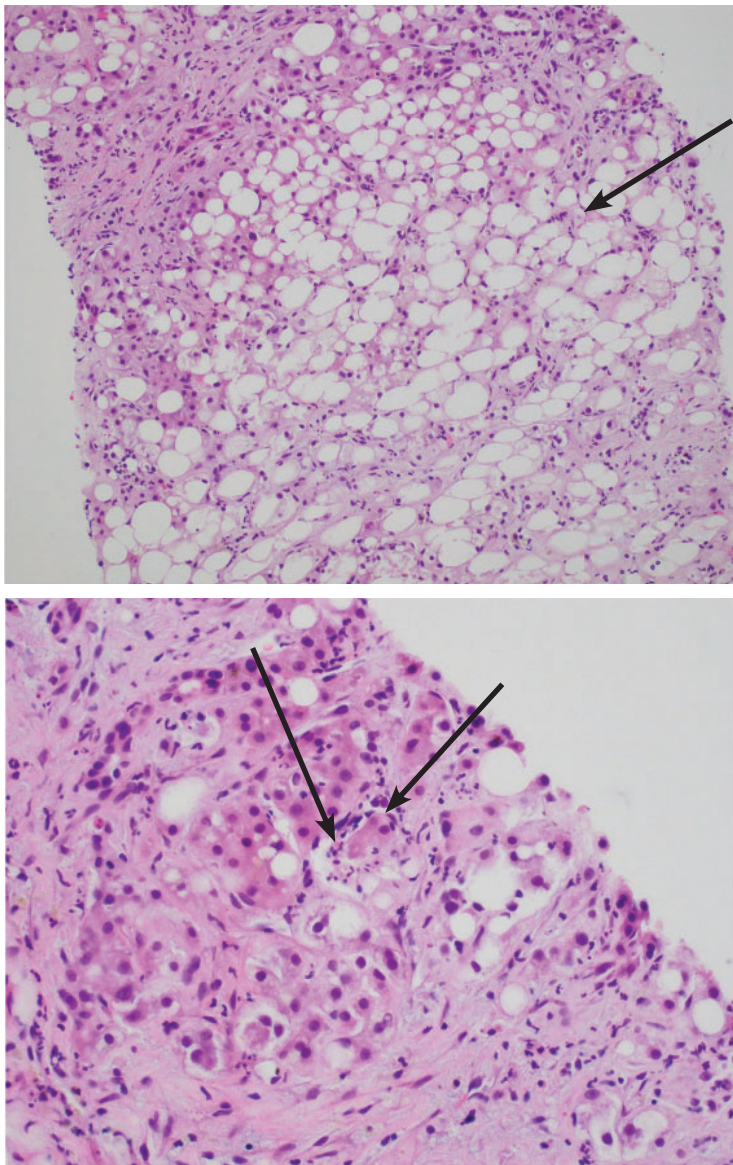


Figure 2. Transjugular biopsy study (top) shows severe steatosis from lipid accumulation in hepatocytes (arrow) (hematoxylin and eosin, $\times 100$). Higher magnification (bottom) shows inflammatory cells (neutrophils, arrows) surrounding Mallory-Denk bodies, which are hyaline (eosinophilic) inclusions (hematoxylin and eosin, $\times 400$).

with a bilirubin of 17.0 mg/dL. Based on this, she is placed on antibiotic prophylaxis for SBP.

Our patient then undergoes an extensive workup for liver disease. Results of tests for toxins, autoimmune diseases, and inheritable diseases are all within normal limits. At this point, despite the patient's reported negative alcohol history, our leading diagnosis is alcoholic hepatitis.

To confirm this diagnosis, she subsequently undergoes transjugular liver biopsy, considered the gold standard for the diagnosis of alcoholic hepatitis. During the procedure, the hepatic venous pressure gradient is measured at 18 mm Hg (reference range 1–5 mm Hg), suggestive of portal hypertension. The pathology study shows severe fatty change, active steatohepatitis with ballooning degeneration, easily identifiable Mallory-Denk bodies, and prominent neutrophilic infiltration, as well as extensive bridging fibrosis (**Figure 2**). These findings point to alcoholic hepatitis.

After the biopsy results, we speak with the patient further about her alcohol habits. At this point, she informs us that she has consumed significant amounts of alcohol since the age of 18 (6 to 12 alcoholic beverages per day, including beer and hard liquor). Therefore, based on this new information, on her jaundice and ascites, and on results of laboratory testing and biopsy, we confirmed our diagnosis of alcoholic hepatitis.

4 When is drug treatment appropriate for alcoholic hepatitis?

- ☐ Model for End-stage Liver Disease (MELD) score greater than 12
- ☐ MELD score greater than 15
- ☐ Maddrey Discriminant Function score greater than 25
- ☐ Maddrey Discriminant Function score greater than 32
- ☐ Glasgow score greater than 5
- ☐ Glasgow score greater than 7

The best answer is a Maddrey Discriminant Function score greater than 32. A variety of scoring systems have been used to assess the severity of alcoholic hepatitis and to guide treatment, including the Maddrey Discriminant Function score, the MELD score, and the Glasgow score.^{11–16} They share similar laboratory values in their calculations, including prothrombin time (or INR) and total bilirubin.^{11–16} Typically, a Maddrey Discriminant Function score greater than 32, a Glasgow score of greater than 9, or a MELD score greater than 21 is used to determine whether pharmacologic treatment is indicated.^{11–16}

The typical treatment is prednisolone or pentoxifylline.^{11,17–21} The Lille score is de-

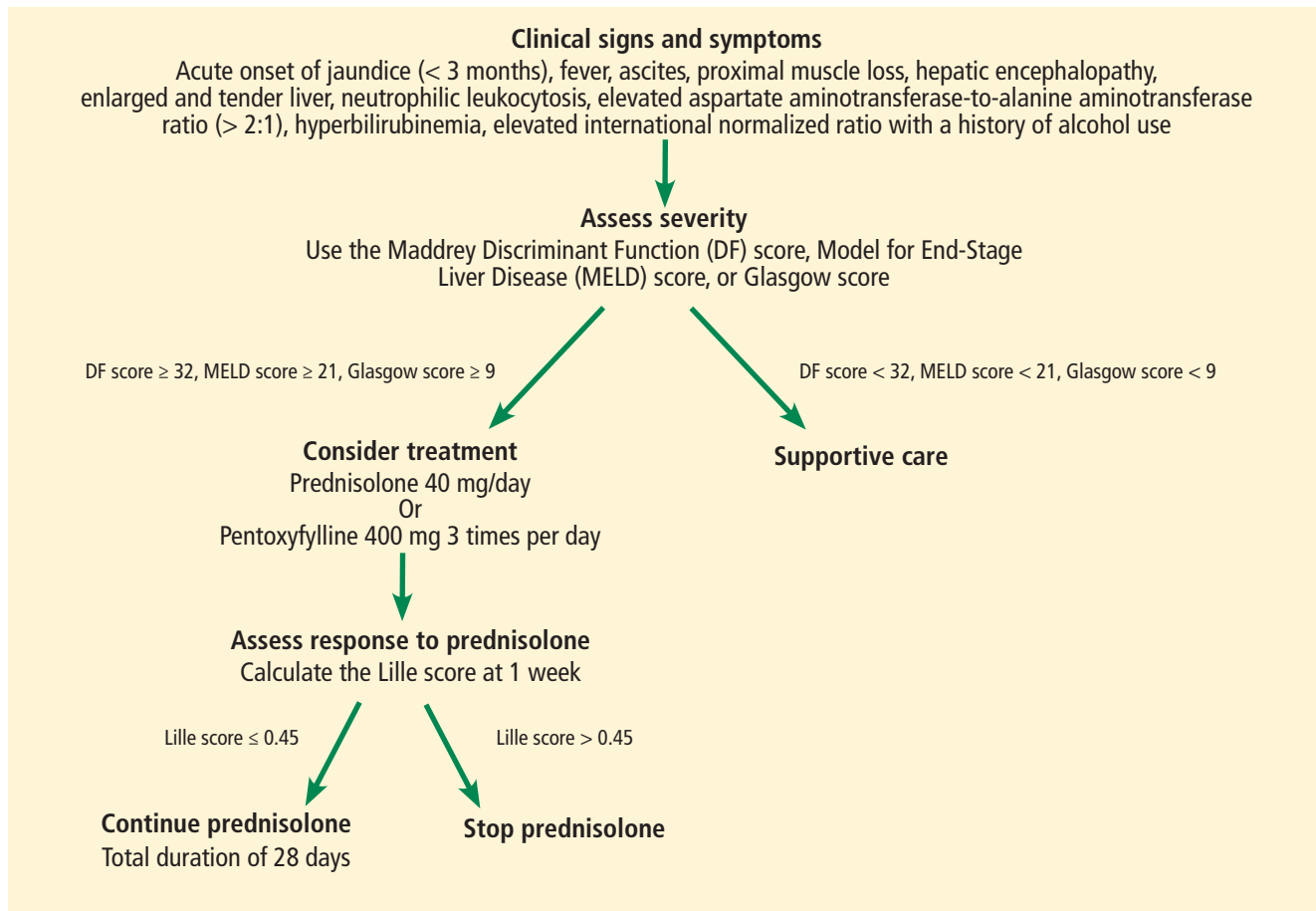


Figure 3. Algorithm for the management of alcoholic hepatitis.

signed to help decide whether to stop corticosteroids after 1 week of administration due to lack of treatment response.²² It predicts mortality rates within 6 months; a score of 0.45 or less indicates a good prognosis, and corticosteroid therapy should continue for 28 days (Figure 3).²²

Our patient's discriminant function score is 50, her Glasgow score is 10, and her MELD score is 28; thus, she begins treatment with oral prednisolone. Her Lille score at 1 week is 0.119, indicating a good prognosis, and her corticosteroids are continued for a total of 28 days.

It should be highlighted that the most important treatment is abstinence from alcohol.¹¹ Recent literature suggests that any benefit of prednisolone or pentoxifylline in terms of mortality rates is questionable,^{19–20} and there is evidence that giving both drugs simultaneously may improve mortality rates,^{11,21} but the evidence remains conflicting at this time.

ALCOHOLIC HEPATITIS

Alcoholic hepatitis is a clinical syndrome of jaundice and liver failure, often in the setting of heavy alcohol use for decades.^{11,12} The incidence is unknown, but the typical age of presentation is between 40 and 50.^{11,12} The chief sign is a rapid onset of jaundice (< 3 months); common signs and symptoms include fever, ascites, proximal muscle loss, and an enlarged, tender liver.¹² Encephalopathy may be seen in severe alcoholic hepatitis.¹²

Our patient is 35 years old. She has jaundice with rapid onset, as well as ascites and a tender liver.

The diagnosis of alcoholic hepatitis must take into account the patient's history, physical examination, and laboratory findings. Until proven otherwise, the diagnosis should be presumed in the following scenario: ascites and jaundice on examination (usually with a duration < 3 months); a history of heavy al-

cohol use; neutrophilic leukocytosis; an AST level that is elevated but below 300 U/L; an ALT level above the normal range but below 300 U/L; an AST-ALT ratio greater than 2; a total serum bilirubin level above 5 mg/dL; and an elevated INR.^{11,12} Liver biopsy is the gold standard for diagnosis. Though not routinely done because of risks associated with the procedure, it may help confirm the diagnosis if it is in question.

CASE CONCLUDED

We start our patient on oral prednisolone 40 mg daily for alcoholic hepatitis. Her symp-

toms and laboratory testing results including bilirubin improve. Her Lille score at 7 days indicates a good prognosis, prompting continuation of corticosteroid treatment for the full 28 days.

She is referred to an outpatient alcohol rehabilitation program and has remained sober as of the last outpatient note.

Alcoholic hepatitis is extremely difficult to diagnose, and no single blood test or imaging study confirms the diagnosis. The history, physical examination findings, and laboratory findings are crucial. If the diagnosis is still in doubt, liver biopsy may help confirm the diagnosis. ■

REFERENCES

- Ruyon BA; AASLD Practice Guidelines Committee. Management of adult patients with ascites due to cirrhosis: an update. *Hepatology* 2009; 49(6):2087–2107. doi:10.1002/hep.22853
- Hoefs JC, Canawati HN, Sapico FL, Hopkins RR, Weiner J, Montgomerie JZ. Spontaneous bacterial peritonitis. *Hepatology* 1982; 2(4):399–407. PMID:7095741
- Ginès P, Cárdenas A, Arroyo V, Rodés J. Management of cirrhosis and ascites. *N Engl J Med* 2004; 350(16):1646–1654. doi:10.1056/NEJMra035021
- Runyon BA, Montano AA, Akriviadis EA, Antillon MR, Irving MA, McHutchison JG. The serum-ascites albumin gradient is superior to the exudate-transudate concept in the differential diagnosis of ascites. *Ann Intern Med* 1992; 117(3):215–220. PMID:1616215
- Hernaez R, Hamilton JP. Unexplained ascites. *Clin Liver Dis* 2016; 7(3):53–56. <https://aasldpubs.onlinelibrary.wiley.com/doi/epdf/10.1002/cld.537>
- Huang LL, Xia HH, Zhu SL. Ascitic fluid analysis in the differential diagnosis of ascites: focus on cirrhotic ascites. *J Clin Transl Hepatol* 2014; 2(1):58–64. doi:10.14218/JCTH.2013.00010
- Bartoloni A, Zammarchi L. Clinical aspects of uncomplicated and severe malaria. *Mediterr J Hematol Infect Dis* 2012; 4(1):e2012026. doi:10.4084/MJHID.2012.026
- Titó L, Rimola A, Ginès P, Llach J, Arroyo V, Rodés J. Recurrence of spontaneous bacterial peritonitis in cirrhosis: frequency and predictive factors. *Hepatology* 1988; 8(1):27–31. PMID:3257456
- Fernández J, Ruiz del Arbol L, Gómez C, et al. Norfloxacin vs ceftriaxone in the prophylaxis of infections in patients with advanced cirrhosis and hemorrhage. *Gastroenterology* 2006; 131(4):1049–1056. doi:10.1053/j.gastro.2006.07.010
- Runyon B; The American Association for the Study of Liver Diseases (AASLD). Management of adult patients with ascites due to cirrhosis: update 2012. https://www.aasld.org/sites/default/files/guideline_documents/141020_Guideline_Ascites_4UFb_2015.pdf. Accessed September 4, 2018.
- Sidhu SS, Goyal O, Kishore H, Sidhu S. New paradigms in management of alcoholic hepatitis: a review. *Hepatol Int* 2017; 11(3):255–267. doi:10.1007/s12072-017-9790-5
- Lucey MR, Mathurin P, Morgan TR. Alcoholic hepatitis. *N Engl J Med* 2009; 360(26):2758–2769. doi:10.1056/NEJMra0805786
- Maddrey WC, Boitnott JK, Bedine MS, Weber FL Jr, Mezey E, White RI Jr. Corticosteroid therapy of alcoholic hepatitis. *Gastroenterology* 1978; 75(2):193–199. PMID:352788
- Forrest EH, Evans CD, Stewart S, et al. Analysis of factors predictive of mortality in alcoholic hepatitis and derivation and validation of the Glasgow alcoholic hepatitis score. *Gut* 2005; 54(8):1174–1179. doi:10.1136/gut.2004.050781
- Dunn W, Jamil LH, Brown LS, et al. MELD accurately predicts mortality in patients with alcoholic hepatitis. *Hepatology* 2005; 41(2):353–358. doi:10.1002/hep.20503
- Sheth M, Riggs M, Patel T. Utility of the Mayo end-stage liver disease (MELD) score in assessing prognosis of patients with alcoholic hepatitis. *BMC Gastroenterol* 2002; 2:2. PMID:11835693
- Akriviadis E, Botla R, Briggs W, Han S, Reynolds T, Shakil O. Pentoxifylline improves short-term survival in severe acute alcoholic hepatitis: a double-blind, placebo-controlled trial. *Gastroenterology* 2000; 119(6):1637–1648. PMID:11113085
- Mathurin P, O'Grady J, Carithers RL, et al. Corticosteroids improve short-term survival in patients with severe alcoholic hepatitis: meta-analysis of individual patient data. *Gut* 2011; 60(2):255–260. doi:10.1136/gut.2010.224097
- Thursz MR, Richardson P, Allison M, et al; STOPAH Trial. Prednisolone or pentoxifylline for alcoholic hepatitis. *N Engl J Med* 2015; 372(17):1619–1628. doi:10.1056/NEJMoa1412278
- Thursz M, Forrest E, Roderick P, et al. The clinical effectiveness and cost-effectiveness of steroids or pentoxifylline for alcoholic hepatitis (STOPAH): a 2 × 2 factorial randomised controlled trial. *Health Technol Assess* 2015; 19(102):1–104. doi:10.3310/hta191020
- Lee YS, Kim HJ, Kim JH, et al. Treatment of severe alcoholic hepatitis with corticosteroid, pentoxifylline, or dual therapy: a systematic review and meta-analysis. *J Clin Gastroenterol* 2017; 51(4):364–377. doi:10.1097/MCG.0000000000000674
- Louvet A, Naveau S, Abdelnour M, et al. The Lille model: a new tool for therapeutic strategy in patients with severe alcoholic hepatitis treated with steroids. *Hepatology* 2007; 45(6):1348–1354. doi:10.1002/hep.21607

ADDRESS: William C. Lippert, MD, MPH, Section of Hospital Medicine, Department of Internal Medicine, Wake Forest Baptist Medical Center, 1 Medical Center Boulevard, Winston-Salem, NC 27157; wlippert@wakehealth.edu