

Renato V. Samala, MD, MHPE, FACP, FAAHPM

Department of Palliative and Supportive Care, Taussig Cancer Institute, Cleveland Clinic, Cleveland, OH; Assistant Professor, Cleveland Clinic Lerner College of Medicine of Case Western Reserve University, Cleveland, OH

Ruth L. Lagman, MD, MPH, MBA, FACP, FAAHPM

Department of Palliative and Supportive Care, Taussig Cancer Institute, Cleveland Clinic, Cleveland, OH; Clinical Assistant Professor, Cleveland Clinic Lerner College of Medicine of Case Western Reserve University, Cleveland, OH

Sina Najafi, DO

Staff Physician, Supportive and Palliative Care, Baylor Scott & White Health, Dallas, TX

Flannery Fielding, CNP, MSN

Department of Palliative and Supportive Care, Taussig Cancer Institute, Cleveland Clinic, Cleveland, OH

Frequently asked questions about managing cancer pain: An update

ABSTRACT

Most patients with cancer experience pain at some point in the disease course due to the disease itself or its treatment, or both. Pain management can involve pharmacologic (nonopioid medications, adjuvants, and opioids) and nonpharmacologic (radiation therapy, interventional procedures) therapies. This article provides a treatment approach to reduce pain for patients with cancer and improve their quality of life.

KEY POINTS

Cancer pain affects patients throughout the disease trajectory.

The typical pharmacologic regimen for treating patients with cancer pain consists of an assortment of nonopioid analgesics, adjuvant pain medications, and opioids.

Early consideration of radiation therapy and various interventional pain management procedures can optimize pain control and preclude escalation of opioids.

New or worsening pain in patients with a history of cancer requires thorough assessment for cancer recurrence or progression.

CANCER-RELATED PAIN, resulting from the disease itself, its treatment, or both, is one of the disease's most agonizing symptoms, severely diminishing quality of life. A review of 52 studies published from 2005 to 2014, with 32,261 patients, concluded that 50.7% of patients with cancer experienced pain.¹ In those who completed curative treatment, the prevalence of pain was 39.3%, in those receiving anticancer therapy it was 55%, and in those with advanced, metastatic or terminal disease it was 66.4%.

Because cancer-related pain occurs throughout the course of the disease, primary care providers are likely to be called on to manage cancer pain, either in the outpatient or inpatient setting. Whether the provider is caring for a patient around the time of diagnosis, during treatment, at the terminal phase, or in survivorship, effective treatment of cancer pain helps patients achieve optimal quality of life. Knowledge of therapeutic approaches and both pharmacologic and nonpharmacologic alternatives may also assist clinicians in treating patients before partnering with specialists, such as those in oncology, palliative medicine, and pain management.

In an earlier article in this journal, Induru and Lagman² stressed that effectively managing cancer pain can lead to overall improvement in patient satisfaction and quality of life. They explored the use of drugs such as opioids and adjuvant pain medications and nonpharmacologic measures such as acupuncture, massage therapy, and music therapy. This article builds on the previous review and features novel drugs and

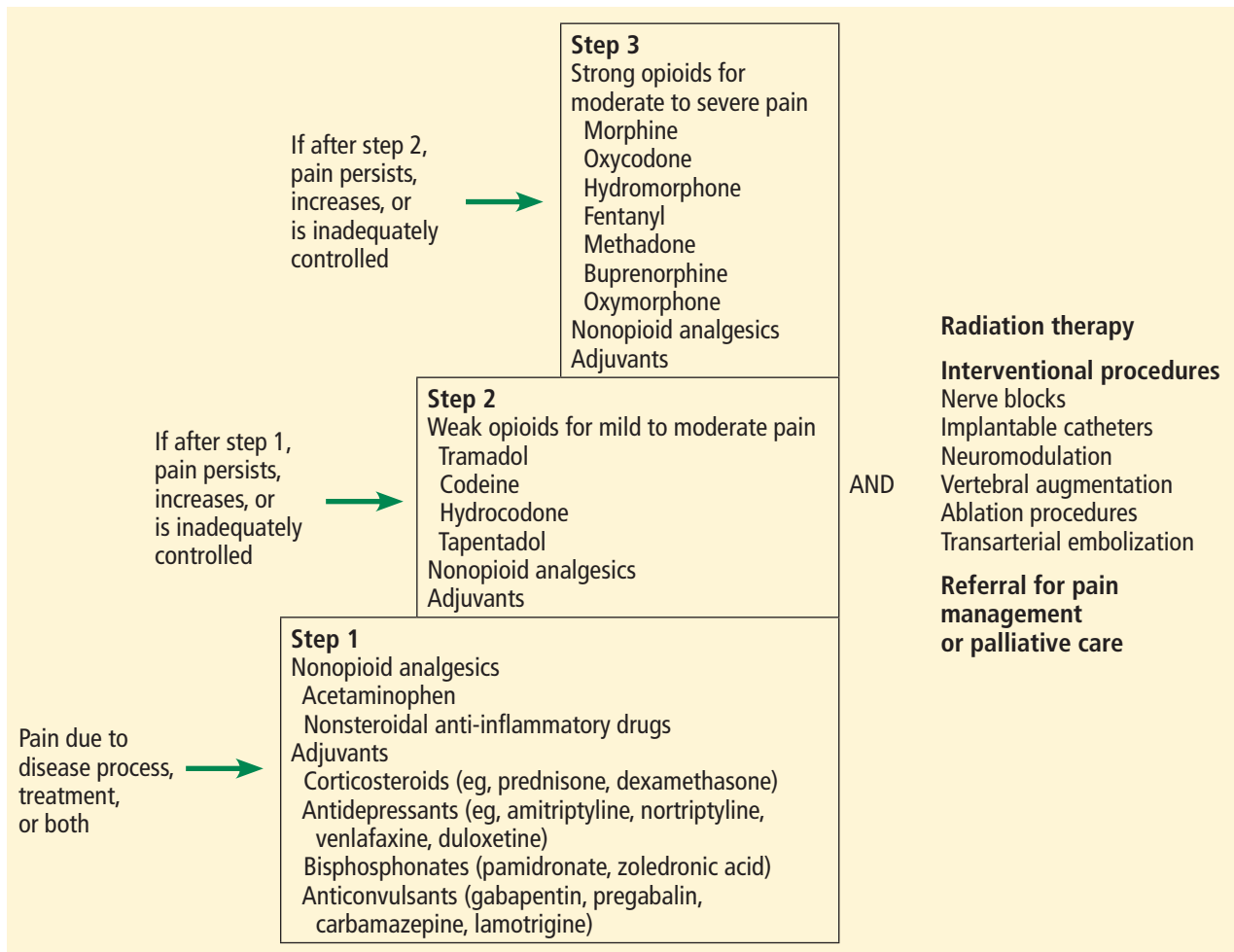


Figure 1. Our approach to managing cancer pain, based on the World Health Organization analgesic ladder.

other, nonpharmacologic interventions available for patients with cancer. It also examines pain management in cancer survivors.

■ WHAT ARE THE KEY PRINCIPLES IN MANAGING CANCER PAIN?

Cancer pain management often involves both drugs and procedures (Figure 1). The most commonly used framework that clinicians can employ in deciding which analgesic drugs to use is the World Health Organization (WHO) analgesic ladder.^{2,3}

At the base, or step 1, of the 3-step ladder are nonopioid analgesics (eg, acetaminophen, nonsteroidal anti-inflammatory drugs) and adjuvants, which are used for mild pain. Adjuvants are drugs that are primarily indicated for conditions other than pain but that possess analgesic

properties; they include corticosteroids (eg, prednisone, dexamethasone), antidepressants (eg, amitriptyline, nortriptyline, venlafaxine), bisphosphonates (eg, pamidronate, zoledronic acid), and anticonvulsants (eg, gabapentin, pregabalin, carbamazepine, lamotrigine).

If pain persists or increases, weak opioids for mild to moderate pain (eg, tramadol, codeine, hydrocodone) are added in step 2. If pain remains uncontrolled, strong opioids for moderate to severe pain (eg, morphine, oxycodone, hydromorphone, fentanyl, methadone, buprenorphine) are used in step 3.

At any stage, when cancer pain persists, escalates, or remains inadequately controlled, clinicians should consider specific nonpharmacologic interventions, which will be discussed below. Providers of ancillary services—nursing, social work, physical and occupational therapy,

spiritual care—may need to be called in. Similarly, specialists from fields such as radiation oncology, palliative medicine, pain management, anesthesiology, interventional radiology, surgery, and orthopedics may be essential in optimizing pain control. We recommend collaborating with specialists in either palliative medicine or pain management when step 1 of the WHO analgesic ladder fails to provide ample relief, especially for providers who are uncomfortable prescribing opioids.

■ WHAT ARE SOME OF THE NONOPIOID MEDICATIONS USED FOR CANCER PAIN?

Duloxetine, an antidepressant

Duloxetine, a serotonin-norepinephrine reuptake inhibitor, is primarily used to treat depression and anxiety, but it is increasingly finding a place in the treatment of diabetic neuropathy, fibromyalgia, chronic back pain, and osteoarthritic pain.⁴⁻⁶ Recent studies suggest that duloxetine, alone or in combination with opioids and gabapentinoids (eg, gabapentin, pregabalin), also offers benefit in 2 cancer-related pain conditions, chemotherapy-induced peripheral neuropathy and cancer-related neuropathic pain.^{7,8}

The dosing used in studies ranged from 20 to 60 mg per day. Common adverse effects are nausea, fatigue, and both insomnia and somnolence.

Cannabinoids are not recommended

The 2 most prominent and abundant cannabinoids—compounds derived from the *Cannabis sativa* plant—are tetrahydrocannabinol (THC) and cannabidiol (CBD). Preparations of cannabinoids that patients can access generally come in 3 forms:

- THC-dominant, eg, oral dronabinol and nabilone
- Balanced THC-CBD, such as oromucosal nabiximols
- CBD-dominant, such as oral CBD oil solution.⁹

Medical cannabis or marijuana preparations of all of these 3 forms are available and can be taken by various routes, such as by mouth, inhaled, or topical application.

Cannabinoids have been studied for the treatment of several cancer symptoms, notably pain, anorexia, nausea, and dysgeusia. Five randomized controlled trials from 2012 to 2018 were part of a systematic review of can-

nabis-based medicines for cancer pain published in 2019.¹⁰ The review concluded that neither balanced THC-CBD nor THC-dominant preparations differ from placebo in reducing pain. Adverse effects of cannabinoids noted in studies include dizziness, dry mouth, nausea and vomiting, somnolence, confusion, and memory impairment.^{9,10} Of note, nabiximols, the cannabinoid most studied for treating cancer pain, is not currently available in the United States.

The lack of quality evidence, access issues, and worrisome side effects preclude the use of cannabinoids for cancer pain at this time.

Acetaminophen

Acetaminophen (also called paracetamol) is a nonopioid medication used in step 1 of the WHO approach to managing cancer pain. Widely available in various formulations and brands, it is a popular analgesic, formulated by itself or combined with other drugs.

With regard to cancer pain, a Cochrane systematic review in 2017 concluded that adding acetaminophen to a daily regimen of 60 mg or more of oral morphine results in no additional benefit in terms of pain relief, quality of life, or patient satisfaction or preference.¹¹ The review was based on 3 randomized, placebo-controlled trials with 122 participants, in which the daily acetaminophen dose ranged from 3,000 mg to 4,000 mg.¹²⁻¹⁴ The reviewers also noted that they could find no study that used acetaminophen alone for cancer pain.

Based on these findings, acetaminophen may not be of benefit when used in step 3 of the WHO analgesic ladder.

■ WHAT ARE SOME OF THE NEW OPIOID MEDICATIONS FOR CANCER PAIN?

Tapentadol, a mu agonist and norepinephrine reuptake inhibitor

Tapentadol has a unique synergistic mechanism of action, functioning as both a weak mu-opioid agonist and a norepinephrine reuptake inhibitor, making it the first in a new drug class.¹⁵⁻¹⁷ While tapentadol has 50 times less affinity for the mu-opioid receptor and relatively moderate norepinephrine reuptake inhibitor activity, the synergy of these mechanisms generates a degree of potency comparable to that of morphine.¹⁷

Adjuvants are drugs that are primarily indicated for conditions other than pain but possess analgesic properties

This unique mechanism results in potential benefits. The drug causes fewer adverse effects than other opioids, especially gastrointestinal problems such as nausea, vomiting, and constipation. The time to development of tolerance is longer than with morphine, and the likelihood of abuse may be lower.^{15,16} Tapentadol can also be helpful in treating neuropathic pain, with a similar mechanism as tricyclic antidepressants and serotonin-norepinephrine reuptake inhibitors.

Tapentadol is available in both immediate- and extended-release forms. There is currently no generic version available in the United States, and the drug may be prohibitively expensive or require prior insurance authorization.

Oxymorphone, a semisynthetic mu agonist

Oxymorphone is a semisynthetic mu-opioid agonist that is about twice as strong as oxycodone and 3 times as strong as oral morphine in relieving pain.¹⁸ It has been shown to be clinically comparable to oxycodone, and it caused less respiratory depression in 1 study.¹⁸ It is available in both immediate- and extended-release formulations.

The drug is predominantly metabolized in the liver, and, therefore, its use is relatively contraindicated in patients who have moderate to severe liver failure.¹⁵ Its elimination in renal failure is prolonged; hence, a longer dosing interval is recommended.

Oxymorphone has been shown to be effective and well tolerated for managing cancer pain,^{19,20} and can be considered for patients for whom other strong opioids such as morphine, oxycodone, and fentanyl have failed or who could not tolerate these drugs. Of note, oxymorphone, either in immediate- or extended-release form, generally costs more in the United States than morphine or oxycodone.

New fentanyl formulations

While intravenous and transdermal fentanyl preparations are used fairly often, a number of newer formulations are available. Transmucosal fentanyl products have been available in the form of buccal tablets, films, and intranasal sprays for a number of years, but are restricted in their use to opioid-tolerant patients (ie, those taking daily doses of at least 60 mg oral morphine or its equivalent for at least 1 week),²¹ and are relatively expensive, limiting their use.

The advantages of these forms of fentanyl are rapid onset (within 10–15 minutes) and short duration of action, making them particularly beneficial in treating episodes of unpredictable breakthrough pain.^{21,22} Available dosages, however, do not correspond with those of other opioids, and even doses of different fentanyl formulations given by the same route are not equivalent. Each preparation must be started at the lowest available dose and titrated up to effect when starting or changing formulations.

■ WHAT IS THE ROLE OF RADIATION THERAPY IN MANAGING CANCER PAIN?

Radiation therapy, or radiotherapy, has various roles in treating cancer; it is given with intent to cure the disease, arrest tumor growth, or control symptoms. As a nonpharmacologic analgesic, it is effective and time-efficient.²³ In particular, it should be strongly considered for patients suffering from painful bone metastases.

Radiation therapy generally is of 2 types, external beam and stereotactic. External beam radiation therapy, the conventional type, uses a fixed source of radiation directed toward cancerous tissue in the body. Stereotactic therapy, on the other hand, uses a moving source that targets the tumor from different angles, thereby limiting damage to nearby normal tissue. This type is typically selected for small or medium-sized tumors.

In either type, treatment can be delivered in single or multiple doses or fractions. A single fraction has been shown to be as efficacious as multiple fractions for alleviating pain from bone metastases.²⁴ Of note, more patients who undergo single-fraction therapy subsequently need repeat radiation therapy to the same site compared with those who receive multiple fractions up front.²⁵ Single-fraction therapy has the advantage of being cost-effective and convenient, especially for patients with limited life expectancy.

Of note, a transient “pain flare” can occur with radiotherapy. In a study of patients who underwent single- or multiple-fraction radiation therapy for symptomatic bone metastases, the overall incidence of pain flare within 10 days of completion was 40%.²⁶ The corticosteroid dexamethasone, given immediately

Lack of evidence, access issues, and side effects preclude the use of cannabinoids for cancer pain at this time

TABLE 1

Interventional procedures for cancer pain management

Type of intervention or procedure	Primary tumor or metastatic site indications
Nerve blocks	
Peripheral nerves	
Paravertebral	Chest-wall pain after mastectomy
Interscalene	Upper-extremity pain after surgical repair of pathologic fractures and neuropathy from brachial plexopathy
Plexus nerves	
Celiac	Right-upper-quadrant and epigastric pain from pancreaticobiliary malignancies
Superior hypogastric	Pelvic pain from gynecologic and urologic malignancies
Ganglion impar	Perineal and rectal pain from anorectal and vulvar malignancies
Implantable catheters and neuromodulation	
Intraspinal drug delivery	Visceral pain from abdominal malignancies, neuropathic pain for lower extremities, and intractable back pain from metastases
Spinal cord stimulation	
Dorsal root ganglion stimulation	
Vertebral augmentation	
Vertebroplasty	Back pain from spine metastases and vertebral fractures
Kyphoplasty	
Ablation procedures	
Radiofrequency ablation	Pain from metastatic bone and soft-tissues sites
Cryoablation	
Microwave ablation	
Magnetic resonance imaging-guided focused-ultrasound surgery	
Transarterial embolization	Pain from hypervascular bone metastases

In survivors, opioids need to be used carefully, with the eventual goal of weaning

before single-fraction therapy and daily for 4 days after, has proven to mitigate pain flares.²⁷

■ WHAT INTERVENTIONAL PROCEDURES ARE AVAILABLE FOR CANCER PAIN?

Some patients with cancer experience refractory pain, defined as failure of conventional oral pharmacologic agents and tumor-directed radiation therapy to control pain or such treatment causing intolerable side effects. In this situation, interventional treatments should be considered (Table 1). However, evidence of efficacy is lacking. Most data on outcomes are based on case reports and case series, given challenges in

methodology such as accrual of adequate sample sizes for test populations and control groups.²⁸

Nerve blocks

Cancer pain can affect nearly any anatomic site and may need local control using nerve or neurolytic blocks, which can be achieved by chemicals (phenol or ethanol), radiofrequency (thermal) ablation, or surgery. Nerve blocks can be performed in a peripheral nerve, plexus nerve, or central neuraxial site. In theory, any peripheral nerve can be blocked, but technical difficulties (eg, scar tissue, swelling) may preclude the procedure, and outcomes cannot

be predicted due to a dearth of evidence.²⁹ Examples of localized nerve blocks include paravertebral blocks for patients undergoing breast surgery³⁰ and interscalene blocks for surgical repair of pathologic fractures.³¹

Celiac plexus blocks are often used and are well studied in treating abdominal pain from pancreaticobiliary cancers. They have been shown to lower pain scores and decrease opioid use.^{32–35} Ultrasonography-guided endoscopic celiac plexus blocks have also been performed. Though mostly based on case reports and low-quality studies with small sample sizes, positive outcomes have been described.^{36,37}

Blocks to the superior hypogastric plexus for pelvic pain from gynecologic and urologic malignancies and to the ganglion impar (ganglion of Walther) for perineal pain secondary to anorectal tumors have been shown to resolve pain.^{38,39} Injection can be done into the intrathecal space to achieve segmental pain control without affecting motor function.⁴⁰

Implantable catheters and neuromodulation

For intractable tumor-related abdominal pain, neuropathic pain in extremities, or somatic low-back pain, another method of achieving central neuraxial analgesia is to use a percutaneous or implanted catheter to deliver opioids, local anesthetics, and adjuvant analgesics into the epidural or intrathecal space.²⁸ The dose is smaller than a systemic dose, and this route would likely benefit an individual having severe adverse effects from systemic opioid therapy.^{41,42}

A randomized controlled trial in 202 patients with advanced cancer compared medical management alone vs intrathecal delivery plus medical management. The latter was associated with lower pain scores, fewer side effects, and increased survival.^{43,44}

Neuromodulation is the delivery of electricity to peripheral nerves, spinal cord, and brain. Spinal cord stimulation is commonly used to treat neuropathic pain from failed back syndromes, ischemic limbs, and complex regional pain syndromes, even though there is a paucity of evidence.⁴⁵ It has been applied to cancer pain and shown to decrease pain scores and opioid use, based on case reports.^{46–48} Reports of dorsal root ganglion stimulation may help pain from surgery, complex regional pain syndrome

and phantom pain, and may be considered for refractory neuropathic cancer pain.⁴⁹

Vertebral augmentation

Vertebral augmentation involves injecting polymethyl methacrylate, a cement, directly into the vertebral body (vertebroplasty) or through a balloon (kyphoplasty). Patients with vertebral compression fractures from spinal metastases may benefit from either procedure.

Kyphoplasty was shown to improve pain scores, decrease opioid use, and improve quality of life compared with medical management alone in a randomized controlled trial in 134 patients with cancer.⁵⁰ Several studies showed improved pain scores and physical function after this procedure in patients with painful, cancer-related vertebral fractures.^{51–53}

Ablation procedures

Imaging-guided tumor ablation involves destruction of bone or soft tissue using radiofrequency energy, cold (cryoablation), microwave energy, or magnetic resonance imaging-guided focused ultrasound.

Radiofrequency ablation has been the most used. Patients experienced reduced pain scores and improved mood after the procedure.^{54–56} Combined radiofrequency ablation and cementoplasty, in which cement is injected into bone for stabilization, have been shown to improve outcomes, as the latter provides structural stability to bone destroyed by the ablation.^{57–59}

Patients treated with cryoablation experienced improved pain scores, decreased opioid use, and durable effects (ie, lasting 24 weeks or more).^{60–63}

A prospective 1-year study of computed tomography-guided microwave ablation of bone metastases and soft-tissue sarcomas demonstrated a success rate (defined as ≥ 80% tumor necrosis) of 80% at 1 month and 63% at 12 months.⁶⁴ Combined with cementoplasty, microwave ablation decreased pain scores and improved ambulation in a retrospective study of 35 cancer patients with high risk of fracture.⁶⁵

Magnetic resonance imaging-guided focused ultrasound provides more defined tumor margins for a more accurate target ablation.⁶⁶ Case series from both single centers and multiple centers showed improved pain scores and decreased opioid analgesic use.^{67,68}

Transarterial embolization

Often, before orthopedic surgery, an occlusive material is injected intra-arterially to prevent perioperative bleeding from potentially bloody bone metastases.⁶⁹ This practice, called transarterial embolization, has provided pain relief for metastatic bone disease in several case series.^{70–72}

■ HOW IS PAIN MANAGED IN CANCER SURVIVORS?

Over the years, effective treatments and innovations have yielded remarkably improved life expectancy and cure rates for patients with most types of cancer. Unfortunately, more than a third of survivors continue to suffer from cancer pain.¹

Chronic pain in these patients can be caused by any of the 3 primary anticancer treatment approaches—chemotherapy, radiation therapy, or surgery (Table 2).^{73,74} Many patients undergo a combination of these treatments, resulting in complex pain. Other causes of chronic pain include lymphedema, osteoporosis leading to pathologic fractures, and adjuvant drugs (eg, aromatase inhibitors, used to treat breast cancer, which cause myalgia and arthralgia).

Pain management in cancer survivors mirrors the interdisciplinary and multimodal approach for treating pain in patients undergoing active treatment. Rather than an ongoing search for a cure of the pain, preserving function and adopting coping strategies become the focus for survivors.⁷³

In managing these patients, it is crucial to thoroughly assess new or worsening pain, especially when accompanied by such symptoms as unexplained weight loss, unusual fatigue, altered bladder or bowel function, persistent cough, focal numbness or weakness, or an enlarging mass.⁷⁴ This allows prompt diagnosis of cancer recurrence or progression.

The WHO pain relief ladder remains the framework for starting analgesics, with close attention to employing adjuvant medications to control neuropathic pain. Opioids need to be used carefully, and with the eventual goal of weaning. Nonpharmacologic interventions, such as nerve blocks, may be indicated for patients with refractory surgery-related pain. Patients who acquire the tendency to cata-

TABLE 2

Causes of chronic pain associated with cancer treatment

Chemotherapy

Peripheral neuropathy (with agents such as paclitaxel, docetaxel, vincristine, cisplatin, oxaliplatin, thalidomide, and bortezomib)

Osteonecrosis secondary to concurrent steroid use

Radiation therapy

Connective-tissue fibrosis

Neural damage (such as brachial plexopathy, myelopathy)

Pain from secondary malignancies

Enteritis

Proctitis

Cystitis

Vaginal dryness or atrophy

Surgery

Mastectomy (may be due to phantom breast pain, intercostobrachial neuralgia, neuroma or nerve injury)

Amputation or phantom limb pain

Thoracotomy

Head and neck surgery (eg, neck dissection)

strophize or exaggerate their pain may benefit from psychosocial support provided by a social worker, psychologist, or spiritual counselor. Referral for physical therapy, occupational therapy, or both may be necessary to improve functional status in the face of chronic pain.

■ A COMPREHENSIVE APPROACH TO A COMPLEX PROBLEM

Managing cancer pain across its disease trajectory is complex. A comprehensive, interdisciplinary, and multimodal approach combining pharmacologic and nonpharmacologic interventions provided by various disciplines and medical specialties is vital. ■

Acknowledgments: We would like to thank Beth Faiman, PhD, MSN, for reviewing our article and sharing her valuable comments.

■ DISCLOSURES

The authors report no relevant financial relationships which, in the context of their contributions, could be perceived as a potential conflict of interest.

REFERENCES

- van den Beuken-van Everdingen MH, Hochstenbach LM, Joosten EA, Tjan-Heijnen VC, Janssen DJ. Update on prevalence of pain in patients with cancer: systematic review and meta-analysis. *J Pain Symptom Manage* 2016; 51(6):1070–1090.e9. doi:10.1016/j.jpainsymman.2015.12.340
- Induru RR, Lagman RL. Managing cancer pain: frequently asked questions. *Cleve Clin J Med* 2011; 78(7):449–464. doi:10.3949/ccjm.78a.10054
- World Health Organization. Palliative care. Cancer pain ladder for adults. Accessed February 9, 2021. <https://www.who.int/cancer/palliative/painladder/en/>
- Hossain SM, Hussain SM, Ekram AR. Duloxetine in painful diabetic neuropathy: a systematic review. *Clin J Pain* 2016; 32(11):1005–1010. doi:10.1097/AJP.0000000000000343
- Lunn MP, Hughes RA, Wiffen PJ. Duloxetine for treating painful neuropathy, chronic pain or fibromyalgia. *Cochrane Database Syst Rev* 2014; (1):CD007115. doi:10.1002/14651858.CD007115.pub3
- Wang ZY, Shi SY, Li SJ, et al. Efficacy and safety of duloxetine on osteoarthritis knee pain: a meta-analysis of randomized controlled trials. *Pain Med* 2015; 16(7):1373–1385. doi:10.1111/pme.12800
- Smith EM, Pang H, Cirrincione C, et al. Effect of duloxetine on pain, function, and quality of life among patients with chemotherapy-induced painful peripheral neuropathy: a randomized clinical trial. *JAMA* 2013; 309(13):1359–1367. doi:10.1001/jama.2013.2813
- Matsuoka H, Iwase S, Miyaji T, et al. Additive duloxetine for cancer-related neuropathic pain nonresponsive or intolerant to opioid-pregabalin therapy: a randomized controlled trial (JORTC-PAL08). *J Pain Symptom Manage* 2019; 58(4):645–653. doi:10.1016/j.jpainsymman.2019.06.020
- Steele G, Arneson T, Zylla D. A comprehensive review of cannabis in patients with cancer: availability in the USA, general efficacy, and safety. *Curr Oncol Rep* 2019; 21(1):10. doi:10.1007/s11912-019-0757-7
- Häuser W, Welsch P, Klose P, Radbruch L, Fitzcharles MA. Efficacy, tolerability and safety of cannabis-based medicines for cancer pain: a systematic review with meta-analysis of randomised controlled trials. *Schmerz* 2019; 33(5):424–436. doi:10.1007/s00482-019-0373-3
- Wiffen PJ, Derry S, Moore RA, et al. Oral paracetamol (acetaminophen) for cancer pain. *Cochrane Database Syst Rev* 2017; 7(7):CD012637. doi:10.1002/14651858.CD012637.pub2
- Axelsson B, Borup S. Is there an additive analgesic effect of paracetamol at step 3? A double-blind randomized controlled study. *Palliat Med* 2003; 17(8):724–725. doi:10.1177/02692163031700816
- Cubero DI, del Giglio A. Early switching from morphine to methadone is not improved by acetaminophen in the analgesia of oncologic patients: a prospective, randomized, double-blind, placebo-controlled study. *Support Care Cancer* 2010; 18(2):235–242. doi:10.1007/s00520-009-0649-8
- Israel FJ, Parker G, Charles M, Reymond L. Lack of benefit from paracetamol (acetaminophen) for palliative cancer patients requiring high-dose strong opioids: a randomized, double-blind, placebo-controlled, crossover trial. *J Pain Symptom Manage* 2010; 39(3):548–554. doi:10.1016/j.jpainsymman.2009.07.008
- Vadivelu N, Chang D, Helander EM, et al. Ketorolac, oxymorphone, tapentadol, and tramadol: a comprehensive review. *Anesthesiol Clin* 2017; 35(2):e1–e20. doi:10.1016/j.anclin.2017.01.001
- Kress HG, Coluzzi F. Tapentadol in the management of cancer pain: current evidence and future perspectives. *J Pain Res* 2019; 12:1553–1560. doi:10.2147/JPR.S191543
- Romualdi P, Grilli M, Canonico PL, Collino M, Dickenson AH. Pharmacological rationale for tapentadol therapy: a review of new evidence. *J Pain Res* 2019; 12:1513–1520. doi:10.2147/JPR.S191060
- Babalonis S, Lofwall MR, Nuzzo PA, Walsh SL. Pharmacodynamic effects of oral oxymorphone: abuse liability, analgesic profile and direct physiologic effects in humans. *Addict Biol* 2016; 21(1):146–158. doi:10.1111/adb.12173
- Mayyas F, Fayers P, Kaasa S, Dale O. A systematic review of oxymorphone in the management of chronic pain. *J Pain Symptom Manage* 2010; 39(2):296–308. doi:10.1016/j.jpainsymman.2009.07.010
- Slatkin NE, Rhiner MI, Gould EM, Ma T, Ahdieh H. Long-term tolerability and effectiveness of oxymorphone extended release in patients with cancer. *J Opioid Manag* 2010; 6(3):181–191. doi:10.5055/jom.2010.0016
- Brząkała J, Leppert W. The role of rapid onset fentanyl products in the management of breakthrough pain in cancer patients. *Pharmacol Rep* 2019; 71(3):438–442. doi:10.1016/j.pharep.2019.01.010
- Fallon M, Giusti R, Aielli F, et al. Management of cancer pain in adult patients: ESMO Clinical Practice Guidelines. *Ann Oncol* 2018; 29(suppl 4): iv166–iv191. doi:10.1093/annonc/mdy152
- Hartsell WF, Scott CB, Bruner DW, et al. Randomized trial of short-versus long-course radiotherapy for palliation of painful bone metastases. *J Natl Cancer Inst* 2005; 97(11):798–804. doi:10.1093/jnci/dji139
- Chow R, Hoskin P, Schild SE, et al. Corrigendum to “Single vs multiple fraction palliative radiation therapy for bone metastases: cumulative meta-analysis.” *Radiother Oncol* 2020; 148:115. doi:10.1016/j.radonc.2020.01.031
- Howell DD, James JL, Hartsell WF, et al. Single-fraction radiotherapy versus multifraction radiotherapy for palliation of painful vertebral bone metastases-equivalent efficacy, less toxicity, more convenient: a subset analysis of Radiation Therapy Oncology Group trial 97-14. *Cancer* 2013; 119(4):888–896. doi:10.1002/cncr.27616
- Hird A, Chow E, Zhang L, et al. Determining the incidence of pain flare following palliative radiotherapy for symptomatic bone metastases: results from three Canadian cancer centers. *Int J Radiat Oncol Biol Phys* 2009; 75(1):193–197. doi:10.1016/j.ijrobp.2008.10.044
- Chow E, Meyer RM, Ding K, et al. Dexamethasone in the prophylaxis of radiation-induced pain flare after palliative radiotherapy for bone metastases: a double-blind, randomised placebo-controlled, phase 3 trial. *Lancet Oncol* 2015; 16(15):1463–1472. doi:10.1016/S1470-2045(15)00199-0
- Vayne-Bossert P, Afsharimani B, Good P, Gray P, Hardy J. Interventional options for the management of refractory cancer pain—what is the evidence?. *Support Care Cancer* 2016; 24(3):1429–1438. doi:10.1007/s00520-015-3047-4
- Chambers WA. Nerve blocks in palliative care. *Br J Anaesth* 2008; 101(1):95–100. doi:10.1093/bja/aen105
- Andreae MH, Andreae DA. Local anaesthetics and regional anaesthesia for preventing chronic pain after surgery. *Cochrane Database Syst Rev* 2012; 10:CD007105. doi:10.1002/14651858.CD007105.pub2
- Falyar CR, Grossman EC. Ultrasound-guided interscalene-supraclavicular block for an intramedullary nailing of a pathologic humeral fracture: practical application of ultrasound-guided regional anesthesia. *AANA J* 2014; 82(3):219–222. pmid:25109160
- Zhong W, Yu Z, Zeng JX, et al. Celiac plexus block for treatment of pain associated with pancreatic cancer: a meta-analysis. *Pain Pract* 2014; 14(1):43–51. doi:10.1111/papr.12083
- Wong GY, Schroeder DR, Carns PE, et al. Effect of neurolytic celiac plexus block on pain relief, quality of life, and survival in patients with unresectable pancreatic cancer: a randomized controlled trial. *JAMA* 2004; 291(9):1092–1099. doi:10.1001/jama.291.9.1092
- Staats PS, Hekmat H, Sauter P, Lillemoe K. The effects of alcohol celiac plexus block, pain, and mood on longevity in patients with unresectable pancreatic cancer: a double-blind, randomized, placebo-controlled study. *Pain Med* 2001; 2(1):28–34. doi:10.1046/j.1526-4637.2001.002001028.x
- Eisenberg E, Carr DB, Chalmers TC. Neurolytic celiac plexus block for treatment of cancer pain: a meta-analysis. *Anesth Analg* 1995; 80(2):290–295. doi:10.1097/0000539-199502000-00015
- Arcidiacono PG, Calori G, Carrara S, McNicol ED, Testoni PA. Celiac plexus block for pancreatic cancer pain in adults. *Cochrane Database Syst Rev* 2011; 2011(3):CD007519. doi:10.1002/14651858.CD007519.pub2
- Puli SR, Reddy JB, Bechtold ML, Antillon MR, Brugge WR. EUS-guided celiac plexus neurolysis for pain due to chronic pancreatitis or pancreatic cancer pain: a meta-analysis and systematic review. *Dig*

- Dis Sci 2009; 54(11):2330–2337. doi:10.1007/s10620-008-0651-x
38. Hou S, Novy D, Felice F, Koyyalagunta D. Efficacy of superior hypogastric plexus neurolysis for the treatment of cancer-related pelvic pain. *Pain Med* 2020; 21(6):1255–1262. doi:10.1093/pm/pnz151
 39. Sousa Correia J, Silva M, Castro C, Miranda L, Agrelo A. The efficacy of the ganglion impar block in perineal and pelvic cancer pain. *Support Care Cancer* 2019; 27(11):4327–4330. doi:10.1007/s00520-019-04738-9
 40. Watanabe A, Yamakage M. Intrathecal neurolytic block in a patient with refractory cancer pain. *J Anesth* 2011; 25(4):603–605. doi:10.1007/s00540-011-1141-4
 41. Sindt JE, Brogan SE. Interventional treatments of cancer pain. *Anesthesiol Clin* 2016; 34(2):317–339. doi:10.1016/j.anclin.2016.01.004
 42. Smith TJ, Swainey C, Coyne PJ. Pain management, including intrathecal pumps. *Curr Pain Headache Rep* 2005; 9(4):243–248. doi:10.1007/s11916-005-0031-6
 43. Smith TJ, Staats PS, Deer T, et al. Randomized clinical trial of an implantable drug delivery system compared with comprehensive medical management for refractory cancer pain: impact on pain, drug-related toxicity, and survival. *J Clin Oncol* 2002; 20(19):4040–4049. doi:10.1200/JCO.2002.02.118
 44. Smith TJ, Coyne PJ. Implantable drug delivery systems (IDDS) after failure of comprehensive medical management (CMM) can palliate symptoms in the most refractory cancer pain patients. *J Palliat Med* 2005; 8(4):736–742. doi:10.1089/jpm.2005.8.736
 45. Kunnumpurath S, Srinivasagopalan R, Vadivelu N. Spinal cord stimulation: principles of past, present and future practice: a review. *J Clin Monit Comput* 2009; 23(5):333–339. doi:10.1007/s10877-009-9201-0
 46. Lihua P, Su M, Zejun Z, Ke W, Bennett MI. Spinal cord stimulation for cancer-related pain in adults. *Cochrane Database Syst Rev* 2013; (2):CD009389. doi:10.1002/14651858.CD009389.pub2
 47. Yakovlev AE, Resch BE. Spinal cord stimulation for cancer-related low back pain. *Am J Hosp Palliat Care* 2012; 29(2):93–97. doi:10.1177/1049909111410414
 48. Yakovlev AE, Elias Y. Spinal cord stimulation as a treatment option for intractable neuropathic cancer pain. *Clin Med Res* 2008; 6(3–4):103–106. doi:10.3121/cmr.2008.813
 49. Harrison C, Epton S, Bojanic S, Green AL, FitzGerald JJ. The efficacy and safety of dorsal root ganglion stimulation as a treatment for neuropathic pain: a literature review. *Neuromodulation* 2018; 21(3):225–233. doi:10.1111/ner.12685
 50. Berenson J, Pflugmacher R, Jarzem P, et al. Balloon kyphoplasty versus non-surgical fracture management for treatment of painful vertebral body compression fractures in patients with cancer: a multicentre, randomised controlled trial. *Lancet Oncol* 2011; 12(3):225–235. doi:10.1016/S1470-2045(11)70008-0
 51. Burton AW, Mendoza T, Gebhardt R, et al. Vertebral compression fracture treatment with vertebroplasty and kyphoplasty: experience in 407 patients with 1,156 fractures in a tertiary cancer center. *Pain Med* 2011; 12(12):1750–1757. doi:10.1111/j.1526-4637.2011.01278.x
 52. Chew C, Craig L, Edwards R, Moss J, O'Dwyer PJ. Safety and efficacy of percutaneous vertebroplasty in malignancy: a systematic review. *Clin Radiol* 2011; 66(1):63–72. doi:10.1016/j.crad.2010.09.011
 53. Schroeder JE, Ecker E, Skelly AC, Kaplan L. Cement augmentation in spinal tumors: a systematic review comparing vertebroplasty and kyphoplasty. *Ever Based Spine Care J* 2011; 2(4):35–43. doi:10.1055/s-0031-1274755
 54. Dupuy DE, Liu D, Hartfeil D, et al. Percutaneous radiofrequency ablation of painful osseous metastases: a multicenter American College of Radiology Imaging Network trial. *Cancer* 2010; 116(4):989–997. doi:10.1002/cncr.24837
 55. Callstrom MR, Charboneau JW, Goetz MP, et al. Image-guided ablation of painful metastatic bone tumors: a new and effective approach to a difficult problem. *Skeletal Radiol* 2006; 35(1):1–15. doi:10.1007/s00256-005-0003-2
 56. Goetz MP, Callstrom MR, Charboneau JW, et al. Percutaneous image-guided radiofrequency ablation of painful metastases involving bone: a multicenter study. *J Clin Oncol* 2004; 22(2):300–306. doi:10.1200/JCO.2004.03.097
 57. Hoffmann RT, Jakobs TF, Trumm C, Weber C, Helmberger TK, Reiser MF. Radiofrequency ablation in combination with osteoplasty in the treatment of painful metastatic bone disease. *J Vasc Interv Radiol* 2008; 19(3):419–425. doi:10.1016/j.jvir.2007.09.016
 58. Munk PL, Rashid F, Heran MK, et al. Combined cementoplasty and radiofrequency ablation in the treatment of painful neoplastic lesions of bone. *J Vasc Interv Radiol* 2009; 20(7):903–911. doi:10.1016/j.jvir.2009.03.035
 59. Clarençon F, Jean B, Pham HP, et al. Value of percutaneous radiofrequency ablation with or without percutaneous vertebroplasty for pain relief and functional recovery in painful bone metastases. *Skeletal Radiol* 2013; 42(1):25–36. doi:10.1007/s00256-011-1294-0
 60. Callstrom MR, Atwell TD, Charboneau JW, et al. Painful metastases involving bone: percutaneous image-guided cryoablation—prospective trial interim analysis. *Radiology* 2006; 241(2):572–580. doi:10.1148/radiol.2412051247
 61. Callstrom MR, Dupuy DE, Solomon SB, et al. Percutaneous image-guided cryoablation of painful metastases involving bone: multicenter trial. *Cancer* 2013; 119(5):1033–1041. doi:10.1002/cncr.27793
 62. Prologo JD, Passalacqua M, Patel I, Bohnert N, Corn DJ. Image-guided cryoablation for the treatment of painful musculoskeletal metastatic disease: a single-center experience. *Skeletal Radiol* 2014; 43(11):1551–1559. doi:10.1007/s00256-014-1939-x
 63. Tomasian A, Wallace A, Northrup B, Hillen TJ, Jennings JW. Spine cryoablation: pain palliation and local tumor control for vertebral metastases. *AJNR Am J Neuroradiol* 2016; 37(1):189–195. doi:10.3174/ajnr.A4521
 64. Aubry S, Dubut J, Nueffer JP, Chaigneau L, Vidal C, Kastler B. Prospective 1-year follow-up pilot study of CT-guided microwave ablation in the treatment of bone and soft-tissue malignant tumours. *Eur Radiol* 2017; 27(4):1477–1485. doi:10.1007/s00330-016-4528-7
 65. Pusceddu C, Sotgia B, Fele RM, Ballicu N, Melis L. Combined microwave ablation and cementoplasty in patients with painful bone metastases at high risk of fracture. *Cardiovasc Intervent Radiol* 2016; 39(1):74–80. doi:10.1007/s00270-015-1151-y
 66. Tempary CM, McDannold NJ, Hynynen K, Jolesz FA. Focused ultrasound surgery in oncology: overview and principles. *Radiology* 2011; 259(1):39–56. doi:10.1148/radiol.11100155
 67. Liberman B, Gianfelice D, Inbar Y, et al. Pain palliation in patients with bone metastases using MR-guided focused ultrasound surgery: a multicenter study. *Ann Surg Oncol* 2009; 16(1):140–146. doi:10.1245/s10434-008-0011-2
 68. Catane R, Beck A, Inbar Y, et al. MR-guided focused ultrasound surgery (MRgFUS) for the palliation of pain in patients with bone metastases—preliminary clinical experience. *Ann Oncol* 2007; 18(1):163–167. doi:10.1093/annonc/mdl335
 69. Gupta P, Gamanagatti S. Preoperative transarterial embolisation in bone tumors. *World J Radiol* 2012; 4(5):186–192. doi:10.4329/wjr.v4.i5.186
 70. Eustatia-Rutten CF, Romijn JA, Guijt MJ, et al. Outcome of palliative embolization of bone metastases in differentiated thyroid carcinoma. *J Clin Endocrinol Metab* 2003; 88(7):3184–3189. doi:10.1210/jc.2003-030231
 71. Barton PP, Waneck RE, Karnel FJ, Ritschl P, Kramer J, Lechner GL. Embolization of bone metastases. *J Vasc Interv Radiol* 1996; 7(1):81–88. doi:10.1016/s1051-0443(96)70738-8
 72. Chiras J, Adem C, Vallée JN, Spelle L, Cormier E, Rose M. Selective intra-arterial chemoembolization of pelvic and spine bone metastases. *Eur Radiol* 2004; 14(10):1774–1780. doi:10.1007/s00330-004-2240-5
 73. Burton AW, Fanciullo GJ, Beasley RD, Fisch MJ. Chronic pain in the cancer survivor: a new frontier. *Pain Med* 2007; 8(2):189–198. doi:10.1111/j.1526-4637.2006.00220.x
 74. Davies PS. Chronic pain management in the cancer survivor: tips for primary care providers. *Nurse Pract* 2013; 38(6):28–39. doi:10.1097/01.NPR.0000429893.95631.63

Address: Renato V. Samala, MD, MHPE, FACP, FAAHPM, Department of Palliative and Supportive Care, Taussig Cancer Institute, CA-53, Cleveland Clinic, 9500 Euclid Avenue, Cleveland, OH 44195; samalar@ccf.org