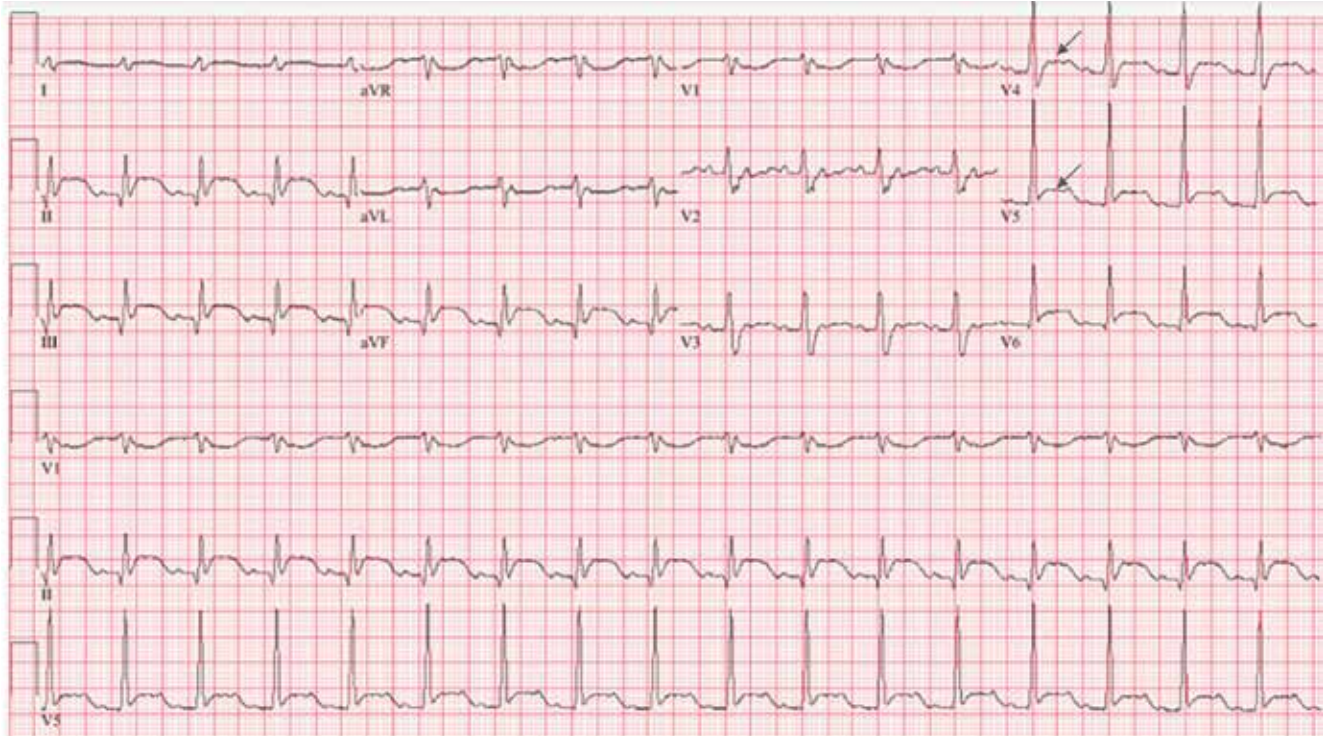


# An unexpected turn

In the July 2022 issue, an error appeared in Ganeshan S, Kelemen B, Dhaliwal G, Zier L. *An unexpected turn: A 71-year-old man with myocardial infarction*. *Cleve Clin J Med* 2022;89(7):401–407. doi:10.3949/ccjm.89a.21030. The arrows in **Figure 3** were incorrectly placed. The correct figure appears below:



**Figure 3.** On repeat electrocardiography 48 hours after presentation, the ST-segment elevations in leads II, III, and aVF were still present. The ST-segment depressions in aVL and V<sub>1</sub>–V<sub>3</sub> had resolved, and new ST-segment elevations were present in V<sub>4</sub> and V<sub>5</sub> (arrows).

This is now correct on ccjm.org.