Tatsuya Shindo, MD
Department of Family Medicine, Kameda Family Clinic Tateyama, Tateyama, Japan; Department of General Internal Medicine, Hyogo Prefectural Harima-Himeji General Medical Center, Himeji, Japan

Median rhomboid glossitis caused by tongue-brushing

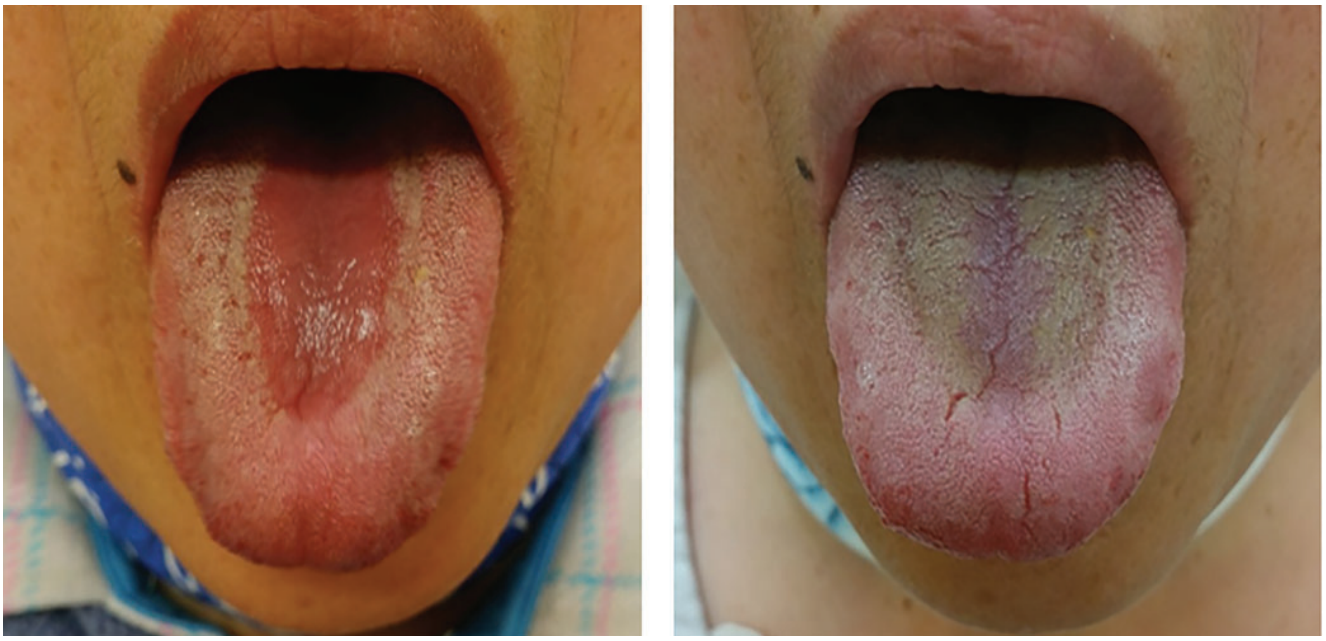

Figure 1. (A) The patient's tongue on presentation at the hospital, and (B) 1 month after discontinuing tongue-brushing.

A previously healthy 57-year-old woman presented to the hospital with a month-long history of painful sensations in the tongue. She was not a smoker. She did not use any prosthesis contacting the palate and was not in the habit of holding any food or material on the tongue. She had started vigorous brushing of the tongue 1 month earlier because her child had told her that she had halitosis. She had not received any treatment before she came to the hospital.

Physical examination revealed a plaque of smooth, erythematous, and well-circumscribed papillary atrophy on the dorsal midline of the tongue (**Figure 1A**). There were no lesions or inflammation on the hard palate. Laboratory tests were normal and testing for candidal infection was negative for yeast-like fungi. A clinical diagnosis of median rhomboid glossitis was made. The patient was advised to stop brushing her tongue, and at a follow-up visit 1 month later, her symptoms and the lesion had improved (**Figure 1B**), and no further evaluation was warranted.

doi:10.3949/ccjm.90a.21111

KEY FEATURES

Median rhomboid glossitis is present in up to 1% of the population[1] and is more prevalent in men,

Downloaded from www.ccjm.org on April 20, 2024. For personal use only. All other uses require permission.

immunosuppressed patients, patients with diabetes, and patients taking broad-spectrum antibiotics.[1,2] It is characterized by a papillary atrophy of the dorsum of the tongue, typically anterior to the circumvallate papillae. It occurs as a well-demarcated area of depapillation, elliptical or rhomboid in shape, on the midline of the tongue.[1] The condition is usually asymptomatic and is often first noticed by a dentist during routine examination. However, some patients may present to the physician's office with persistent pain, irritation, or pruritus.[2]

In patients with median rhomboid glossitis due to chronic candidal infection, prolonged contact of the tongue lesion with the hard palate can result in a lesion on the hard palate, referred to as a "kissing lesion." This is considered a marker of immunosuppression, and human immunodeficiency virus infection should be suspected.[1] However, the cause of median rhomboid glossitis is not limited to candidal infection, and idiopathic cases have also been reported.[3] It may also be caused by minor trauma.[4] Vigorous tongue-brushing may result in loss of filiform papillae and so should be discouraged.

The differential diagnosis includes erythroplakia, geographic tongue, and granular cell tumor, but these conditions can be differentiated by their appearance and clinical course, and unnecessary evaluation and referral can be avoided if the clinician is aware of median rhomboid glossitis.

Median rhomboid glossitis may improve spontaneously, as in this patient. If initial testing is negative for candidal infection, patient follow-up may be useful, but empiric antifungal treatment should be avoided as it contributes to resistance.[3]

DISCLOSURES

The author reports no relevant financial relationships which, in the context of their contributions, could be perceived as a potential conflict of interest.

REFERENCES

1. **Rogers RS 3rd, Bruce AJ.** The tongue in clinical diagnosis. J Eur Acad Dermatol Venereol 2004; 18(3):254–259. doi:10.1111/j.1468-3083.2004.00769.x
2. **Goregen M, Miloglu O, Buyukkurt MC, Caglayan F, Aktas AE.** Median rhomboid glossitis: a clinical and microbiological study. Eur J Dent 2011; 5(4):367–372. pmid:21912494
3. **Pili FMG, Erriu M, Piras A, Garau V.** Application of the novel method in the diagnosis and treatment of median rhomboid glossitis Candida-associated. Eur J Dent 2014; 8(1):129–131. doi:10.4103/1305-7456.126268
4. **Lago-Méndez L, Blanco-Carrión A, Diniz-Freitas M, Gándara-Vila P, García-García A, Gándara-Rey JM.** Rhomboid glossitis in atypical location: case report and differential diagnosis. Med Oral Patol Oral Cir Bucal 2005; 10(2):123–127. pmid:15735544

Address: *Tatsuya Shindo, MD, Department of Family Medicine, Kameda Family Clinic Tateyama, 4304-9 Masaki, Tateyama-shi, Chiba-ken 294-0051, Japan; shindo.tatsuya@kameda.jp*

Downloaded from www.ccjm.org on April 20, 2024. For personal use only. All other uses require permission.