

THE CLINICAL PICTURE

Takeshi Onda, DDS, PhD

Department of Oral and Maxillofacial Surgery,
Tokyo Dental College, Tokyo, Japan

Kamichika Hayashi, DDS, PhD

Department of Oral and Maxillofacial Surgery,
Tokyo Dental College, Tokyo, Japan

Akira Katakura, DDS, PhD

Department of Oral Pathological Science and
Surgery, Tokyo Dental College, Tokyo, Japan

Masayuki Takano, DDS, PhD

Department of Oral and Maxillofacial
Surgery, Tokyo Dental College, Tokyo, Japan

Oral leukoplakia and oral cancer

A 56-YEAR-OLD MALE was referred by his dentist with noticeable worsening of vitiligo of the tongue, which had been diagnosed as oral leukoplakia 3 years earlier and had been monitored at the dental clinic.

The patient had no significant medical history. He had a continuous smoking habit of more than 36 years but did not consume alcohol. Examination confirmed oral leukoplakia, with an uneven and rough surface, and a white papillary mass was noted within the area of leukoplakia on the right edge of the tongue (**Figure 1**). No lymph node swelling in the neck was noted. Biopsy of the lesion confirmed it to be squamous cell carcinoma. Computed tomography, magnetic resonance imaging, and ultrasonography showed that the mass was confined to the surface of the tongue.

■ TREATMENT AND FOLLOW-UP

Resection of the mass with at least 10 mm of surrounding tissue was performed under general anesthesia. During surgery, rapid pathological diagnosis was performed to confirm that no tumor cells remained, and the wound was subsequently sutured. Postoperatively, a slight deformation of the tongue and scarring were noted, affecting the patient's eating, swallowing, and pronunciation, but these functions gradually improved. At 5 years postoperatively, the patient's clinical course was favorable, without recurrence.

■ PREMALIGNANT ORAL LESIONS

Tongue cancer accounts for 60% of all oral cancers, and usually originates from the tongue border.¹ Nearly 90% of all oral cancers are squamous cell carcinoma, and major risk factors are chronic irritation, smoking, and alcohol consumption.²

Most oral cancers have a premalignant lesion stage.³ Regular monitoring for progression of premalignant lesions is critical for the early detection and treatment of oral cancer. Oral leukoplakia, the most

doi:10.3949/ccjm.90a.22044

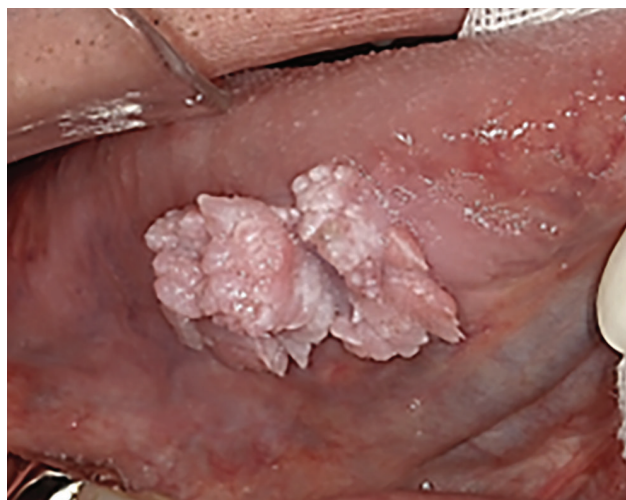


Figure 1. White lesions were observed on the right tongue edge. Papillary cell proliferation was noted in the same area.

common potentially cancerous oral lesion, progresses to squamous cell carcinoma at a rate ranging from 0.1% to 36.4%.⁴ This transformation depends on factors such as sex, age, clinical type, locus, onset mode, and the presence or absence of epithelial atypia,⁵ although the mechanism remains unclear to date.

Currently, no clear guidelines exist as to whether aggressive resection or progression monitoring produces better outcomes. Consequently, there is an urgent and unmet need for molecular biological investigation of leukoplakia.

■ IMPORTANCE OF REGULAR FOLLOW-UP

Our report illustrates the importance of regular follow-up of leukoplakia. Before our patient presented, he had been followed regularly by his dentist, and this led to earlier recognition of possible malignant transformation, resulting in earlier resection of the cancer and better prognosis. ■

■ DISCLOSURES

The authors report no relevant financial relationships which, in the context of their contributions, could be perceived as a potential conflict of interest.

■ REFERENCES

1. Omura K. Current status of oral cancer treatment strategies: surgical treatments for oral squamous cell carcinoma. *Int J Clin Oncol* 2014; 19(3):423–430. doi:10.1007/s10147-014-0689-z
2. Abati S, Bramati C, Bondi S, Lissoni A, Trimarchi M. Oral cancer and precancer: a narrative review on the relevance of early diagnosis. *Int J Environ Res Public Health* 2020; 17(24):9160. doi:10.3390/ijerph17249160
3. Yang SW, Lee YS, Chang LC, Yang CH, Luo CM, Wu PW. Oral tongue leukoplakia: analysis of clinicopathological characteristics, treatment outcomes, and factors related to recurrence and malignant transformation. *Clin Oral Investig* 2021; 25(6):4045–4058. doi:10.1007/s00784-020-03735-1
4. Evren I, Brouns ER, Poell JB, et al. Associations between clinical and histopathological characteristics in oral leukoplakia. *Oral Dis* 2021; 10.1111/odi.14038. doi:10.1111/odi.14038
5. Speight PM, Khurram SA, Kujan O. Oral potentially malignant disorders: risk of progression to malignancy. *Oral Surg Oral Med Oral Pathol Oral Radiol* 2018; 125(6):612–627. doi:10.1016/j.oooo.2017.12.011

.....
Address: Takeshi Onda, DDS, PhD, Department of Oral and Maxillofacial Surgery, Tokyo Dental College, 2-9-18, Kanda-Misakicho, Chiyoda-ku, Tokyo 101-0061, Japan; ondatake@tdc.ac.jp