

RÖNTGENOGRAPHIC INTERPRETATION OF DUODENAL DEFORMITIES*

C. C. McCLURE, M.D.

Cases presenting obscure abdominal conditions, with vague and indefinite symptoms, are frequently encountered in medical practice. Most physicians have experienced the humiliation resulting from inability to diagnose correctly and treat satisfactorily cases of "biliousness," "indigestion," "gas on the stomach," "heavy feeling after eating," and various combinations of such complaints. Frequently, of course, constipation is at the root of the patient's difficulty, and there is also a very close relationship between gastrointestinal symptoms and the condition commonly diagnosed as "neurasthenia." This is a dangerous diagnosis to make, however, unless a careful and exhaustive search has failed to reveal the presence of organic disease. Yet differentiation is essential, for it must be remembered that in cases in which the symptoms are due to so-called neurasthenia the patient can not often be relieved by operative intervention, while nothing but surgery will avail in such conditions as cholelithiasis, duodenal ulcer with pyloric obstruction, appendicitis, and so forth.

If gastrointestinal disorders always presented definite signs and symptoms, a diagnosis could be made early, and proper treatment could be instituted promptly; but many times the symptoms are so vague that the most experienced observers are unable to formulate a correct diagnosis. One reason for this is the close anatomical association of the abdominal viscera, which permits one organ to be affected by a pathological condition in another nearby, as in cases of adhesions to a diseased appendix or gallbladder. Another reason is the functional interdependence of the viscera, so that a derangement in one organ may disturb the function of another, while the closely related innervation is responsible for the development of reflexes which may be mistaken for primary disease.

In these undefined cases, if it is impossible to formulate a diagnosis after complete examination, exploratory laparotomy is justified, especially if the patient is in an alarming condition. This procedure usually is safe, but it is successful only when the surgeon is capable of interpreting the pathological conditions encountered.

Reprinted by permission of WEST VIRGINIA MEDICAL JOURNAL, 1931, Vol. 27, pages 1-8.

*Original paper.

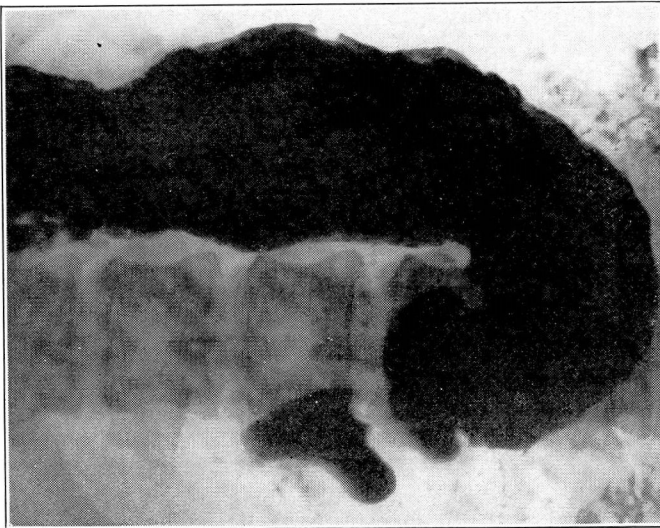
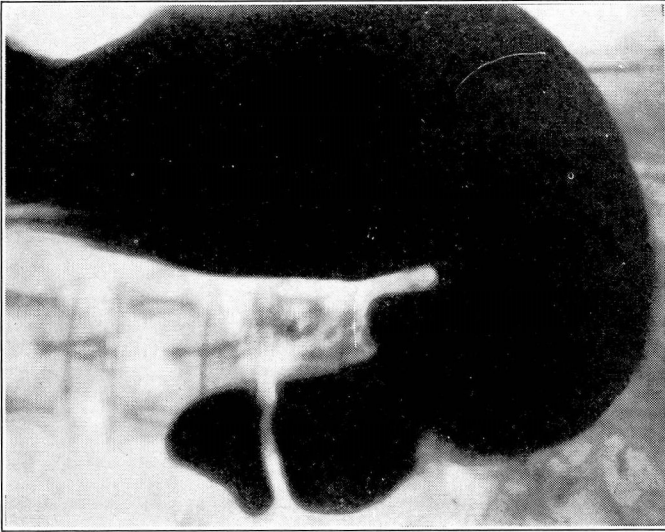


Fig. 1. Röntgenograms showing pressure deformities produced by pressure from a diseased gallbladder on the greater-curvature side of the duodenal bulb. (See also illustrations on page 80.)

Sometimes, after the removal of a diseased organ, the patient will complain of symptoms similar to those present before the operation, but perhaps less severe. These residual symptoms may be the result of the incomplete removal or repair of the closely associated pathological conditions, and they may be anticipated and prevented by proper methods.

It has taken the medical profession a long time to appreciate the necessity for complete teamwork, particularly in cases of digestive disorder. The internist must have intelligent and earnest cooperation from the pathologist and the roentgenologist in solving the preoperative diagnostic problems. He must also be familiar with the surgical possibilities and be ready to exchange advice with the surgeon both before and after the operation. The surgeon, in turn, must acquaint himself with the case from all angles, so that he will be prepared adequately to explore the operative area before the incision is closed and to clear up any associated conditions which may have developed. Thus will postoperative symptoms be averted or minimized.

In the diagnosis of gastrointestinal disease the importance of the X-ray can scarcely be overestimated, but it is essential that the roentgenologist be thoroughly familiar with the evidences of disease as they appear on the film. It is to emphasize, therefore, some of these diagnostic indications as they apply to the duodenum, and the effect on it of disease of the surrounding viscera, that this short paper is presented.

THE DUODENUM AND CHOLECYSTITIS

Normally, the pressure of the gallbladder on the duodenum is less than the pressure within the duodenum, and therefore it does not produce any irregularity of this portion of the digestive tract. On the other hand, a chronically diseased gallbladder, with increased pressure, frequently manifests itself by the presence of a distinct deformity of the stomach or duodenum or both — a fact easily explained by the juxtaposition of these organs. After this condition has been present for a time, it is followed by a more serious manifestation, namely, periduodenitis. This term is used to designate the adhesions which unite the accessory bile passages to the cap and descending portions of the duodenum and which deform and constrict the duodenum in the absence of any parietal lesions such as stenosis, ulceration, or diverticula. It is probable that the persistence of periduodenitis after cholecystectomy is the usual reason for incomplete relief of symptoms. This

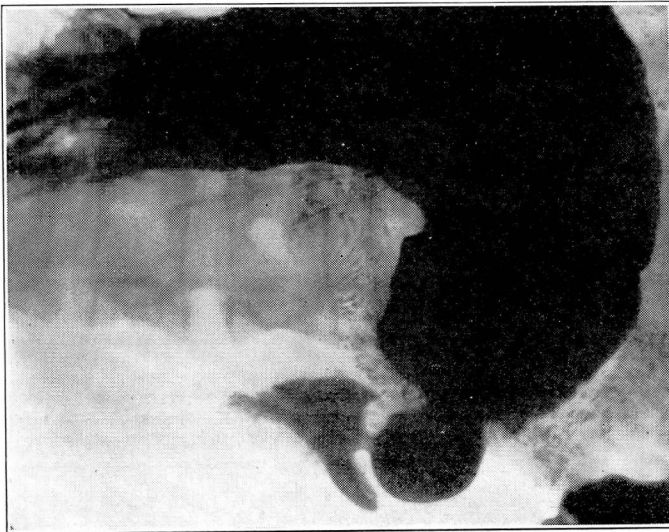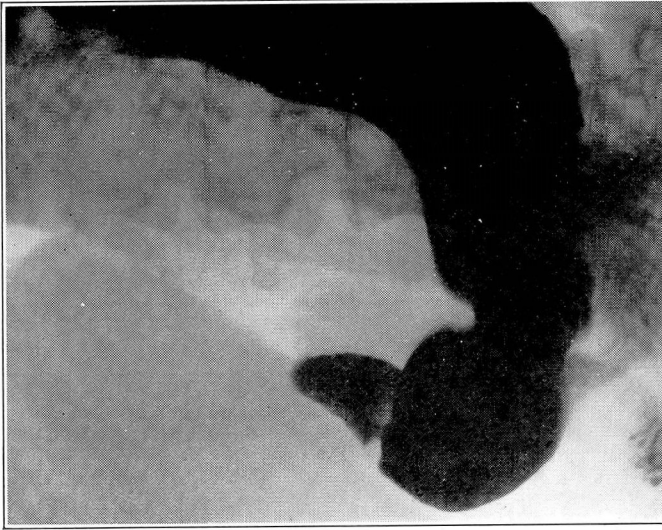


Fig. 1. (Cont.) Röntgenograms showing pressure deformities produced by pressure from a diseased gallbladder on the greater-curvature side of the duodenal bulb. (See also illustrations on page 78.)

condition doubtless has necessitated many secondary operations. Hence a careful survey should be made before the first incision is closed.

Periduodenitis has a distinctive röntgenologic syndrome, and the absence of deformity of the duodenum in the presence of cholecystitis is almost unknown. The adhesions which unite the accessory biliary tract to the duodenum present various arrangements. Some connect the cystic duct or the gall-bladder or both to the bulb and descending portion of the duodenum. If the patient is not too heavy or the abdominal wall not too thick or rigid, the presence or absence of these pericholecystic adhesions can easily be demonstrated. After they have been released at operation, the duodenum will assume its original course and contour, free from stenosis or other deformities, and the röntgenographic appearance will be normal.

When involved in pericholecystic adhesions, the duodenal bulb presents a constant deformity which varies in degree according to the amount of filling or emptying at the time the röntgenogram is made. At no time during the examination, however, will it have the clear, smooth appearance of the normal cap. Under the fluoroscope pressure exerted on the pylorus in an attempt to fill the bulb smoothly produces dilatation of the cap, but the irregularity remains even though the contour is slightly changed. Deforming pericholecystitis is always stenosing in character, although to a variable degree. The hyperperistalsis often seen in patients with disease of the gall-bladder probably is caused by duodenal stenosis.

Röntgenographic examination of the duodenum, therefore, not only reveals the presence of adhesions binding the gallbladder, but also yields information as to the extent of these adhesions. This is a most important part of the preoperative diagnosis, as it acquaints the surgeon with the difficulties likely to be encountered at operation.

The gallbladder may leave its imprint on any portion of the gastropyloric canal, depending on whether the contact is with the pyloric vestibule, the duodenal bulb, or the descending portion of the duodenum. This imprint always appears as a regular concave curve, which may be wider or narrower but never so deep as the defect seen in cases of duodenal ulcer. The depth of the curve is directly proportionate to the degree of filling of the duodenum. At times it is possible to see the shadow of the gallbladder or the outline of a stone occupying this concave pressure irregularity. One normal condition sometimes is misleading, namely, a heavily loaded

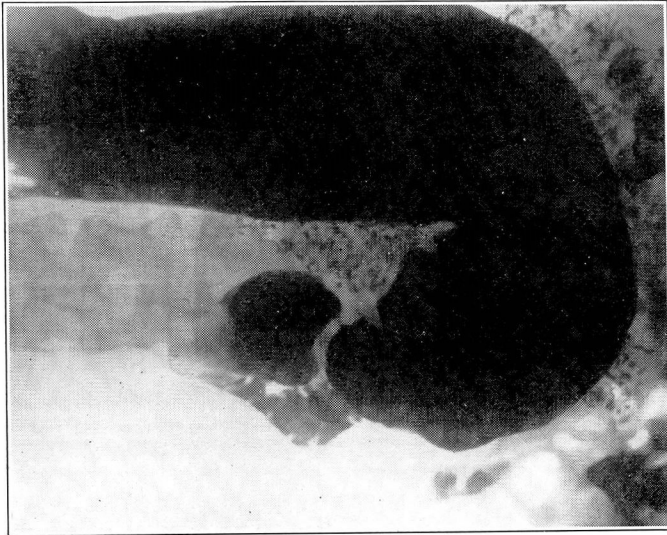


Fig. 2. Röntgenogram showing deformity of the cap and descending portion of the duodenum, caused by pressure from a diseased gallbladder.

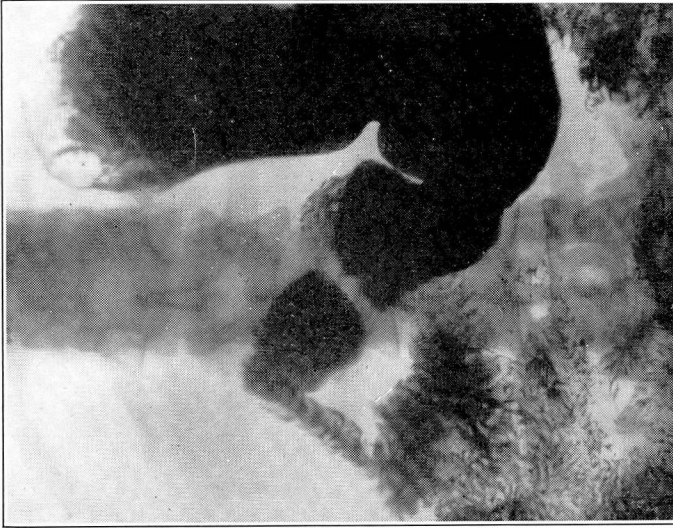


Fig. 3. Röntgenogram showing dilatation of the duodenum caused by periduodenitis, with adhesions to a diseased gallbladder.

hepatic flexure. Usually, however, this is easily ruled out by colonic examination.

DILATATION OF THE DUODENUM

The definite röntgenographic picture of a dilated duodenum (chronic duodenal ileus) frequently is seen in cases of severe chronic headache accompanied by epigastric pain, vomiting, and typical symptoms of toxemia, these symptoms varying according to the degree of obstruction. In these cases the descending, transverse, and ascending portions of the duodenum may become greatly dilated, though the cap and descending portions are commonly affected, and the opaque meal may be seen for hours in the section of the small intestine involved.

According to Higgins,¹ the four main groups of etiologic factors are: (1) congenital abnormalities, (2) factors favoring the formation of adhesions, (3) factors favoring the compression of the duodenum, and (4) factors favoring the pelvic position of the intestines. In chronic cholecystitis, the first or second portions of the duodenum, or possibly both, frequently are found to be adherent to the gall-bladder. Angulations along the course of the duodenum, resulting from adhesions, are capable of producing varying degrees of obstruction, thus causing dilatation and stasis in that portion of the small intestine proximal to the kink or angulation. Inflammatory conditions in the mesentery, infiltration by a malignant growth, or tuberculous adenitis might be factors favoring adhesions and, later, chronic duodenal ileus. Deaver states that acute angulation in the duodenojejunal angle may be a cause for the dilatation. Spinal deformities, an extremely low duodenum, a heavy mesentery, and excessive motility of the proximal colon also have been given as causes of chronic duodenal ileus.

Whether or not the etiologic factor can be diagnosed röntgenographically depends upon the presence of a characteristic deformity of the duodenum. Usually it can not be determined with any degree of certainty. Since chronic duodenal ileus is often overlooked, however, even though not uncommon, the examiner should make a very careful röntgenographic examination in all suspected cases.

Dietary, postural, and supportive treatment gives relief in some cases, depending upon the causative factor and the degree of dilatation. If marked dilatation is present, with stasis and regurgitation of the duodenal contents into the stomach, duodenojejunostomy is indicated. Gastroenterostomy does not relieve the condi-

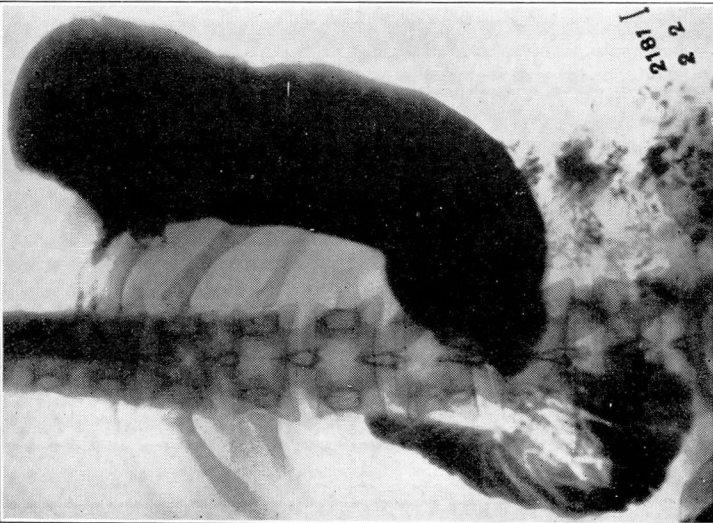


Fig. 4. Röntgenogram showing a filling defect of the fundus ventriculi on the lesser-curvature side, due to carcinoma. In this case the patient had swallowed lye in an attempt at suicide. The stomach and duodenum were rigid and the duodenum was greatly dilated.

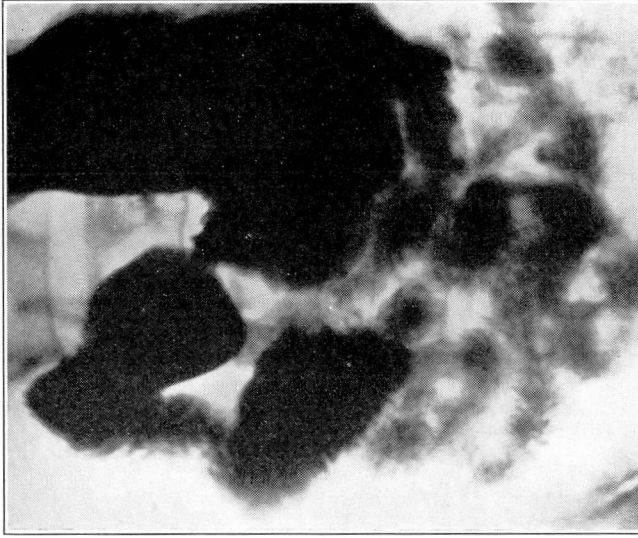


Fig. 5. Röntgenogram showing a greatly dilated duodenum. The only cause ascertained on examination was general visceroptosis. Operation has not been performed.

tion, and may even aggravate it, necessitating a second operation. The end-results after proper surgical intervention are excellent, and the operative mortality is practically nil.

GASTROPTOSIS

[The duodenum is freely movable throughout its course, except at its beginning and end. At the superior portion it is attached to the liver by the hepatoduodenal ligament, and at the duodenojejunal flexure it is suspended from the posterior body wall by the ligament of Treitz. Bearing in mind these attachments, the unfortunate neurasthenic patient with markedly visceroptotic abdomen may be assured that, while the pain and discomfort complained of have a real cause, it is not of a dangerous nature. In these cases the stomach may occupy a position with the greater curvature on a level with the symphysis. When such a stomach is filled with food, the weight stretches the suspensory ligaments just so much more, and this naturally adds to the epigastric discomfort.

Before making a diagnosis of stretching of the duodenal ligament as a cause of symptoms, of course, it is necessary to rule out all possible organic lesions which might be responsible. Retention often occurs in cases of marked visceroptosis because of the inability of the peristaltic waves to empty a stomach against the pull of gravity.

PANCREATIC TUMOR

It is unfortunate that, in its early stages, tumor of the pancreas usually can not be diagnosed röntgenographically. It is necessary for such growths to attain sufficient size to exert definite pressure on the descending or transverse portions of the duodenum or the greater curvature of the stomach at the pyloric end in order to produce a deformity that is recognizable on the film. A benign growth, as a rule, produces a sharp, clear-cut mesial border, usually displacing the descending portion of the duodenum outward. A malignant growth may be recognized by the fringed border of the displacement.

DUODENAL DIVERTICULA

As a rule, diverticula of the duodenum present themselves in the space between the pylorus and the descending and transverse portions of the duodenum. It is interesting to speculate on the origin of such diverticula, and a tenable theory is that they may be due, in some cases at least, to an old perforation which has caused a localized peritonitis that has walled itself off, but communicates with the duodenum by a fistulous tract. The röntgenographic recognition of diverticula presents little difficulty.

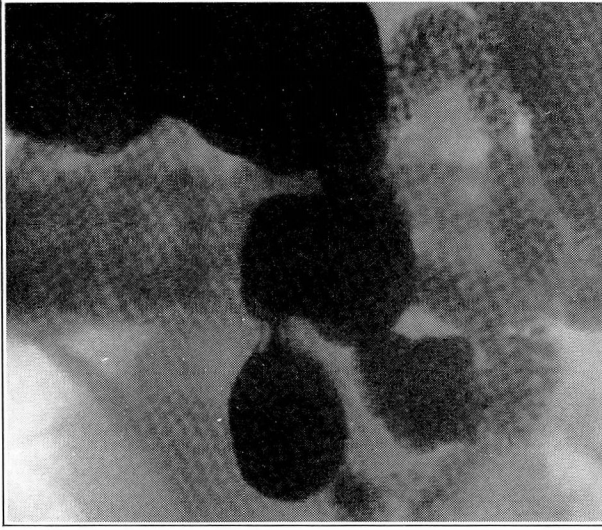


Fig. 7. Röntgenogram showing a diverticulum from the transverse portion of the duodenum.

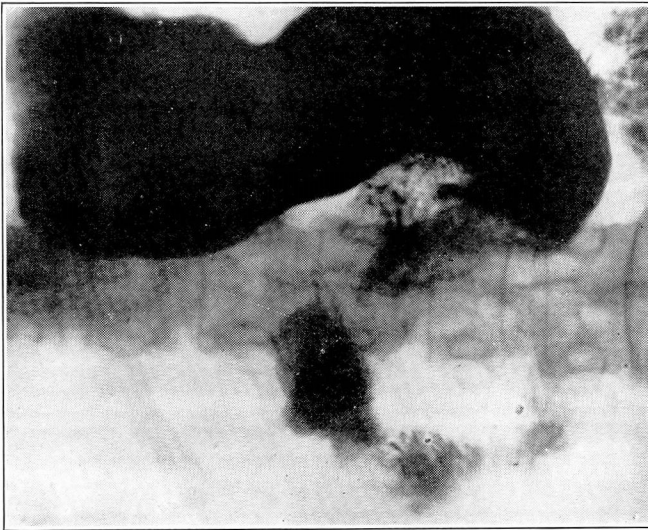


Fig. 6. Röntgenogram showing deformity of the pylorus due to carcinoma of the head of the pancreas. This diagnosis was confirmed at operation.

DUODENAL ULCER

The deformity caused by ulcer of the duodenum usually is marked enough to be readily recognized. As in cases of pulmonary tuberculosis, however, a sufficient pathological change must take place for a diagnostic shadow to be cast on the film. In some cases of ulcer, even in the presence of extensive hemorrhage, the crater is not deep enough to throw a shadow and the spasticity of the surrounding duodenal bulb is insufficient to produce the characteristic stellate cap. In such cases, a diagnosis of duodenal ulcer is not justified by the roentgenographic evidence, for bulbar deformity is the cardinal sign on which to predicate a correct hypothesis.

Usually, the deformity found at operation is smaller than that indicated by the film. The factor responsible for this effect is the spastic condition of the musculature surrounding the region of the ulcer. When this element is absent and the bulb is smooth and well rounded, the presence of a duodenal ulcer can not be demonstrated before operation. When the spasticity is present, however, the deformity, viewed röntgenographically, is unvarying, and should not be mistaken.

Any angle of the duodenal bulb may be involved, and small ulcers on the base of the bulb should not be overlooked. Ulcers located distal to the bulb are particularly difficult to diagnose because of the normal irregularity of the outline in this portion of the duodenum. The diagnosis of such ulcers can be made only by the aid of indirect signs, such as enlargement of the stomach with retention, hyperperistalsis, or the retention of a well-defined flake of barium in the ulcer crater. The finding of a hypertonic, hyperperistaltic, and hypermotile stomach is an indication of duodenal ulcer without obstruction. After obstruction has taken place, the stomach becomes markedly hypotonic.

In interpreting röntgenograms of the duodenal cap, it is necessary to bear in mind the possibility of deformity from pressure by the spine. Slight right or left rotation or elevation of the hips will clear up this irregularity. Often it is difficult to differentiate a deformed bulb from one that is incompletely filled. This occurs usually when the bulb is very large and the barium meal passes to the descending portion of the duodenum as rapidly as it is forced through the pyloric ring. The chief point to remember, however, in diagnosing deformities of the duodenal bulb, is that their significance does not depend upon their size, but, rather, upon their persistence.

CONCLUSION

The motility of the gastrointestinal tract, and the consequent röntgenographic variations within the normal range, make the

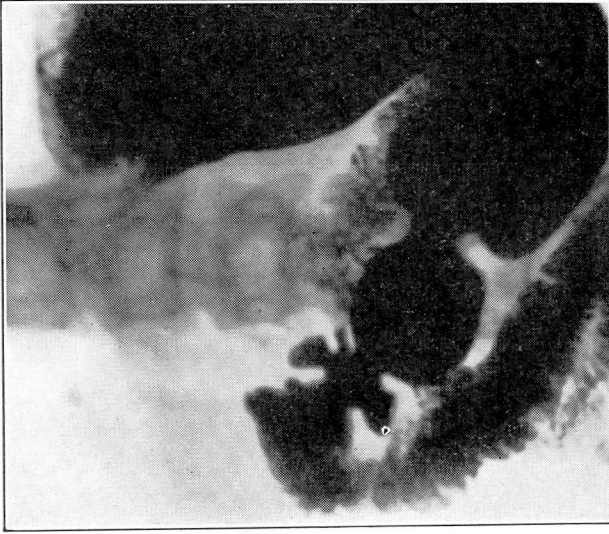


Fig. 9. Röntgenogram showing the characteristic stellate cap produced by duodenal ulcer.



Fig. 8. Röntgenogram showing a diverticulum from the cap of the duodenum.

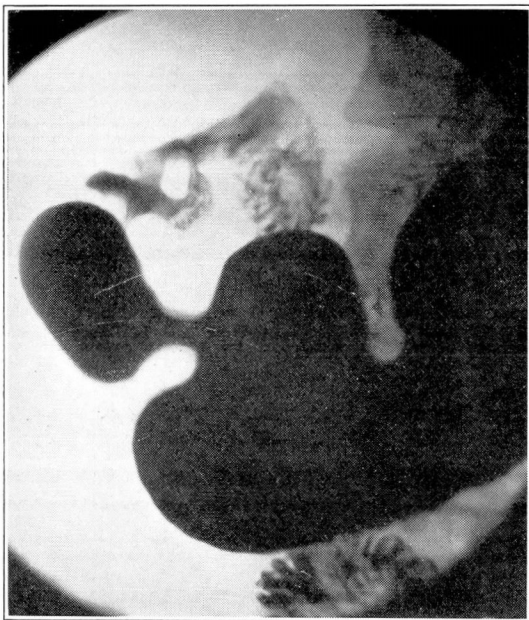


Fig. 10. Röntgenogram showing a deformity of the duodenum resulting from ulcer.

diagnosis of lesions of these organs both difficult and interesting, Complete familiarity with the normal picture is essential, as well as a thorough knowledge of the signs indicative of abnormality, before an interpretation of pathologic changes should be attempted. It is unfortunate that in its earliest stages the disease usually can not be detected röntgenographically, as it is necessary that definite anatomical changes take place before diagnostic shadows are cast on the film.

Many cases of indefinite symptoms centering around the epigastric region are caused by lesions affecting the duodenum. Among these are cholecystitis, producing pressure deformities of the duodenum or periduodenitis with adhesions to the gallbladder, dilatation of the duodenum as a result of various lesions, viscerop-tosis, tumor of the pancreas, duodenal diverticulum, and ulcer of the duodenum.

The illustrations show typical cases of these several conditions, and are presented with the hope that they may prove helpful to the general diagnostician for purposes of comparison.

REFERENCE

Higgins, C. C.: Chronic Duodenal Ileus. Tr. Sect. Surg., General and Abdb., A. M. A., 1928, pp. 127-131.

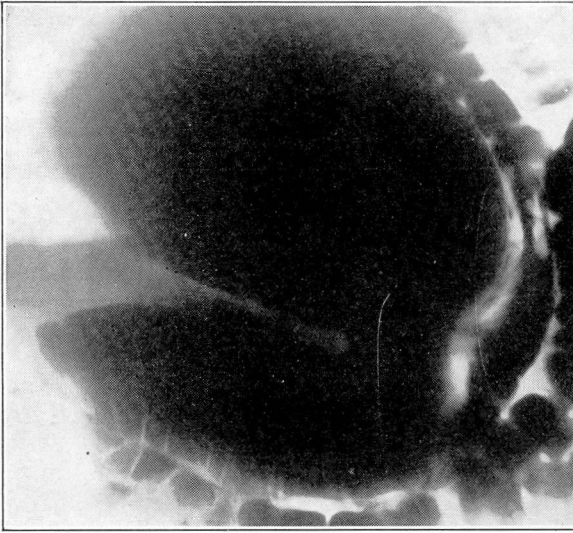


Fig. 12. Röntgenogram showing immense dilatation of the stomach as a result of complete obstruction caused by chronic duodenal ulcer. The colon was filled by a barium enema.

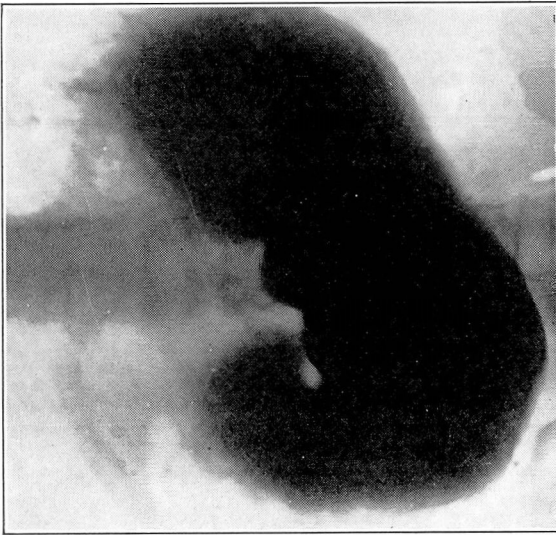


Fig. 11. Röntgenogram showing marked dilatation of the stomach, due to chronic duodenal ulcer producing complete obstruction.