

APPENDICOVESICAL FISTULA

WILLIAM E. LOWER, M.D.,

and

JAMES I. FARRELL, M.D.

Foreign bodies are considered to be an infrequent cause of appendicitis, especially in America, where the fæcalith is not regarded as a foreign body. A survey of the literature (Mitchell,¹ Fowler² and Berger³) shows that approximately 2 to 3 per cent of all cases of appendicitis are caused by true foreign bodies. Mahoney⁴ reports a series of seventy-four cases in which foreign bodies were the cause of appendicitis. In forty of these cases the appendicitis was due to the presence of sharp instruments (pins), and the mortality in thirty-eight was 55.2 per cent. In the majority of these cases the appendicitis occurred in childhood, and no history of swallowing the pin could be obtained.

Keen⁵ reports the case of a man aged twenty-four, who had suffered from dysuria since the age of seven years. At the onset of the dysuria the family doctor found a pin in the urethra and removed it. The patient stated that he did not insert the pin into the penis, nor did he remember swallowing it. At the age of twenty-three he was thought to have a rectovesical fistula secondary to the rupture of a prostatic abscess. Two unsuccessful attempts were made to close this fistula. One year later a laparotomy was performed and a long appendix was found, with its distal end incorporated into the bladder wall. The appendix was separated from the bladder and removed, and the patient made an uneventful recovery.

CASE HISTORY

The patient, a man aged twenty-six years, entered the clinic on June 17, 1930, complaining that he had been troubled with bladder stones since 1917. He had been treated by irrigations for a very painful bladder, and had been cystoscoped twice with negative findings. The patient states that in January, 1925, he fell downstairs and "jarred a stone loose from the bladder wall." An X-ray picture taken at that time revealed a large stone in the bladder surrounding a pin (Fig. 1). This was removed from the bladder one week later. The patient did not recall swallowing the pin, but his mother stated that it had been swallowed when he was about six months old.

In January, 1926, a recurrent calculus was removed from the bladder by cystotomy, and in July, 1927, a third stone was removed *per urethram* by means of a lithotrite. During 1927-1928 the patient suffered intense pain with each urination. During the preceding two years he had attacks of chills and fever, and passed gravel and blood in the urine. Several times these attacks were accompanied by pain in the region of the left kidney, and during the preceding month he had noticed a material in the urine that looked like fæces.

Reprinted by permission of ANNALS OF SURGERY, 1931, Vol. 93, pages 628-630.

APPENDICOVESICAL FISTULA

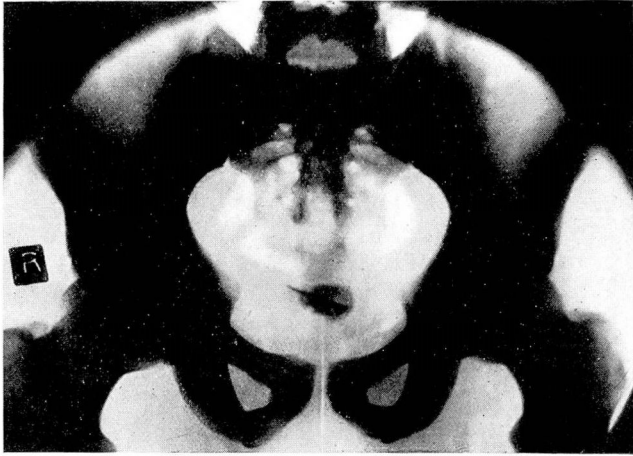

Fig. 1. Vesical calculus from incrustated pin.

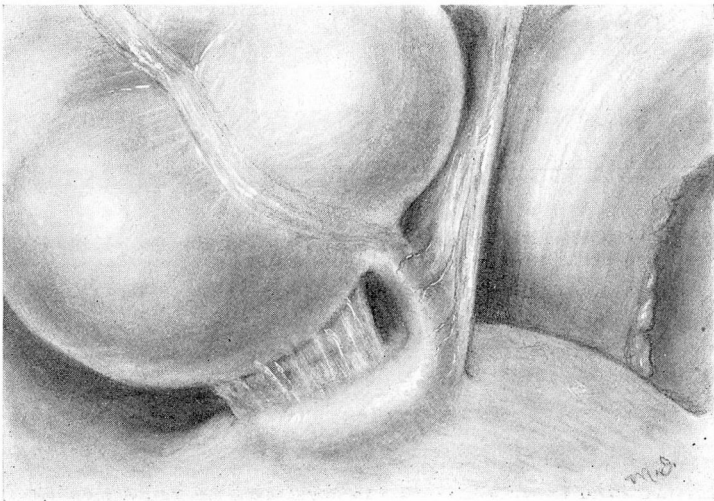


Fig. 2. Drawing showing the appendix and its attachment to the bladder.

X-ray examination revealed no suspicious shadows in the genito-urinary tract. On cystoscopic examination the bladder was found to be very much inflamed. In the posterior portion of the bladder near the top there was a depression which suggested a fistula connecting with the bowel. Considerable faecal material was found in the bladder, suggesting the existence of an enterovesical fistula. In view of the badly inflamed bladder, retrograde pyelograms were not made. Uroselectan was given intravenously, and the urogram showed moderate right hydronephrosis, with a normal ureter. The left renal pelvis appeared to be normal. The left ureter was visualized, but not well visualized, and was normal. The bladder was small but normal.

The patient entered the hospital June 28, 1930; a suprapubic operation was done on the 30th, under spinal anaesthesia. After the small intestines had been packed off into the upper abdomen. The appendix was found adherent to the dome of the bladder (Fig. 2). The enterovesical fistula was in all probability due to the pin swallowed by the patient in infancy which had lodged in the appendix and perforated the bladder. The appendix was removed from the caecum, and its distal end dissected free from the bladder wall. The bladder was closed by inverting the wall with two rows of continuous catgut sutures.

The pathologist reported that the specimen consisted of a portion of the appendix which was adherent to and communicated with the bladder. On one surface it was lined by soft, velvety, irregular mucous membrane such as is seen in the bladder. The surrounding portion of the tissue showed dense fibrous adhesions. Opening into the centre of the patch of mucous membrane was a small tubular structure which allowed the passage of a probe. This was the appendix. (Fig. 3.)

After the operation the patient made an uneventful recovery, and was discharged in two weeks. A month later he returned to the clinic, reporting that he was free from symptoms. The urine was clear, amber colored, and alkaline in reaction. The specific gravity was 1.020. It contained neither albumin nor sugar, and the microscopic examination of the urine gave essentially negative findings.

In reviewing the literature, only one other report was found of a case of appendicovesical fistula. However, although reports of such

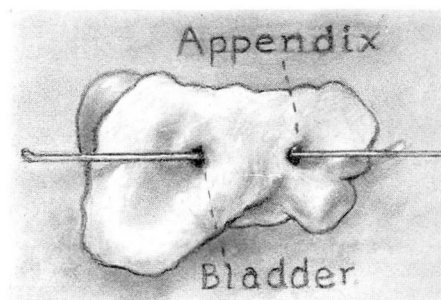


Fig. 3. The fistulous tract excised showing the connection between appendix and bladder.

cases are rare, the presence of foreign bodies in the appendix is not uncommon.

APPENDICOVESICAL FISTULA

Urologists frequently find foreign bodies in the bladder, but it usually is believed that they have been inserted into the urethra, slipped beyond the patient's control, and ascended to the bladder. Once there, they become encrusted with mineral salts and a calculus is formed. When our patient stated that a pin was found in the bladder, we supposed that it had been introduced through the urethra, but subsequent events in his case led to the belief that the pin swallowed in infancy lodged in the appendix and penetrated the bladder, causing an appendicovesical fistula. The bladder stone with the pin was removed in January, 1925, but the fistula persisted, and was the cause of the re-formation of the bladder stones. Since the removal of the appendix and closure of the fistula the patient has been free from urinary symptoms.

REFERENCES

- 1 Mitchell, J. F.: The Presence of Foreign Bodies in the Vermiform Appendix, with Especial Reference to Pointed Bodies. *Bull. Johns Hopkins Hosp.*, vol. x, p. 35, 1899.
- 2 Fowler, R. H.: Foreign-body Appendicitis; with Especial Reference to the Domestic Pin; an Analysis of Sixty-three Cases. *Annals of Surgery*, vol. lvi, pp. 427-436, 1912.
- 3 Berger, J.: Appendicitis from Foreign Bodies. *Presse med.*, vol. xxxii, pp. 338-390, May, 1924.
- 4 Mahoney, S. A.: Foreign Bodies as a Cause of Appendicitis. *Boston Med. and Surg. Jour.*, vol. clxxxiv, p. 113, February 3, 1921.
- 5 Keen, W. W.: A Case of Appendicitis in Which the Appendix Became Permanently Soldered to the Bladder, Like a Third Ureter, Producing a Urinary Fecal Fistula. *Tr. Am. Surg. A.*, vol. xvi, p. 243, 1898.