

TUMOR OF THE SPINAL CORD ASSOCIATED WITH BILATERAL ACOUSTIC TUMORS

Report of a Case

W. JAMES GARDNER

Reprinted by permission from the ARCHIVES OF NEUROLOGY AND PSYCHIATRY, November, 1930, Vol. 24, pp. 1014-1022.

The patient, a report of whose case follows, is a member of a family in which bilateral deafness has been transmitted as a true mendelian dominant character. The condition has been traced through five generations of the family, which includes 217 members.¹ Thirty-eight members have been affected. Of these thirty-eight, fifteen subsequently became blind, the blindness being preceded by headache and vomiting in each case in which information was available. Of the deaf and blind persons, four were examined prior to death, and were found to have choking of the optic disks with secondary atrophy. Of the deaf persons, seven were personally examined. Five of these had entire absence of vestibular responses in the Barany test. In the other two, a sluggish response was obtained from the left horizontal canal, but the remaining semicircular canals were nonfunctioning. In addition, four subjects were found who had little or no impairment of hearing, but whose vestibular responses were absent in the Barany test. These Barany observations, together with the neurologic signs which these persons presented, made the diagnosis of bilateral acoustic tumors practically indisputable. The two affected members of this family who came to necropsy had bilateral acoustic neurofibromas. There was practically no associated evidence of von Recklinghausen's disease in this family, and at the time of the investigation, there was nothing to indicate the presence of tumors elsewhere than on the acoustic nerves.

Following publication of the first report on this family, however, one of the affected members, the subject of the following case history, developed symptoms of a tumor of the spinal cord. The tumor, which proved likewise to be a neuro-fibroma, was correctly localized and successfully removed. Therefore, it seems probable that other affected members of this family may also have tumors on other portions of the central nervous system.

¹ Gardner, W. J., and Frazier, C. H.: Bilateral Acoustic Neurofibromas; A Clinical Study of Field Survey of a Family of Five Generations with Bilateral Deafness in Thirty-eight Members, *Arch. Neurol. and Psychiat.* 23:266 (Feb.) 1930.

REPORT OF CASE

Clinical History.—VA^a (fig. 1), a man, was admitted to the neurological service of the Cleveland Clinic Hospital on January 22, 1930, having been referred by Dr. T. K. Wood, of Muncy, Pa. The chief complaint was weakness of both legs and of the left hand.

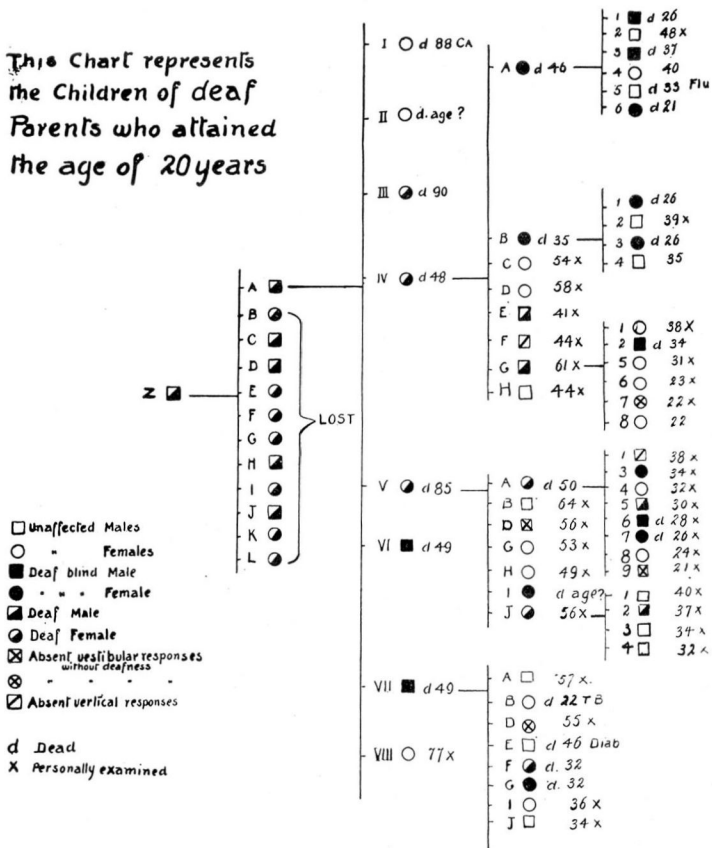


Fig. 1 — Chart of the patient's family tree. This chart includes only the children of affected parents who attained the age of 20 years, at which average time the condition became manifest. For the sake of simplicity, the charts representing the complete family tree have been omitted. These may be seen by consulting the original article (*Arch. Neurol. and Psychiat.* 23:266, February, 1930).

The patient who is the subject for this report is indicated as VA₉.

The patient had been a little unsteady on his feet, especially after dark, for a period of four or five years. For about two years there had been occasional indefinite cramps in the left hand. For over a year there had been bilateral tinnitus, marked on the left side. For

nine months the patient had noticed some difficulty in retaining feces, and constipation requiring catharsis had been present. For four months there had been progressive weakness and atrophy of the muscles of the left hand and also progressive weakness of both legs. Pain had not been a symptom.

Physical Examination.—The patient was a large, healthy-looking man. His gait was ataxic and lurching, and he tired readily on walking. There were no other points of interest in the physical examination.

Neurologic Examination.—The positive signs were: The retinal veins were slightly engorged, but the optic disks were not choked. A fine horizontal nystagmus appeared on lateral rotation of the eyes. There was a slight impairment of hearing for high tones in the left

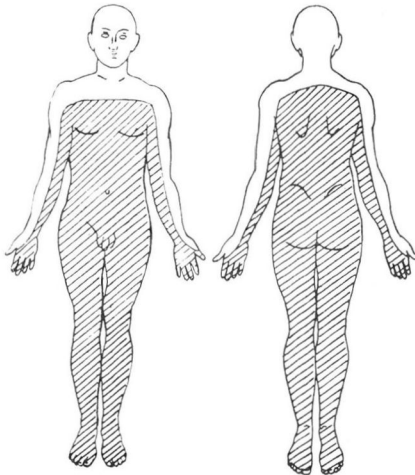


Fig. 2 — Preoperative level impaired for tactile, pain and thermal perception

ear. The lower extremities were weak and spastic. The grasp of the right hand was slightly weak, and the left was extremely weak and flaccid. The dynamometer readings were: right 80, left 5. There was distinct atrophy of the interossei and hypothenar muscles of the left hand and a lesser degree of atrophy in the flexors and extensors in the forearm.

The right biceps and triceps reflexes were normal; the left were slightly exaggerated. The right patellar reflex was normal, but the left was decidedly hyperactive. On testing the achilles reflexes, a bilateral ankle clonus was elicited. The Babinski response was positive on both sides. The corneal reflexes were normal. The abdominal

and cremasteric reflexes were absent. The Romberg sign was strongly positive. There was no dysmetria in the finger-to-nose or heel-to-knee tests. There was decided impairment of tactile, pain and thermal perception up to and including the eighth cervical segment (fig. 2). It was not possible to demonstrate a pilomotor or vasomotor level. Horner's syndrome was not present.

Diagnosis.— On the basis of the atrophy of the muscles of the left hand, the sensory level and the freedom from pain, the diagnosis was neurofibroma of the left eighth cervical anterior root.

Vestibular Studies.— Tests by Dr. W. V. Mullin disclosed that the right labyrinth was entirely nonfunctioning, while a very sluggish response was obtainable from only the horizontal canal on the left side.² The hearing was normal with the right ear, but there was

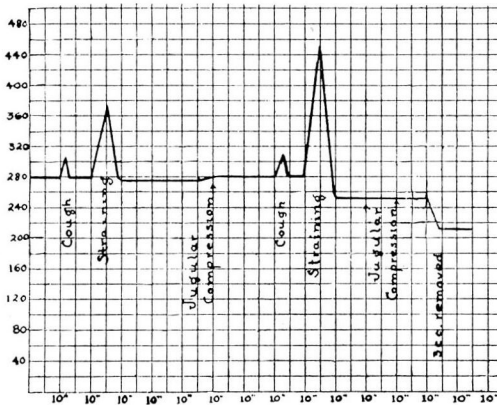


Fig. 3 — Graph of the spinal fluid pressure responses, indicating practically a complete block on jugular compression and a partial block on straining.

a mild nerve deafness on the left. These observations, together with the family history, indicated the presence of bilateral acoustic tumors.

Spinal Fluid Examination.— At the spinal puncture, the initial pressure was found to be 280 mm. of water (fig. 3). The pressure rose to 295 when the patient coughed, and returned promptly to 280. Straining increased the pressure to 365, and it fell to 275 on release. Jugular compression for ten seconds caused a rise only to 280. On straining once more, the pressure rose to 445, and fell promptly to 250. Jugular compression was again applied for ten seconds, with no response. The withdrawal of 3 cc. of fluid reduced

² Similar results had been obtained by Dr. James A. Babbitt and Dr. Lewis Fisher, of Philadelphia, a year previously.

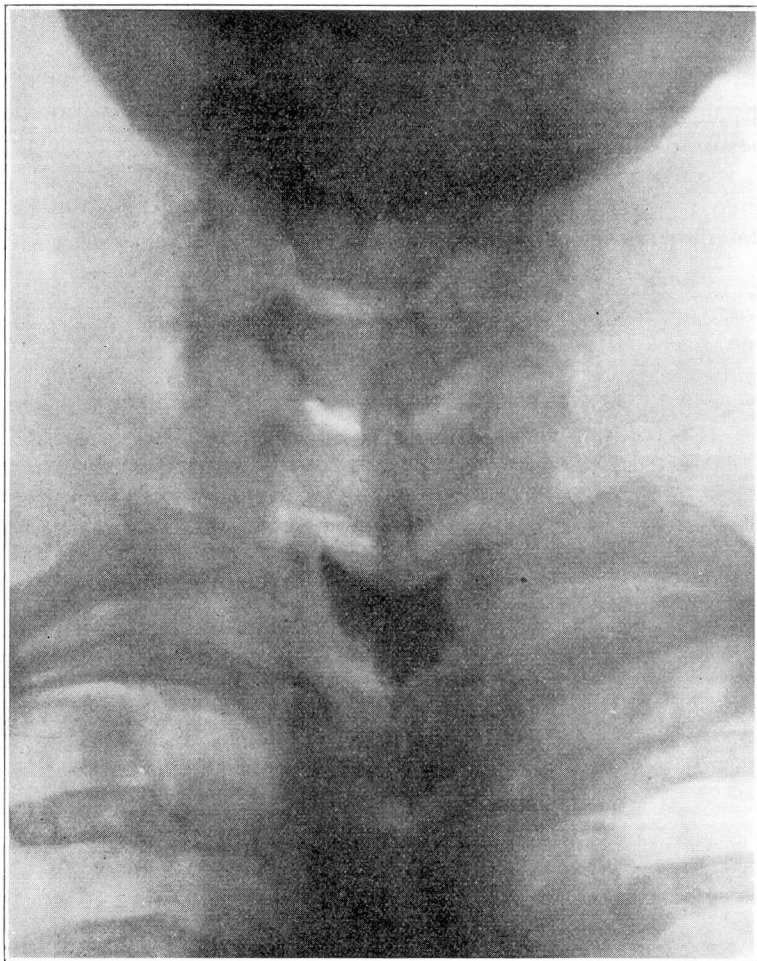


Fig. 4 — Roentgenogram made after the introduction of 2 cc. of campiodol into the lumbar sac. The lower border of an oval tumor is outlined.

the pressure to 210 mm. of water. The jugular-compression tests indicated a complete block from above downward, but the response to straining indicated that the block was not complete from below upward, as the pressure after straining was found to be below the initial pressure.³ A specimen of the fluid was faintly yellow. It contained 5 cells per cubic millimeter and the globulin was four plus. The Wassermann and colloidal gold reactions were negative.

³ The latter point is of interest and can be demonstrated in many cases of partial block. It has not received mention in the literature.

In an effort to exclude the presence of other spinal tumors below the level of the main lesion, an injection of iodized oil was performed in the lumbar region. Roentgenograms taken with the patient in the head-down position showed that the oil stopped at a point opposite the middle of the body of the first dorsal vertebra, where it outlined the lower border of an oval tumor (fig. 4). No evidence of obstruction of the oil elsewhere was manifest. Operation was decided on, therefore.

Operation.— A laminectomy was performed, the laminae of the third cervical to the first dorsal vertebrae, inclusive, being removed. On opening the dura, the arachnoid membrane was found to be non-pulsating except at the extreme upper end of the exposure. In the upper two-thirds of the exposure, the cord was displaced backward and flattened as though by a tumor on its anterior aspect.

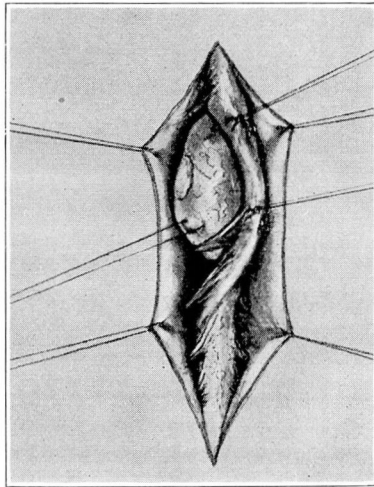


Fig. 5 — The tumor in situ after it had been freed from its distal attachment to the left eighth anterior cervical root.

The eighth cervical and first thoracic posterior roots were sectioned on the left side, after which the cord was gently rotated and pulled to the right. This disclosed a yellowish-pink, smooth, firm tumor anterior to the cord. The tumor was firmly adherent where the left eighth cervical root made its exit from the dural sac (fig. 5). The tumor was freed at this point with a scalpel and removed from the canal. The left eighth cervical anterior root was found to be thickened and elongated up to the point at which it made its entrance into the tumor. About 2 cm. of the proximal portion of this root was removed with the tumor. The point of attachment of the tumor to

SPINAL CORD TUMOR

the distal portion of the root was then thoroughly curetted and painted with Zenker's solution. The cord was replaced in its normal position in the canal and the wound was closed. Aside from a minor wound complication, the patient's convalescence was uneventful.

Course.— One month after the operation, a neurologic examination showed the following: The gait was slightly ataxic and the

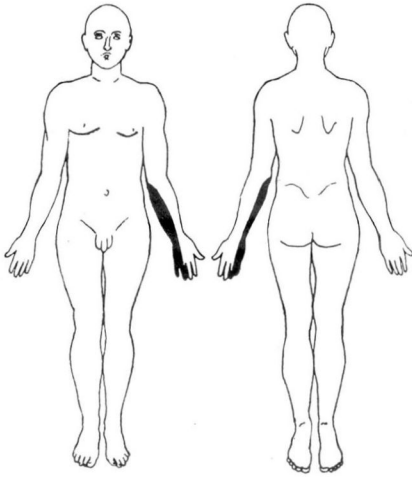


Fig. 6 — Postoperative anesthesia resulting from operative section of the eighth cervical and first thoracic posterior roots.

Romberg test was mildly positive. Nystagmus was present as before the operation. The biceps, triceps and achilles reflexes were normal. The left patellar reflex was moderately exaggerated; the right was normal. The Babinski response was negative, and there was no




Fig. 7 — Photograph of the tumor after its removal, showing the point of entrance of the nerve. Its point of exit is marked by the abraded area in the capsule.

ankle clonus. There was a slight improvement in the strength of the left hand, but the atrophy was unchanged. There was complete anesthesia on the ulnar side of the left forearm and hand (fig. 6).

Pathologic Report.—Grossly, the specimen consisted of an oblong, flattened, encapsulated tumor, removed from the anterior root of the left eighth cervical nerve (fig. 7). The proximal portion

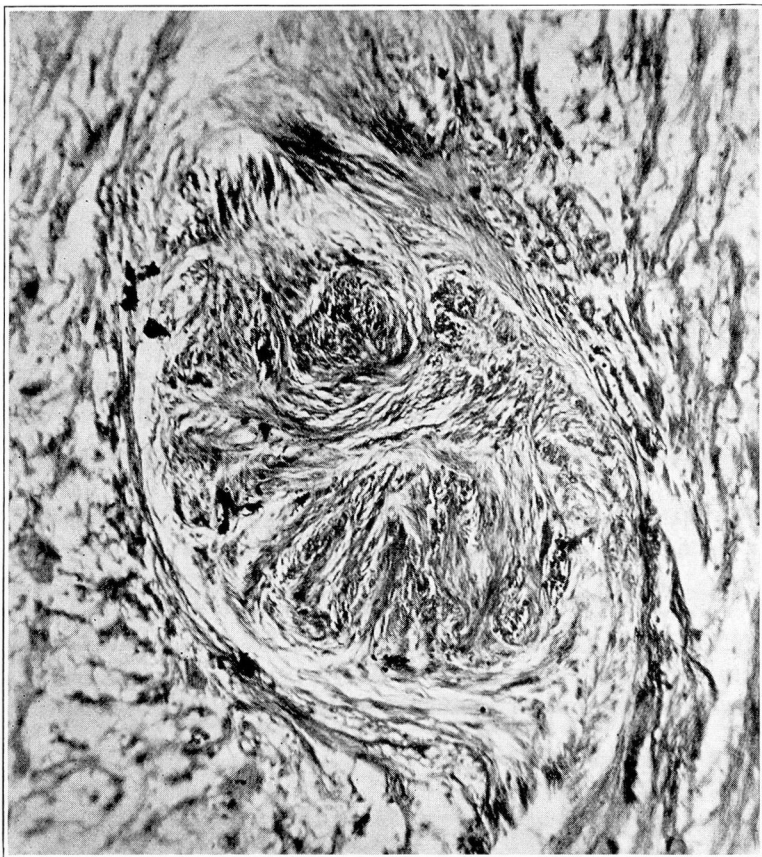


Fig. 8 — Photomicrograph showing the typical structure of a neurofibroma. Hematoxylin and eosin stain; X 125.

of the anterior root was present, measuring 1.5 cm. in length and 0.5 cm. in diameter. It was grayish in color, moderately soft, and appeared edematous. Distally, the anterior root expanded into a tumor, which was flattened and roughly oval in shape, measuring 3.2 by 2.2 by 1.3 cm., and weighing 8 gm. Directly opposite the anterior root was an abraded area marking the point where its

SPINAL CORD TUMOR

fibers continued distally to join the dorsal root. The remainder of the tumor was covered by a thin membrane containing numerous fine blood vessels. The specimen was preserved in Zenker's solution before sectioning (fig. 8).

Microscopically, a section through the nerve showed a mass of tumor tissue made up of bundles of spindle cells running in various directions, with a tendency to form whorls. The nuclei varied con-

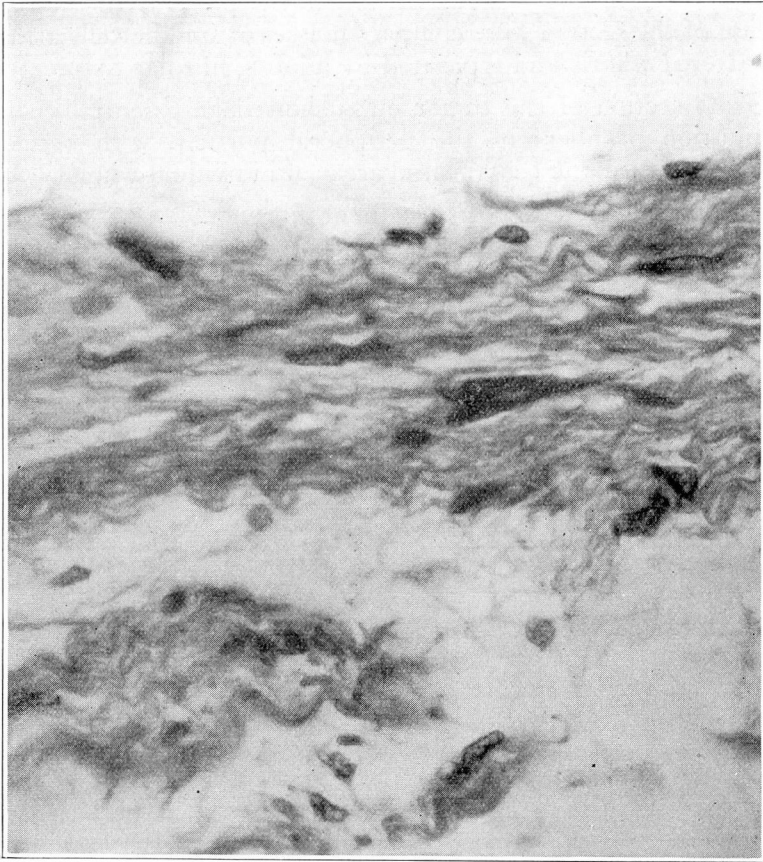


Fig. 9 — Same field as in figure 8; X 600

siderably, generally being elongated, but in many instances they were short, oval, and sometimes large, irregular or stellate forms. There was a large amount of blue-staining intercellular substances, principally fibrillar. Along one surface of the section there were fairly large areas of loosely arranged, pink-staining tissue, suggestive

of nerve fibers with degenerative changes. The tumor mass itself had a well defined capsule along one surface. On the opposite surface, the capsule was not so distinct. No collagen fibers were shown with the van Gieson stain.

A longitudinal section of the tumor, fixed with Zenker's solution, included at one end a portion of nerve trunk which had a structure similar to that seen in the section through the nerve. The remainder of the section consisted of an outer lamellated zone of long, wavy fibers, loosely arranged and with few nuclei present. In the central portion of the section were compact masses of spindle cells arranged in scattered whorls and separated by a loose, fibrillar tissue.

Gross section of the tumor mass showed an essentially similar distribution of fibers in the peripheral portion, with occasional whorls, and near the center large areas of individual whorls.

The pathologic diagnosis was neurofibroma.