

# TRAUMATIC SUBDURAL HEMATOMA

WITH PARTICULAR REFERENCE TO THE LATENT INTERVAL

W. JAMES GARDNER, M.D.

*Reprinted by special permission from the ARCHIVES OF NEUROLOGY AND PSYCHIATRY, 27:847-855, April, 1932.*

Traumatic subdural hematoma is a definite clinical entity that has been given considerable attention in the medical literature since Virchow's classic description<sup>1</sup> of "hematomas of the dura mater" in 1857. The lesion consists of an encysted collection of blood, situated between the dura and the arachnoid membranes, usually over the convexity of the cerebral hemisphere. It is my aim to sketch briefly the clinical and pathologic aspects of this interesting lesion and to dwell particularly on the reason for its delayed clinical manifestations.

The majority of published reports of cases of traumatic subdural hematoma are similar in one respect, that is, in the occurrence of a latent interval between the reception of trauma and the onset of pressure symptoms. The cranial trauma that was responsible may have been severe or so trivial as to be readily forgotten. In many instances a history of trauma that had been denied previously has been obtained after operative verification of the lesion has led to closer questioning of the patient or his relatives. The latent interval may vary from a few hours to many months or even years, and during this period the symptoms may be slight or even entirely absent.

The onset of symptoms may be insidious or rapidly progressive. The most common symptom is headache, occasionally associated with vomiting. Mental disturbances occur more frequently in the presence of this condition than in the case of any other space-filling intracranial lesion. Inequality of the pupils, papilledema and pyramidal tract signs are frequently present. Convulsions, either jacksonian or generalized, may occur. However, lateralizing signs are not of great significance, since the lesion is often found on the side opposite to that which is indicated by the symptoms. In a certain percentage of cases the lesion is bilateral.

During the past few years, seven cases of traumatic subdural hematoma have been studied in the neurosurgical department of the Cleveland Clinic Hospital. Five of the patients recovered following an operation, while two died with the condition undiagnosed (Fig. 1). The following case is a fairly typical one.

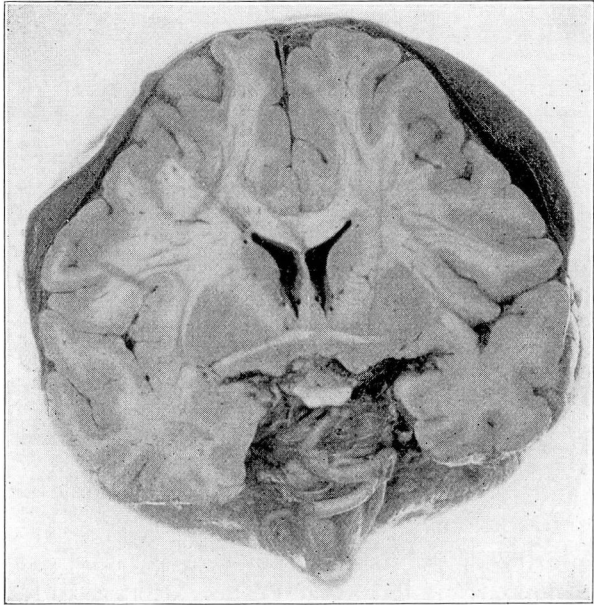


Fig. 1. Postmortem specimen of bilateral subdural hematoma.

#### REPORT OF A CASE

*History.* A man, aged 52, was admitted to the Cleveland Clinic on Feb. 4, 1930, with lapse of memory as the chief complaint. On Dec. 12, 1929, he had driven his automobile into a ditch, colliding with a concrete culvert. He was unconscious for about an hour and a half. On regaining consciousness he did not recall events that had occurred for approximately ten minutes prior to the accident. He sustained a small laceration over the left eye. He remained at home for four weeks, during which time he did not feel himself; after this he resumed work as a certified public accountant, feeling that he was entirely well. Three weeks later, he had a period of complete amnesia lasting for forty-eight hours. For this reason he was referred to the clinic by Dr. Paul Zinkham, of Ravenna, Ohio.

*Examination.* The patient was alert mentally and apparently in good health; the temperature was normal, the pulse rate, 88, and the blood pressure, 126 systolic and 90 diastolic. The ocular fundi presented an early papilledema. Roentgen examination of the skull gave negative results for any evidence of fracture. Neurologic examination gave negative results. The spinal fluid pressure was 240 mm. of water. The fluid was clear and colorless and contained 2 cells. The Wassermann and colloidal gold reactions were negative.

*Course.* Forty-eight hours after admission, the patient lapsed into semistupor, and a complete paralysis of the left third nerve developed, with a slight weakness in drawing up the right corner of the mouth. The pulse rate was 48, and the blood pressure, 188 systolic and 144 diastolic. An immediate operation was decided on, the preoperative diagnosis being intracranial hemorrhage.

*Operations.* Since the symptoms indicated a lesion on the left side, the usual subtemporal decompression was performed on that side. Except for increased intracranial pressure, the observations at the operation were entirely negative. Forty-eight hours later, the patient's condition was still more alarming, and because the presence of a clot on the opposite side was suspected a right subtemporal decompression was performed. When the dura was incised, a large thin-walled cyst containing dark, semifluid blood was evacuated. The underlying cortex was entirely normal. No fresh bleeding followed the evacuation, and the wound was closed without drainage. The patient made a complete uneventful recovery, and has remained well to date.

*Summary.* In this case a man sustained a cranial trauma resulting in mild symptoms for four weeks, followed by a symptom-free interval of three weeks. Seven weeks after the trauma, he had a three-day period of amnesia, and one week later passed into stupor. An encysted subdural hematoma was found on the side opposite to that indicated by the symptoms. This history differs in but few details from that in many cases reported in the literature.

#### CHARACTER OF THE LESION

The gross as well as the microscopic characteristics of these lesions are of interest. Grossly, the outer wall of the hemorrhagic cyst, which is next to the dura, is a great deal thicker than the inner wall, which is next to the arachnoid. The outer wall is adherent to, but strips easily from, the inner surface of the dura, leaving relatively few bleeding points. As a rule, the inner wall is not at all adherent to the arachnoid and is avascular. The contents of the cysts vary from a thin yellow or brown fluid containing shaggy remnants of degenerating clot to a firm currant-jelly clot.

The microscopic appearance of the neomembrane surrounding the degenerating clot has been well described by many authors, notably by Putnam and Cushing<sup>2</sup> in 1925. Briefly, the outer wall may be said to resemble a highly vascular layer of granulation tissue of varying thickness, slightly adherent to the inner surface of the dura. Putnam and Cushing were particularly impressed with the frequent occurrence of a layer of large irregular "mesothelial-lined

blood spaces" in the neomembrane just below the line of demarcation between the dura and the membrane. The inner wall of the cyst is much thinner, and consists of a layer of fibrous tissue, a few cells in thickness, with a single layer of mesothelium on the surface next to the arachnoid. This portion of the membrane is entirely avascular.

In cases of subdural hematoma it is seldom possible to demonstrate the original source of the hemorrhage. The preponderance of evidence, however, would seem to indicate that the vascular rupture occurs in one or more of the cerebral veins as they cross the subdural space to enter the longitudinal sinus.<sup>3</sup> Certainly this is the most likely source of subdural hemorrhage during the course of a cranial operation.

#### THE LATENT INTERVAL

With this introduction, consideration may be given to the latent interval between the occurrence of the trauma and the onset of symptoms of increased intracranial pressure. In analyzing a large series of case reports of traumatic subdural hematoma, it is difficult to escape the conviction that the lesion must undergo a progressive augmentation in size subsequent to its initial formation. Otherwise, why should a patient, apparently completely recovered from the effects of a cranial trauma, begin to show symptoms of increasing intracranial pressure some weeks or months later?

The most obvious explanation of the progressive enlargement of these lesions is that there occurs a slow, continuous or perhaps an intermittent bleeding from the responsible vessel.<sup>3</sup> Yet, nowhere else in the body does an injured blood vessel behave in this fashion. These lesions occur in persons of any age; vascular disease does not constitute an etiologic factor, and a hemorrhagic diathesis has never been demonstrated.

It has been suggested<sup>3</sup> that the granulation tissue that constitutes the outer wall of the hematoma may be the seat of repeated hemorrhages, either from a capillary source or from the large "mesothelial-lined blood spaces," which appear to communicate with the capillaries. Arguments against this hypothesis are that spontaneous hemorrhage does not occur from newly formed blood vessels elsewhere in the body, and furthermore, the gross contents of a clinically progressive hematoma, as disclosed at operation or necropsy, are usually found to be perfectly homogeneous.

From the microscopic appearance of the membrane and from negative cultural studies of the contained fluid, it does not appear

that infection can be responsible for a progressive enlargement of these lesions.

Taking all factors into consideration, it would appear that the peculiar behavior of these lesions must be the direct result of their environment. The subdural space has received surprisingly scant attention in the medical literature. Although the neurologic surgeon traverses this space almost daily, he rarely gives it much thought. Yet it is unique anatomically — a potential space lined with mesothelium, its outer wall constituted by the dura and its inner wall by the avascular arachnoid, with the cerebrospinal fluid space just beneath.\* Curiously, nature has provided no obvious means of draining this space. The pericardial, pleural and peritoneal spaces all have their subserous systems of lymphatics to carry off debris. The presence of lymphatics, however, has never been demonstrated in the dura or in the arachnoid, unless one considers the subarachnoid spaces as lymphatic channels. This apparent lack of adequate lymphatic drainage from the mesothelial-lined subdural space, therefore, may provide the explanation for the curious progressive behavior of the subdural hematoma. Since the subdural space continues over the pachimion bodies, as demonstrated by Winkelman and Fay,<sup>5</sup> it seems likely that elimination of subdural extravasations may occur at these points as well as along the nerve sheaths, provided that the extravasation is not too large.

#### EXPERIMENTAL STUDIES

In order to study the behavior of these lesions, attempts were made to reproduce them in animals, in spite of the failures of previous investigators.

In five dogs, a trephine opening was made over the parietal area, which was followed by a cisternal puncture to relax the unopened dura. With a fine curved hypodermic needle, from 0.7 to 3 cc. of whole, unclotted blood from the femoral vein was injected beneath the dura. A muscle graft was then placed over the puncture wound to seal it, the button of bone replaced and the wound closed. When the animals were killed, from three weeks to three and one-half months later, there was little or no gross evidence of the injected blood beneath the dura. This has also been the experience of previous investigators in this field.<sup>6</sup>

That an overlying cranial defect might in some way favor the regression of a subdural hematoma was suggested by the fact that

\*Penfield, by an ingenious process, has demonstrated the presence of a small amount of yellow fluid in the subdural space of the dog and he has also described a pathologic collection in the human being.

a progressive type of lesion never follows a cranial operation. Therefore, in order to avoid the presence of a cranial defect directly over the experimental lesion, the following procedure was carried out on seven dogs.

A small drill hole was made in the parietal region and was followed by a cisternal puncture with the removal of from 5 to 10 cc. of fluid. A curved lumbar puncture needle was then passed through

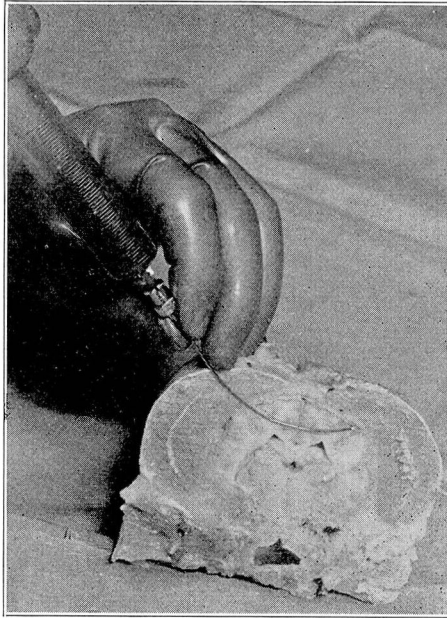


Fig. 2. Method of transcerebral injection of blood into the subdural space.

the brain across the midline until the point came to rest beneath the intact cranial vault on the side opposite to the drill hole. At this point from 3 to 11.5 cc. of whole, unclotted blood from the femoral vein was injected (Fig. 2). Again, at autopsy little gross evidence of the injected blood was found if more than a couple of weeks had elapsed since its introduction.

In this series of experiments large dogs, weighing from 45 to 60 pounds (20.4 to 27.2 Kg.), were used in order that larger amounts of blood might be injected. The animal into which 11.5 cc. was injected died within a few hours after the experiment had been performed. At necropsy, the blood was found to be generally distributed

over the hemisphere, but at no point was the clot more than 1.5 mm. in thickness. This suggested that the failure to reproduce the progressive clinical lesion might be due to failure to obtain a sufficiently thick layer of injected blood in the experimental animal.

Attention was then diverted temporarily to a study of the comparative osmotic pressures of the blood and spinal fluid.




Fig. 3




Fig. 4

Fig. 3. Method of demonstrating the osmotic imbalance of the protein in the blood and spinal fluid. The beaker contains the spinal fluid, and the inverted funnel is closed with a tambour of cellophane containing the blood.

Fig. 4. Cellophane sac containing whole blood immersed in spinal fluid for the purpose of observing the increase in weight of the sac.

Semipermeable collodion membranes were first used, but were soon discarded on account of their fragility. Cellophane proved to be much more adaptable. This membrane was found to be permeable to the molecules of salts and dextrose of whole blood but not to the larger molecules of protein. In experiments *in vitro* it was found that when whole blood was separated from cerebrospinal fluid by a membrane of cellophane, no. 300, there was an osmotic imbalance of about 20 mm. of water in favor of the blood (Fig. 3). It was therefore assumed that 20 mm. of water represented

the fractional osmotic pressure of the proteins of the blood against that of the proteins of the spinal fluid.

Further tests were then made. With aseptic precautions, two cellophane sacs containing whole blood taken from a patient on a fasting stomach were dialyzed against the patient's spinal fluid (Fig. 4). One test was carried out in the refrigerator at 0 C. and one in the incubator at 37 C. Each day, the sacs were removed from the fluid and weighed aseptically. The initial weight of the sac that was kept at 0 C. was 1.864 Gm. In eighteen hours, it had increased 37.1 per cent of its original weight; in forty-four hours, 57 per cent, and in sixty-six hours, 73.5 per cent. The initial weight of the sac that was kept at 37 C. was 1.286 Gm. In eighteen hours, it had increased 59 per cent of its original weight; in forty-four hours, 78.2 per cent, and in sixty-six hours, 93 per cent.

In a series of eight dogs, cellophane sacs, of known weight, containing whole blood from the femoral vein were inserted in the subdural space. The sacs with their contents were removed later and weighed in order to note any increase in weight. In five of the animals similar sacs were also placed in the rectus sheath or peritoneal cavity. In one animal, which was killed after fifty-one days, both sacs were found to be ruptured. In the remaining animals the sacs were intact when removed from three to eighteen days after implantation. After removal each sac was found to have gained from 39 to 103 per cent in weight. With one exception, the control sacs in the rectus sheath and peritoneal cavity gained more in weight than did the sacs in the subdural space.

*Tests with Living Neomembrane.* An opportunity of testing the permeability of the living neomembrane then presented itself. A portion of an inner cyst wall was removed from a patient at operation, two and one-half months after a cranial trauma.

Seventeen cubic centimeters of the fluid contents of the hemorrhagic cyst was dialyzed against 52 cc. of the patient's spinal fluid, the cyst wall being used as the dialyzing membrane. This preparation was made under aseptic precautions and placed in the refrigerator for sixteen hours. At the end of this time the hemorrhagic fluid had increased 2.9 per cent in volume after it had returned to room temperature. The total protein\* of the surrounding spinal fluid, estimated by the Kjeldahl method, was the same after the experiment as it had been before.

\*The protein content of the cyst fluid was 8.2921 per cent. The protein content of the spinal fluid was 0.854 per cent before and 0.8406 per cent after dialysis. This slight difference is within the limits of experimental error. The measurements were made by Dr. John W. Shirer.



## COMMENT

The measurements indicate that the neomembrane is permeable to fluid but not to protein molecules, and that an osmotic imbalance exists which is in favor of the cyst contents.

In the light of the experiments cited, the latent interval in cases of subdural hematoma may be explained as follows:

Following a cranial trauma, hemorrhage occurs into the subdural space, probably from a rupture of one of the cerebral veins where it crosses the space to enter the sagittal sinus. A large amount of blood having escaped, becomes clotted, and within the course of a few days this clot is surrounded by a capsule of mesothelium and connective tissue growing out from the dura. That this capsule forms with remarkable rapidity is attested by clinical as well as by experimental observations.<sup>8</sup> The portion of the capsule next to the dura becomes invaded with nutrient capillaries from the dura and thus attains a greater thickness than does the avascular portion that is adjacent to the avascular arachnoid. The encapsulated clot then undergoes partial liquefaction, with a resultant fluid high in protein content. This fluid is separated from the cerebrospinal fluid, which is of low protein content, merely by the thickness of a few layers of cells constituting the inner wall of the cyst and the arachnoid membrane. There then results an ideal set-up for osmotic interchange. Since the neomembrane is impermeable to the large protein molecules in the hemorrhagic fluid, an osmotic imbalance in favor of the hemorrhagic fluid must exist, resulting in the withdrawal of cerebrospinal fluid into the cyst. This, of course, causes a progressive enlargement of the hemorrhagic cyst and eventually a rise in intracranial pressure.

## CONCLUSIONS

1. In cases of subdural hematoma there occurs a gradual increase in the size of the lesion following its initial formation.
2. The progressive behavior of these lesions is due to their environmental conditions, particularly to the inadequacy of lymphatic drainage from the mesothelial-lined subdural space.
3. The actual increase in size of the subdural hematoma is due to an accession of tissue fluid, particularly spinal fluid.
4. This fluid is drawn into the hemorrhagic cyst through the semi-permeable arachnoid membrane and adjacent cyst wall by the osmotic tension of the blood proteins contained in the cyst.
5. It is difficult, if not impossible, to reproduce in the dog the clinical picture of subdural hematoma.

REFERENCES

- 1 Virchow, R.: Das Hämatoma der Dura mater, Verhandl. d. phys.-med. Gesellsch. 7:134, 1857.
- 2 Putnam, T. J., and Cushing, Harvey: Chronic Subdural Hematoma: Its Pathology, Its Relation to Pachymeningitis Hemorrhagica and Its Surgical Treatment. Arch. Surg. 11:329, September, 1925.
- 3 Trotter, Wilfred: Chronic Subdural Hemorrhage of Traumatic Origin and Its Relation to Pachymeningitis Haemorrhagica Interna. Brit. J. Surg. 2:271, 1914.
- 4 Penfield, —: The Cranial Subdural Space. Anat. Rec. 28:174, 1924.
- 5 Penfield, —: Subdural Effusion and Internal Hydrocephalus. Am. J. Dis. Child. 26:383, October, 1923.
- 6 Winkelman, N. W., and Fay, T.: Pacchionian System: Histologic and Pathologic Changes with Particular Reference to Idiopathic and Symptomatic Convulsive States. Tr. Am. Neurol. A. 55:274, 1929.
- 7 Putnam, T. J., and Putnam, I. K.: The Experimental Study of Pachymeningitis Haemorrhagica. J. Nerv. & Ment. Dis. 65:260, 1927.