

JAUNDICE IN HEART DISEASE

A. CARLTON ERNSTENE

Reprinted by special permission from THE MEDICAL CLINICS OF NORTH AMERICA, 15: 1005-1013, January, 1932.

Jaundice not infrequently occurs in patients with advanced stages of heart disease. The patients for your consideration today illustrate the diversity of mechanisms responsible for the development of icterus in various cardiac disorders and the importance of the sign in accurate diagnosis, prognosis, and treatment.

In a recent excellent review Rich¹ has divided all cases of jaundice into two groups: retention jaundice and regurgitation jaundice. Jaundice of the retention type develops whenever the liver becomes functionally unable to excrete bilirubin in the amounts presented by the blood for disposal. In this form of icterus, the blood plasma gives the indirect van den Bergh reaction, and the urine does not contain bilirubin or bile salts. On microscopic examination of the liver, the bile ducts are patent, but the liver cells usually show atrophy or cloudy swelling. Jaundice of the regurgitation type results from pathologic changes in the liver which permit the escape of whole bile from bile canaliculi into the blood stream. In this form of icterus, the blood plasma gives the direct van den Bergh reaction, and the urine contains bilirubin and bile salts. On pathologic examination, there is rupture of the bile canaliculi resulting from obstruction of the ducts or from necrosis of the hepatic cells. I shall follow this classification in discussing today's cases.

Jaundice in Nonvalvular Heart Disease with Congestive Myocardial Failure. The bilirubin content of the blood is increased in practically all cases of congestive myocardial failure,² and occasionally this increase is sufficient to produce visible icterus. Jaundice, when it occurs, usually is of the retention type and is due to two factors. The first of these is depression of the excretory function of the liver due to the anoxemia resulting from venous congestion. The second is increased production of bilirubin as evidenced by its increased concentration in the blood and its increased excretion as urobilin in the stools and urine.¹

Case I. The patient before you, a white male, fifty-four years of age, was informed five years ago that his blood pressure was elevated. Dyspnea and palpitation on exertion and edema of the ankles were first noted one year later. Since then he has had several

attacks of congestive failure. Two weeks ago, he developed a cough which was followed shortly by a conspicuous increase in his previous symptoms. For the past week he has had moderate jaundice.

On physical examination there is orthopnea and slight cyanosis. Other significant findings, in addition to the icterus, include fullness of the peripheral veins, signs of congestion at the bases of both lungs, enlargement of the heart with a soft systolic murmur at the apex, and auricular fibrillation. The blood pressure is 200 mm. of mercury, systolic and 120 mm. of mercury, diastolic. The liver is tender, and its edge is felt 6 cm. below the costal margin. There is edema over the legs and sacrum. The urine contains no bilirubin, and the jaundice, therefore, is of the retention type.

The following diagnoses have been made: Essential hypertension, hypertensive heart disease, hypertrophy and dilatation of the heart, congestive myocardial failure, and auricular fibrillation.

It will be noted that in this subject the jaundice is uniform in distribution. This, however, is not always the case, for Meakins³ observed a number of patients with severe myocardial failure and advanced dependent anasarca in whom jaundice was present only in the upper part of the body while the fluids of edema and ascites rarely contained bilirubin.

The enlargement of the liver in this patient is due, of course, to passive congestion. Gross sections of such livers usually present the so-called "nutmeg" appearance, and microscopic examination reveals atrophy of the central cells of each lobule.¹

Passive congestion of the liver due to causes other than myocardial failure may also result in the appearance of icterus of the retention type. Extensive pericardial effusion, for example, is accompanied by increased peripheral venous pressure, congestion of the viscera, and occasionally by jaundice.

Jaundice in Congestive Myocardial Failure With Tricuspid Regurgitation. When myocardial failure is accompanied by functional or organic insufficiency of the tricuspid valve, jaundice is almost always present. The retention of bile pigment in this condition owes its origin to precisely the same factors as in nonvalvular heart disease with congestive failure.

Case II. This patient is a schoolboy, seventeen years of age. Evidence of heart disease was first discovered three years ago during a routine physical examination. Six months later he developed symptoms and signs of myocardial failure and was kept in bed for several weeks. He has taken digitalis daily since that time

and has been practically free of symptoms. Three weeks ago he noted increasing dyspnea and palpitation, followed shortly by swelling of the legs and abdomen.

The patient, as you see, has severe orthopnea. The skin and sclerae are deeply jaundiced. The cheeks are flushed, and there is moderate cyanosis of the lips, ears and tips of the fingers. The veins of the neck are distended and pulsating forcibly. There is bulging of the thoracic wall in the precordial region. The heart is greatly enlarged, and systolic and diastolic murmurs are present at the apex and in the right second intercostal space. A loud, harsh systolic murmur is heard in the fourth and fifth interspaces just to the left of the sternum. Auricular fibrillation is present with an apex rate of 120 beats per minute and a moderate radial pulse deficit. The arterial blood pressure is 190 mm. of mercury, systolic and 30 mm. of mercury, diastolic. Capillary pulsation is present, and a "pistol shot" sound is heard over the femoral artery. Signs of pulmonary congestion are present over the back, and there is evidence of free fluid in the right pleural cavity. The liver extends 8 cm. below the costal margin and shows forcible pulsations on bimanual palpation. There is considerable ascites and moderate edema of the legs, thighs, and lower back. The urine contains no bilirubin, and the jaundice, therefore, is of the retention type.

The following diagnoses have been made: Rheumatic heart disease, hypertrophy and dilatation of the heart, congestive myocardial failure, mitral stenosis and regurgitation, aortic regurgitation, tricuspid insufficiency, and auricular fibrillation. The presence of tricuspid insufficiency is indicated principally by the distended, pulsating jugular veins, the expansile pulsations of the liver, and the harsh systolic murmur over the tricuspid area.

Jaundice in Congestive Myocardial Failure With Acute Necrosis of the Liver. In patients with jaundice due to congestive myocardial failure, icterus usually is of the retention type and microscopic examination of the liver reveals only atrophy of the central portions of the lobules. In severe and protracted cardiac failure, however, actual necrosis of the liver cells may be present.¹ Usually only the central cells are thus affected, although occasionally, as in the case to be considered next, the changes are very widespread and the liver presents the pathologic picture of acute necrosis (acute yellow atrophy, acute toxic hepatitis). When the necrosis of the liver cells becomes sufficiently extensive, bile canaliculi are ruptured and permit leakage of bile into the blood stream. The jaundice, therefore, changes from the retention type to the regurgitation type.

Case III. The case I wish to review is that of a woman, forty-one years of age, who had had rheumatic fever at the age of twelve years. She was admitted to this hospital in January, 1929, with symptoms of moderately severe congestive failure, six weeks in duration. There had been one earlier attack of cardiac failure, five years previously, and since that time she had had dyspnea on exertion. On admission to the hospital there was slight jaundice of the skin and sclerae. This gradually disappeared during her stay in the hospital. The liver was enlarged and could still be felt at the time of discharge, six weeks later. The urine contained no bile. On April 20, 1929, the patient was readmitted to the hospital because of increasing dyspnea, cough, palpitation, and swelling of the ankles, one week in duration. Jaundice and pain in the right upper quadrant of the abdomen had been present for three days, and for two days there had been repeated vomiting. The skin, sclerae, and mucous membranes were deep yellow in color, and there was moderate cyanosis. The heart was enlarged and presented the signs of mitral stenosis and auricular fibrillation. The percussion note was dull, and numerous medium râles were heard over the bases of both lungs. The liver was tender and extended a hand's breadth below the costal margin. There was slight edema over the legs and sacrum. The urine contained a large amount of bilirubin; the blood gave the direct van den Bergh reaction, and the stools were grayish white in color.

The patient was fairly comfortable during the first ten days in the hospital although the jaundice did not diminish. Repeated vomiting then returned, and she rapidly became drowsy and confused. The jaundice increased in intensity, while the liver began to decrease appreciably in size. During the following three days, the patient's condition became progressively worse; the temperature rose to 103 F., and death occurred on the fourteenth day after admission.

Necropsy revealed chronic mitral endocarditis with mitral stenosis, chronic passive congestion of the viscera, early bronchopneumonia, and acute necrosis of the liver. The liver weighed 1560 Gm., was very soft, flabby, and dark purplish red in color. On cut surface, practically none of the normal markings could be distinguished. Microscopic sections showed almost complete disappearance of normal liver cells (Fig. 165). The general appearance was that of a sponge consisting of the original stroma, now filled with blood, with scattered liver cells occurring singly or in small groups in all stages of necrosis. There was no proliferation of the bile ducts and only slight evidence of regeneration of the hepatic cells.

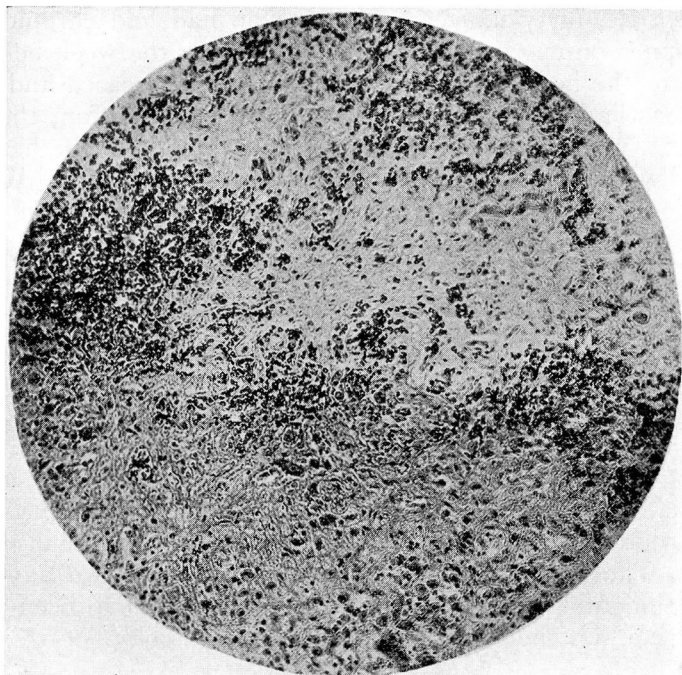


Fig. 165.—Photomicrograph showing widespread necrosis of the hepatic epithelial cells in Case III

In severe and prolonged passive congestion the liver may become abnormally susceptible to the effects of toxic agents. Although no definite statement can be made, it is possible that the terminal bronchopneumonia in this patient contributed to the production of the widespread necrosis of the hepatic epithelial cells.

You will note that at the time of the patient's first admission to the hospital, the jaundice was of the retention type, while during the second admission, it had the characteristics of the regurgitation type and reflected the more extensive liver damage then present.

Jaundice in Congestive Failure With Pulmonary Infarction. The rapid development or intensification of jaundice in congestive failure usually is due to pulmonary infarction. Infarction of the lung causes a sudden increase in the degree of anoxemia of the liver which, of course, reduces the already impaired excretory function of the hepatic cells. In many instances, the increase in anoxemia causes actual necrosis of the liver cells in the center of the lobules; and if this is sufficiently extensive, the jaundice assumes the characteristics of the regurgitation type.¹

Case IV. The patient whose necropsy specimens I have here was a white male, forty-six years of age, who had had chronic cough and dyspnea on exertion for ten years. During the week before admission to the hospital, these symptoms had increased and edema of the legs had been present. On physical examination, there was orthopnea, moderate cyanosis, and slight jaundice. The heart was enlarged with systolic and diastolic murmurs at the apex. Auricular fibrillation was present. There were signs of congestion at the bases of both lungs and of consolidation in the left midchest posteriorly. The liver extended almost to the level of the umbilicus, and there was edema of the legs and over the lower back.

During the first two days in the hospital, the jaundice increased greatly. Then for twelve days it gradually diminished as the patient's general condition improved. On the fourteenth day, however, there was an abrupt increase in dyspnea and cyanosis, and on the following day the jaundice was noted to be much more intense. There had been no cough, pain in the chest, or hemoptysis, and examination of the chest revealed no significant changes in physical findings. The patient became comatose and died two days later. During the entire period of observation, bilirubin had been present in the urine, but the stools had been of normal color.

Necropsy confirmed the diagnosis of rheumatic heart disease with mitral stenosis. The liver was enlarged and congested and showed necrosis of the central cells of the lobules in microscopic sections (Fig. 166). The major portion of the cavity of the left auricle was occupied by a large, grayish-red, friable thrombus, and the lumen of the right inferior pulmonary vein was occluded by an attached thrombus which extended peripherally for a considerable distance along its tributaries. The lower lobe of the right lung was completely infarcted; it was deep red in color and of a firm, rubbery consistency throughout. Scattered through the remainder of the lungs were many areas of thrombotic infarction, ranging from a few millimeters to 5 or more centimeters in the greatest diameter. There were no areas of pneumonia.

Both the rapid increase in jaundice soon after the patient's admission to the hospital and the sudden intensification of icterus a few days before death presumably were due to pulmonary infarction. It is to be noted that during the entire period of observation the icterus was of the regurgitation type and indicated the presence of central necrosis of the liver.

Although severe anoxemia of the liver cells is the principal cause of the sudden appearance of intensification of jaundice in

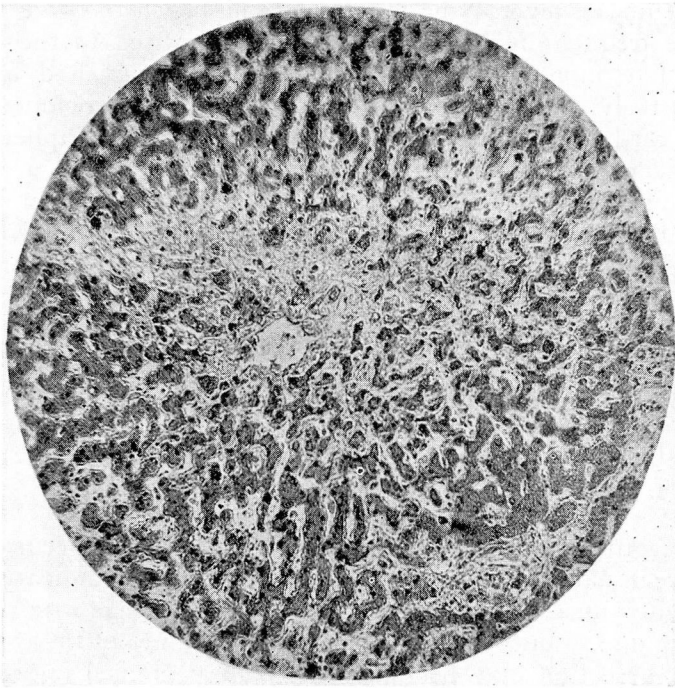


Fig. 166.— Photomicrograph showing necrosis of the central hepatic epithelial cells in Case IV

myocardial failure with pulmonary infarction, it is to be remembered that hemorrhagic infarcts are sources of bilirubin. The extensive infarction in the present case must have added appreciably to the total amount of circulating bilirubin and thus increased the degree of jaundice.

Jaundice in Subacute Bacterial Endocarditis. Prolonged febrile illnesses accompanied by the development of severe anemia cause atrophy of the central hepatic cells and depress the excretory function of the liver. At the same time, the increased destruction of red blood cells causes a considerable increase in bilirubin production. Jaundice of the retention type may result from the combination of these two factors.¹

In subacute bacterial endocarditis, the skin often has a diffuse yellowish-brown color to which the term “café au lait” is applied. Occasionally, if the disease is accompanied by a sufficiently severe anemia, the skin and sclerae become definitely icteric. This has occurred in the last patient to be presented.

Case V. Fifteen years ago, at the age of seventeen years, this man had rheumatic fever. Nine months ago he began to tire easily and to have frequent night sweats. He was admitted to the hospital nearly five months ago because these symptoms had increased progressively. The important physical findings included slight pallor, cardiac enlargement with the cardiac and peripheral signs of aortic regurgitation, petechiae in the conjunctivae, a palpable spleen, microscopic hematuria, moderate leukocytosis, and irregular fever. During the time in the hospital his condition has become progressively worse, with great loss of weight, repeated chills, and numerous showers of petechiae. On two occasions he has complained of severe pain in the left upper quadrant of the abdomen. Repeated blood cultures have yielded growths of *Staphylococcus aureus*. The red blood cell count has decreased to 1.8 millions per cubic millimeter. The skin now has a definite yellow color, and the sclerae show slight icterus. The urine contains no bilirubin, and the jaundice, therefore, is of the retention type.

Recognition of the factors responsible for the occurrence of jaundice in patients with heart disease is of value in indicating what therapeutic measures are to be employed. In subjects with retention jaundice due to uncomplicated myocardial failure of the congestive type, venesection may be followed by great clinical improvement and subsidence of the icterus. The diminution in jaundice under these circumstances is due to decreased passive congestion of the liver and consequent alleviation of the anoxemia of the hepatic epithelial cells. Jaundice probably would occur less frequently in congestive failure if venesection were done routinely in all subjects in whom the venous pressure is higher than 20 cm. of water and the red blood cell count is within the limits of normal. Icterus due to pulmonary infarction complicating congestive failure indicates the presence of severe anoxemia. The administration of oxygen frequently is of considerable benefit in this condition. Jaundice occurring with extensive pericardial effusion indicates the necessity for aspiration of the pericardial fluid. Removal of the fluid results in a decrease in venous pressure and therefore relieves the anoxemia of the liver. In addition to these measures, all patients with congestive heart failure should, of course, be treated by rest in bed, complete digitalization, limitation of fluid intake and, if necessary, administration of diuretic drugs. Icterus in patients with subacute bacterial endocarditis may diminish following transfusion and other therapeutic measures directed toward alleviation of the anemia.

The cases that have been presented illustrate the multiplicity of mechanisms that may result in the appearance of jaundice in

JAUNDICE IN HEART DISEASE

patients with heart disease. I believe it will be apparent to you that the recognition of the form of jaundice in each instance is of considerable importance not only in estimating the type and degree of pathologic change in the liver but also in determining the diagnosis, the prognosis, and the proper treatment.

REFERENCES

- 1 Rich, A. R.: The Pathogenesis of the Forms of Jaundice, Bull. Johns Hopkins Hosp., 47:338, 1930.
- 2 Fishberg, A. M.: Jaundice in Myocardial Insufficiency, Jour. Amer. Med. Assoc., 80:1519, 1923.
- 3 Meakins, J.: Distribution of Jaundice in Circulatory Failure, Jour. Clin. Invest., 4:135, 1927.