

# CHEMICAL PNEUMONIA IN WORKERS EXTRACTING BERYLLIUM OXIDE

## *Report of Three Cases*

H. S. VanORDSTRAND, M.D., ROBERT HUGHES, M.D.,  
and MORRIS G. CARMODY, M.D., F. A. C. S.\*

In the past 22 months 3 men employed in the extraction of beryllium oxide from the raw ore have been seen at the Cleveland Clinic. They presented symptoms of a chemical pneumonia which we believed to be attributable to their occupation. In each patient the syndrome was characteristic and identical, and in each recovery was complete. One man returned to the same occupation, developed a recurrence of his initial pneumonia, and is again making a satisfactory recovery.

We believe that the chemical pneumonia is due to the inhalation of irritants in the process of the extraction of beryllium oxide. The specific etiologic agent is unknown. It may not be beryllium per se but chemical compounds formed outside or inside the respiratory tract during the processing of the ore.

Beryllium belongs to the same chemical group as magnesium and calcium. It is usually found as beryl, a double silicate of beryllium and aluminum. It is used as an alloy to harden and strengthen other metals; it prevents corrosion, augments the electric conductivity of copper, and is easily permeable to x-rays as is shown in figure 1.

In the American literature we have been unable to find a reference to the toxicity of beryllium or its compounds. In the foreign literature Caccuri<sup>1</sup> reported experimentally produced hepatic and renal changes in beryllium poisoning. He studied the effects of beryllium carbonate, nitrate, and oxide on the liver and kidney in rabbits and found that the nitrate causes the greatest damage. Volter<sup>2</sup> reported the experimental toxicity of beryllium fluoride and chloride and found the former to be more toxic. These compounds were found to precipitate proteins in vitro, inhibit the life process of infusoria, and denature cell protoplasm. Volter reported that beryllium fluoride can paralyze the central nervous system in the higher forms of life with death resulting from paralysis of the respiratory center.

\*Former Chief Resident Surgeon Cleveland Clinic Foundation.

## CHEMICAL PNEUMONIA

An article in *Occupation and Health*<sup>3</sup> describes one method used in the preparation of beryllium. This method involves four processes.

1. Beryl and sodium fluorosilicate are pulverized together liberating large amounts of dust.
2. The mixture is fused in kilns. Some gases are given off, e.g.,  $\text{SiF}_4$ .

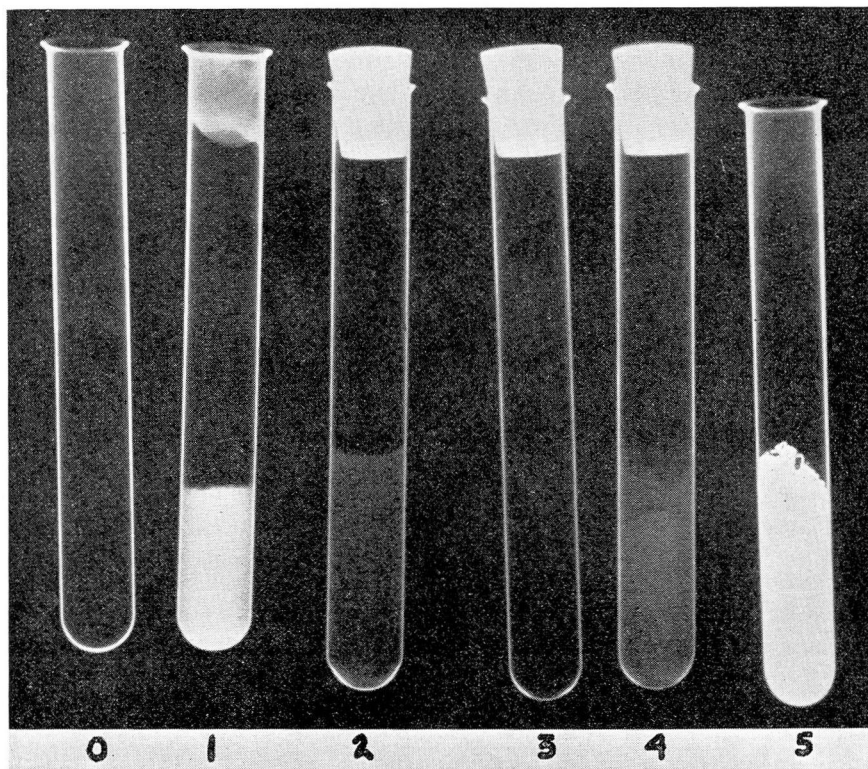


FIGURE 1. This figure illustrates the relative radiotranslucency and radio-opacity of (0) air; (1)  $\text{BaSO}_4$  %10; (2)  $\text{BeSO}_4$  %10; (3)  $\text{BeO}$  crystals; (4)  $\text{BeSO}_4$  crystals; (5)  $\text{BaSO}_4$  crystals. It is evident that  $\text{BeO}$  crystals (3) are essentially radiotranslucent.

3. The resulting mass is again pulverized and treated with hydrofluoric acid to dissolve out beryllium as beryllium oxyfluoride. Dust of silicates, fumes of the oxyfluoride, and vapors of hydrofluoric acid may be evolved during this stage.

4. Beryllium oxyfluoride is heated in a crucible or treated elec-

trollytically to recover pure beryllium. Gases and smokes given off resemble those mentioned in the third stage.

This article states that the precise nature of the beryllium compounds given off in smoke and dust is not known. The presence of hydrofluoric acid and silicon fluoride in the air must be kept in mind. Other fluorides also may be present.

The foregoing report mentions the pathology occurring in the skin and mucous membranes. Particular attention is called to "a metal fume fever," i.e., paroxysmal cough with a small amount of expectoration, increased dyspnea, cyanosis, and slight fever usually with complete recovery. During the disease process the clinical findings were cyanosis, dyspnea, reduction of chest expansion, and numerous moist râles without definite localization. The syndrome continued for 3 or 4 weeks with alternating remissions and exacerbations. X-rays of the chest had a "reticulated" appearance with small nodules resembling those seen in miliary tuberculosis. The condition was described as a bronchiol-alveolitis or peribronchiolalveolitis.

Gelman<sup>4</sup> in Moscow reported a number of cases with this clinical picture. He believed that the disease in their beryllium "foundry" was due to the action of fluorine which he thought was separated from beryllium oxyfluoride at the level of the bronchioles and alveoli. It was his impression that it takes time for enough fluorine to accumulate to cause symptoms, and that it continues to separate as long as any beryllium oxyfluoride is present which accounts for the prolongation of symptoms. The fumes are said to be able to travel in air in toxic concentrations for 100 yards or more.

The chemical procedure or formula used for the preparation of beryllium oxide at the plant at which our patients worked has not been released by the company. According to the chemists, however, no fluorides are used. Despite this difference in preparation of beryllium the symptoms and physical findings of our patients closely resembled those that have been reported to occur when fluorides were used in the preparation of beryllium.

The symptoms of the three patients reported here were identical. Each man began to note the insidious onset of his disease by a gradual decrease in his vital capacity. Soon thereafter a dry cough was noted which was never very productive. In all instances the expectoration of mucoid or frothy sputum was slight and occasionally blood tinged. The most disturbing symptom was the progressive dyspnea with the

## CHEMICAL PNEUMONIA

ensuing severe apprehension. In each patient the disease ran a low grade febrile course in which the temperature never rose above 100 F.

The physical findings were also identical: low grade fever, shallow rapid respirations, mild to moderate cyanosis with fine crepitant râles throughout the lower half of both lungs.

Two of the patients had bronchoscopic examinations: one revealed a hyperemic tracheobronchial mucosa; and the other showed additional evidence of chronic irritation with the presence of a patchy exudate throughout the visualized tracheobronchial tree. The aspirated secretions and expectorated specimens, or both, were negative for all pathogens in all cases. There was no deviation from the normal in the white blood count or in other laboratory tests.

The onset of symptoms preceded the roentgen changes by at least 3 weeks. The appearance of the chest films then varied with the stage and severity of the disease. The x-ray findings in order of progress were: (1) diffuse haziness of both lungs; (2) subsequent development of soft irregular areas of infiltration with prominence of the peribronchial markings; (3) absorption of soft exudative infiltration and the appearance of discrete small nodules scattered throughout both lungs; (4) clearing of lung fields.

The roentgen changes were bilateral and diffuse in all cases and followed the same general pattern. The exudative and nodular infiltration regressed within one to 2 months after which the chest appeared entirely normal. Identical roentgen changes were found by one of us (R.H.) on reviewing the chest films of 6 additional patients. These patients were from the same beryllium plant and had symptoms similar to those in the 3 cases reported in this paper.

The term tentatively used in the diagnosis is chemical pneumonia, although a more accurate one might be chemical pneumonitis or chemical bronchiolitis. As mentioned previously, the condition has been described in the foreign literature as a bronchiolalveolitis or paribronchiolalveolitis.

The average loss of time from work in the 3 cases was  $3\frac{3}{4}$  months.

### CASE REPORTS

**Case 1.** A man 28 years of age came to the Clinic on February 11, 1941 complaining of shortness of breath with a slightly productive cough of one month's duration. He stated that the expectoration had been slightly blood streaked on several occasions. He had lost 11 pounds in weight.

H. S. VANORDSTRAND, ROBERT HUGHES AND MORRIS G. CARMODY

There was a moderate elevation of temperature, 99.6 F., and abnormal physical findings in the chest. There were decreased respiratory excursions with a respiratory rate of 30, and numerous scattered fine crepitant râles were heard throughout both lungs. The mucous membranes were slightly cyanotic.

X-ray examination of the chest showed a diffuse haziness of both lungs, prominence of the peribronchial markings, and irregular areas of soft nodular infiltration.

Bronchoscopy revealed patchy areas of whitish adherent exudate on the visualized tracheobronchial mucous membrane. There were no ulcerations, tumefactions, nor changes in the size of the lumen of the bronchial tree. There was a minimal amount of secretion which upon aspiration was found to be negative in all respects on smear and culture.

Expectorated mucoid specimens were negative for all pathogens; the blood counts were normal; and all the other routine laboratory studies revealed normal values.

On a program of rest the patient's symptoms entirely subsided in 3 weeks, and an x-ray examination of the chest on March 11, 1941 showed a complete return to normal.

The roentgen films in this case have not been released by the State Industrial Commission.

**Case 2.** A man 55 years of age was seen on May 3, 1942 with symptoms of shortness of breath and a slightly productive cough of 5 weeks' duration. As in the preceding case the positive physical findings were a low grade fever, the temperature being 99.8 F., mild cyanosis, shallow rapid respiration, and fine crepitant râles scattered throughout the lungs being most pronounced in the lower two-thirds.

Stereoroentgenograms showed essentially the same findings as in the previous case.

A bronchoscopic examination showed a mild generalized hyperemia of the tracheobronchial mucosa without other pathology. A minimal amount of rather frothy secretion was aspirated and was negative on smear and culture.

Expectorated mucoid secretions were negative bacteriologically. The blood counts and all other laboratory tests were normal.

This patient was advised to rest for 3 months and then return for a recheck examination. When seen again on August 26, 1942 he stated that he had been completely symptom free for over one month. A progress x-ray examination of his chest was found to be entirely normal. The patient was advised to return to some simple form of work other than at the plant in which he had contracted the chemical pneumonia. On November 12 this patient returned and related that he had experienced a recurrence of his previous symptoms in the past 3 weeks. Contrary to our advice he had returned to work at the beryllium plant on September 16. The physical findings were identical to those of his initial examination, and x-ray examination of his chest showed a recurrence of the chemical pneumonia. He was hospitalized in his own town, and after a rather stormy course he is now convalescing satisfactorily.

This case illustrates the recurrence of identical symptoms in a patient following reexposure in his occupation. As in the first case the roentgen films have not been released by the State Industrial Commission.

**Case 3.** A boy aged 17 entered our hospital on August 27, 1942 with the symptoms of marked dyspnea and a slightly productive cough with occasionally blood-tinged expectoration of 3 weeks' duration. The patient informed us that he had been

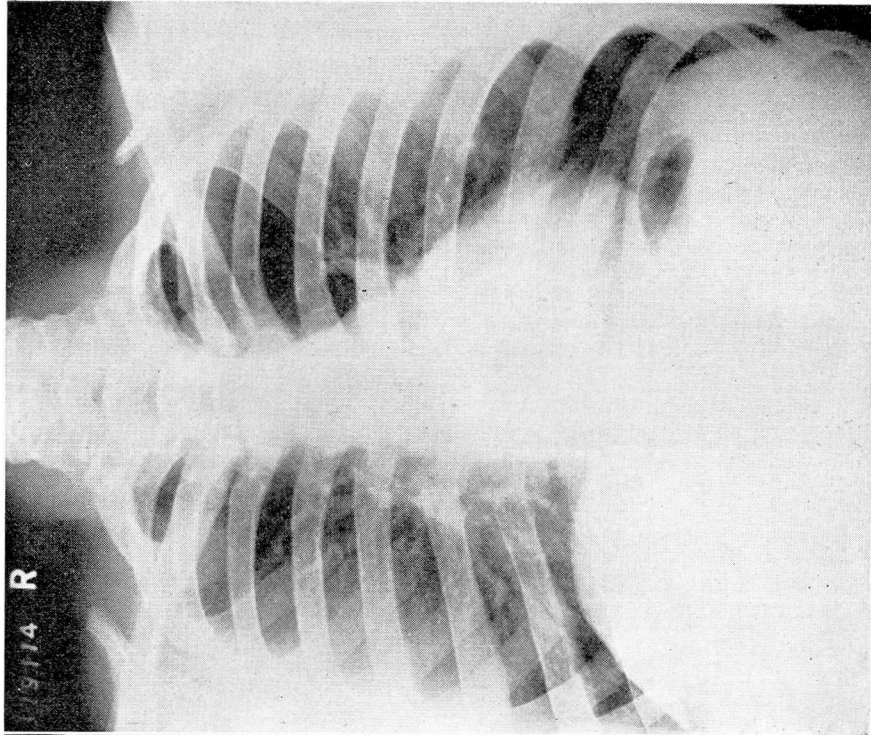


FIGURE 3. This chest film was made 6 weeks after the film in figure 2. At this time both lungs appear entirely normal.

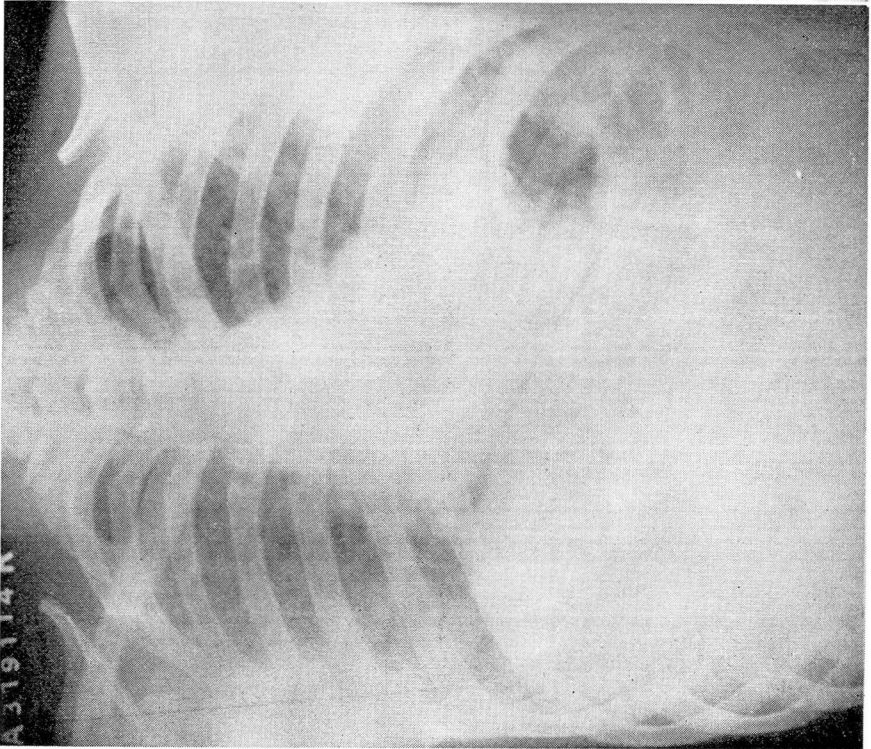


FIGURE 2. This chest represents the changes at the height of the disease. The roentgen film shows a diffuse soft patchy infiltration in both lungs with prominence of the peribronchial markings and a little elevation of both diaphragms.

H. S. VANORDSTRAND, ROBERT HUGHES AND MORRIS G. CARMODY

employed at the chemical plant for 3 months and was classified as a general helper, "doing everything around the plant."

The initial examination revealed considerable cyanosis, a temperature of 99.8 F., and extreme dyspnea. Bronchovesicular breath sounds were present over the lower two-thirds of the chest both anteriorly and posteriorly with a roughening and prolongation of the expiratory phase as compared with the inspiratory; the total excretory excursion was very shallow with a rate of 48.

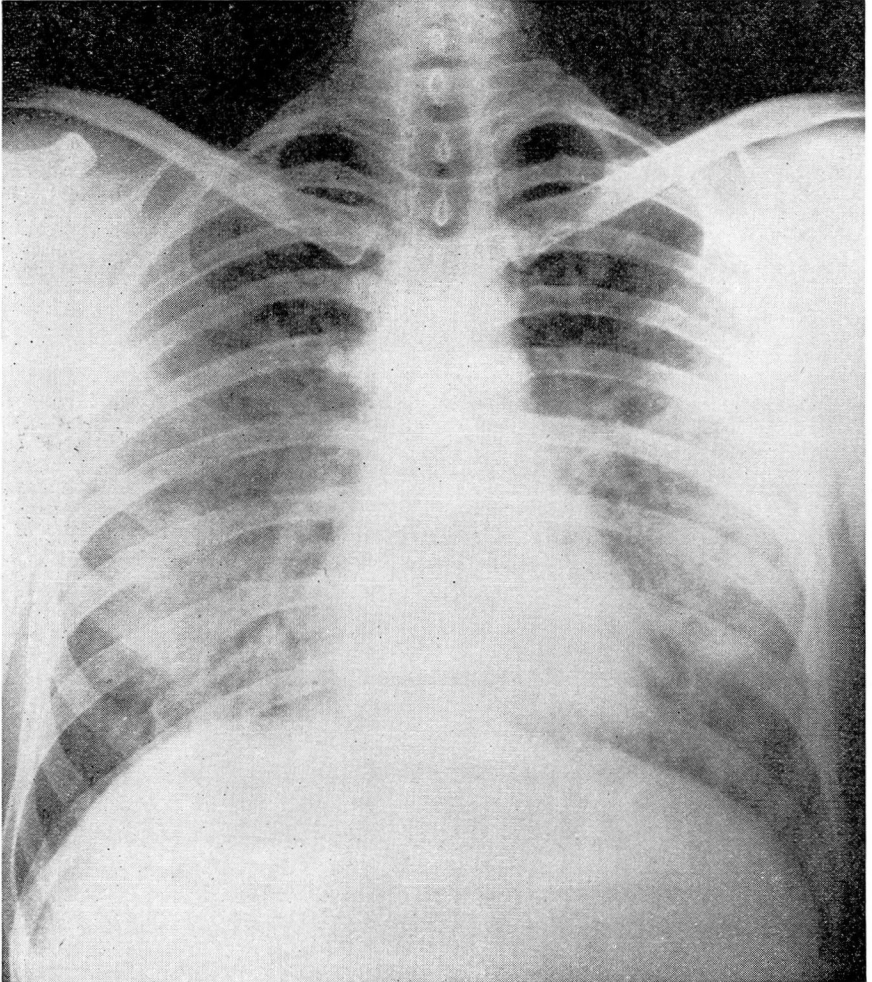


FIGURE 4. This chest film illustrates a chemical pneumonia which developed in a patient working in a rayon factory. There is a diffuse bilateral soft infiltration present. This appears in irregular conglomerate patches and resembles the changes occurring in the 3 patients working in the beryllium plant.

## CHEMICAL PNEUMONIA

Stereoeroentgenograms of the chest again demonstrated the diffuse haziness, soft patchy infiltration, and the prominence of the peribronchial markings. (Fig. 2) In this case there was also some elevation of both diaphragms.

The patient was hospitalized for 22 days and was confined within an oxygen tent for the greater part of the first 12 days. His temperature ranged between 99.4 F. and 100 F., but returned to normal the last 5 days of his stay. Roentgenograms made at 5 to 7 day intervals initially showed a progression of the pulmonary pathology and then a gradual recession. Later films assumed more of a mottled, nodular character in contrast to the initial diffuse haziness.

The patient was discharged to his home on a continued rest regimen. Six weeks<sup>s</sup> later he reported that he had been completely symptom free for the previous 2 weeks. The last x-ray examination made on this patient reveals a complete return to normal as is shown in figure 3.

This patient suffered a more severe disability than the other 2 patients. It is interesting to note that as a general helper he never spent any appreciable time at any one phase of the extraction of beryllium oxide. We had the opportunity to review chest films made at 1 to 2 week intervals after the onset of his symptoms. No change was evident for the first month after which x-rays showed a characteristic progression of the disease and finally clearing of the lungs.

Symptoms and roentgen changes identical to those described in the 3 foregoing cases were found in a 28 year old man who was employed in "the mixing room" of a rayon factory. He informed us that he had worked there for over 5 years, and that 8 other men in the same department had recently become ill and apparently were convalescing satisfactorily away from work. Our diagnosis in this case was chemical pneumonia of undetermined etiology. (Fig. 4)

This case has been mentioned as a chemical pneumonia with symptomatology and roentgen findings identical to those of the 3 cases reported in the beryllium industry, although apparently without exposure to a beryllium compound. This would suggest that beryllium itself is not the etiologic factor.

In our own research department and in the plant manufacturing beryllium oxide, studies are being carried out with the hope of determining the exact etiologic agent for the chemical pneumonia as illustrated in these 3 patients. Experimental animals have been placed in various places in the plant to study the effects of exposure. We hope to be able to add further information in a subsequent report.

### SUMMARY

Three cases of chemical pneumonia occurring in a war industry manufacturing beryllium oxide are presented. The chemical formula or agents used in this process have not been made known by the manufacturer.



The 3 cases reported had identical symptoms and roentgen findings. The characteristic symptoms consisted of dyspnea, a relatively non-productive cough with occasionally blood-tinged expectoration, and a low grade fever. The roentgen changes in the chest which appeared about 3 weeks after the onset of symptoms revealed a diffuse haziness of both lungs, prominence of the peribronchial markings, soft irregular areas of infiltration, and discrete small nodules. These changes were dependent on the stage of the disease. The 3 patients recovered with a complete return of the lungs to normal on chest x-ray.

Additional studies are being made to determine the specific inhaled etiologic agent in this industrial disease attendant to the war effort. The loss of time from work in these 3 cases averaged  $3\frac{3}{4}$  months.

*We wish to acknowledge our appreciation to Dr. John M. McDonald, Director of the Bureau of Occupational Diseases, Baltimore City Health Department, Baltimore, Md. for his interest and cooperation in independently reviewing the foreign literature bearing on occupational diseases in the beryllium industry.*

#### BIBLIOGRAPHY

1. Caccuri, S.: Changes of liver and kidneys in beryllium intoxication; experimental study of industrial toxic hepatonephritis. *Rass. Med. Ind.* 11:307-314, 1940.
2. Volter, S. V.: Toxicity of beryllium. *Farmakol. i. Toksikol.* 3:82-5, 1940.
3. Gelman, J. G.; Beryllium. *Occupation & Health Supplement*, International Labor Office, Geneva, January, 1938.
4. Gelman, I.: Poisoning by vapors of beryllium oxyfluoride. *J. of Ind. Hyg. & Toxicology.* 18:371-379 (September) 1936.