

HEMOPTYSIS AND HEMATURIA IN SPRUE

Importance of Vitamin K Metabolism

Report of a Case

E. N. COLLINS, M.D. and A. D. HOFFMANN, M.D.

Sprue (idiopathic steatorrhea, celiac disease, Gee-Herter disease) is not commonly encountered in nontropical regions. Sprue is considered a chronic deficiency state related to pernicious anemia and to deficient absorption of the erythrocyte-maturing factor, as well as to deficient absorption of fat-soluble substances. Hemoptysis and hematuria are rare complications. The case to be reported not only illustrates the lack of *absorption* of fat-soluble substances, including fat-soluble vitamins, particularly vitamin K, but also may illustrate deficient *synthesis* of vitamin K as a result of the use of succinylsulfathiazole,* which changes the bacterial flora in the intestinal tract.

In this instance the diagnosis of sprue was not established until the second period of observation. Until then the patient had been treated for indeterminate diarrhea. Three years previously an attack of prolonged diarrhea had promptly subsided upon sulfathiazole therapy, which suggested that bacillary dysentery might have been present. Nine days following our initial observation, the patient was readmitted to the hospital as an emergency case with hemoptysis and hematuria.

CASE REPORT

A married white man, aged 31, a storekeeper by occupation, was referred by Dr. J. T. Ledman of Lakewood, Ohio to Dr. J. W. Thomas for allergic investigation. The patient complained of lower abdominal cramplike pain, persistent diarrhea, weakness, and loss in weight.

During the previous 4 months he had had as many as 9 stools daily without observing blood. He had lost 20 pounds in weight. A similar condition 3 years previously had lasted 8 months. Sulfathiazole had been given for 2 weeks and had been followed by a remission of symptoms until the onset of the present attack. The patient had never been in the tropics or Southern states. Dr. Ledman stated that during the present illness stool examination and roentgen examination of the colon had revealed no evidence of an *inflammatory process*, and there had been no response to the use of sulfathiazole. Even though the patient had never had hay fever, asthma, or other manifestations of allergy, a possible gastrointestinal allergy was suspected.

Physical examination revealed a poorly nourished man 68.5 inches in height and weighing 121.5 pounds. The temperature and pulse rate were normal. The blood pressure was 94 systolic and 68 diastolic in mm. of mercury. The tongue was smooth, but the

* 2-(N⁴-succinylsulfanilamido)-thiazole—sulfasuxadine, Sharp & Dohme.

patient's wife volunteered the information that it had been "beefy red" prior to admission. There was a slight tenderness in both lower abdominal quadrants.

As the initial stool examination revealed the presence of fatty acid crystals, the diagnosis of sprue was immediately considered. However, no fatty acid crystals were found on subsequent daily stool examinations over a period of 12 days. No evidence of parasites was found. Cultures of stools for dysentery bacilli were negative, but the Gregerson modification of the benzidine test for occult blood was positive in all the stools examined. The diet contained meat but was low in fat.

Proctosigmoidoscopic examination revealed normal findings. Roentgen examinations of the chest, stomach, duodenum, and colon also revealed normal findings. However, the interval study of the small intestine disclosed increased caliber of the intestinal loops, clumping of barium, and apparent thickening of the intestinal folds 2 hours after the ingestion of the barium sulfate meal. These findings are characteristic of a deficiency state and not of regional enteritis.

The gastric Ewald test meal examination revealed a free acidity of 30 and a total acidity of 60. The blood count was 4,250,000 red blood cells, with a hemoglobin of 76 per cent, and 3500 white blood cells. The sedimentation rate of the erythrocytes was normal, as were the fasting blood sugar determination, blood Wassermann and Kahn tests, and urinalyses.

Aside from the evidence of the one stool that contained fatty acid crystals, the cause of the diarrhea remained indeterminate. The patient had become symptom free as soon as he had entered the hospital. Throughout the hospitalization period of 12 days he had only one or 2 stools daily. He gained strength, and his weight increased from 121.5 to 126 pounds, even though the residue in the diet had been increased daily.

In view of the patient's response to sulfathiazole therapy 3 years previously, the use of succinylsulfathiazole on an emperic basis was started 6 days prior to his discharge. Two Gm. was given 4 times daily for 3 days, after which 1 Gm. was used 4 times daily during an additional 9 days until a total of 60 Gm. had been taken. While the patient was in the hospital, the fluid intake and output were adequate, the blood sulfathiazole level did not exceed 3.6 mg. per cent, and the urine remained clear.

Second period of observation. Nine days after the patient was discharged from the hospital, Dr. Ledman called by telephone to report that the patient had hemoptysis, massive hematuria, and should be readmitted to the hospital immediately. Upon admission examination of the urine revealed "almost pure blood." The fluid intake and output had been satisfactory, there were no sulfathiazole crystals nor other abnormal findings in the urine, and the blood succinylsulfathiazole level was 2.6 mg. per 100 cc. blood. The use of succinylsulfathiazole had been discontinued 3 days prior to the re-admission to the hospital. Stereoroentgenograms of the urinary tract and chest revealed no abnormal findings. Cystoscopic examination and bilateral pyelograms were made by Dr. Charles Higgins and were reported as being normal. The ureteral catheters were left in place for drainage, and blood was observed coming from both kidneys. No tubercle bacilli were isolated from either kidney specimen, and the cultures were negative.

Meanwhile, the prothrombin time of the blood was found to be elevated to 41 seconds using Quick's method (normal 15 seconds).

An injection of 2-methyl-1, 4 naphthaquinone* was given, and transfusion of 500 cc. blood was administered by the slow drip citrate method. Prior to transfusion the red blood cell count was 3,620,000; hematocrit reading 87 per cent of normal (39 cc. per 100 cc. of blood); hemoglobin 75 per cent (11.5 Gm.); volume index 1.21; and color index 1.04. The mean cell diameter was 8.1 microns. The icterus index was 3 units. The

SRUE

white blood cell count was 3500. Examination of the blood smear revealed a marked macrocytosis, occasional nucleated red cells, 56 per cent neutrophils, 43 per cent lymphocytes, 2 per cent eosinophils, 2 per cent monocytes, and no abnormal white blood cells. The previous finding of free hydrochloric acid in the stomach contents excluded true pernicious anemia.

The blood calcium was reduced to 8.3 and the total blood proteins to 4.9 mg. per cent. The plasma proteins were fractionated by the Tiselius method. Results are summarized in chart 1. The blood urea, carbon dioxide combining power, and cevitamic acid determinations revealed normal findings. All stools were loaded with fatty acid crystals throughout the second hospital observation. Benzidine tests were negative on several of the stools; all the dietary factors remained the same as during the first observation. Therefore, a diagnosis of sprue complicated by a hemorrhagic diathesis was made.

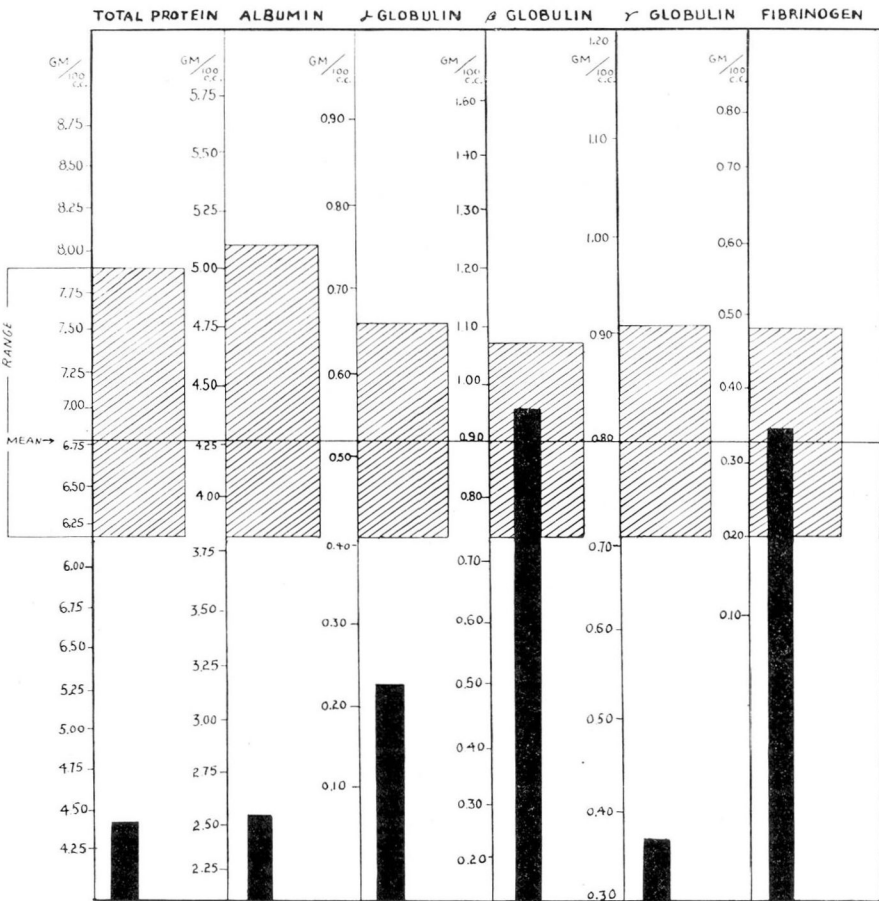


CHART 1

The bromsulfalein and intravenous hippuric acid liver function tests revealed normal findings.

The intravenous use of 2-methyl-1, 4 naphthaquinone* was continued daily for 3 days, after which a similar substance** was given by mouth daily for 26 days. Nine hours after the blood transfusion and first injection of vitamin K substance, less blood appeared in the urine. Three days later the urine was entirely clear, and the prothrombin level of the blood was normal. The hemoptysis had subsided by the time the patient had reached the hospital.

Additional therapeutic measures included the daily intramuscular injection of 3 cc. liver extract (10 units per 3 cc. — Lederle) and 2 cc. vitamin B complex (Beminal Injectable — Ayerst, McKenna) while the patient was in the hospital (16 days). During each of the first 2 days the patient was given 50 cc. of an Amino-Acid Parenteral preparation (Stearns)† in 1000 cc. of 5 per cent glucose solution intravenously, after which a similar type of preparation (Aminoids — Arlington Chemical Co.) was continued orally. Other oral medication included liver extract (Valentine), ketocholanic acids (Ketochol — Searle), a multivitamin preparation (Gelseals Multibebrin — Lilly), and calcium lactate. After the prothrombin time of the blood returned to normal, it remained normal, as did the blood calcium, while the patient was in the hospital. At the end of this time the red blood cell count was 4,110,000; hematocrit reading 89 per cent of normal; hemoglobin 75 per cent; volume index 1.08; color index 0.91; and mean cell diameter of erythrocytes 7.8 microns. After discharge the patient was advised to continue with a high protein, high vitamin, low fat diet; liver intramuscularly twice weekly, and the daily oral use of liver extract, supplemental vitamins, and calcium.

Five months later Dr. Ledman stated that the patient had been working steadily during the previous 4 months. His general health had been good; he had gained 14 pounds in weight and was averaging one formed stool daily. His blood count at that time was 4,300,000 red blood cells with a hemoglobin of 87 per cent, and 5100 white blood cells.

COMMENT

The significant diagnostic features appeared during the second period of observation when the patient was readmitted as an emergency patient with hemoptysis and hematuria, and the diagnosis of sprue was established. The prothrombin time of the blood was elevated to 41 seconds, using Quick's method of determination (normal 15 seconds). The bleeding promptly subsided, and the prothrombin time of the blood returned to normal following a blood transfusion and the intravenous use of 2-methyl-1, 4 naphthaquinone.

Although spontaneous remissions and acute exacerbations occur in sprue, it seems unusual that striking changes should occur within the

*Hykinone (2-methyl-1, 4-naphthohydroquinone-3-sodium-sulfonate, Abbott) A synthetic substance with a vitamin K action in an aqueous, isotonic, injectable solution. One ampule (4 mg.) daily, intravenously.

**Kayquinone (2-methyl-1, 4-naphthoquinone, Abbott) A synthetic substance which has to a high degree the activity of vitamin K extracted from natural sources. One 1 mg. tablet daily.

† Acid hydrolysis of casein fortified with tryptophane.

short period of time between our two periods of observation (9 days). In addition to deficient *absorption* of fat-soluble vitamin K there may have been deficient *synthesis* of this vitamin as a result of the use of succinylsulfathiazole. Our experience confirms that of Poth¹² in that during the use of adequate doses of this drug B. coli counts in cultures of the stools diminish to zero. Quick⁸ states, "Of great interest and importance was the discovery that vitamin K is synthesized by various bacteria." He refers to the extensive work of Almquist⁴ and his co-workers. It was found that B. coli and other common bacteria readily synthesized products which had high vitamin K activity. Uvnäs⁵ points out that a K-avitaminosis is easily produced in chickens and birds but with difficulty in mammals, perhaps owing to the synthesis of vitamin K by intestinal bacteria in mammals.

Basic considerations in sprue relate to a chronic deficiency state, particularly to deficient absorption of fat-soluble substances and the erythrocyte-maturing factor. Hanes⁶ states that "In the sprue patient fats are normally split, since the pancreatic secretion is maintained, but so poorly absorbed that they are excreted in two or three times the normal amount." Haden⁷ emphasizes the close relationship of sprue to pernicious anemia and states that "The bone marrow lacks the erythrocyte-maturing factor, not from a defect in formation as in pernicious anemia, but from a defect in absorption." Quick mentions, "The hypoprothrombinemia in sprue is not surprising; one would expect a hypovitaminosis of all the fat soluble members A, D, K, and possibly E whenever a severe persistent steatorrhea is encountered." Albright and Stewart⁸ have reported intensive studies in a case of chronic regional ileitis with proven severe hypovitaminosis of all fat-soluble vitamins, including K, due to steatorrhea. In recent years increasing attention has been given to the lack of absorption of vitamin K in the absence of jaundice in various intestinal conditions. Important contributions to this subject have been made by Butt, Snell, and Osterberg,⁹ Snell,¹⁰ and Mackie, Eddy, and Mills.¹¹

The difficulties which may be encountered in making a diagnosis of sprue in nontropical regions are emphasized by Ingelfinger.¹² Typically, the patient with sprue has frequent bowel movements consisting of soft, light yellow, frothy and greasy fecal material. Actually none of his 4 reported patients consistently had stools fitting this description, and this experience is illustrated in the present case report. Two of his patients had a hemorrhagic diathesis, and the chief complaint of one patient was hematuria. Obviously, if the diagnosis is not correctly made, the patient may die of internal and external hemorrhages.

Classic features of sprue may be absent or may be obscured by the

secondary nutritional disturbances of the disease. In the early stages of sprue there is a moderate hypochromic anemia; while in the fully developed disease in adults the blood picture very closely resembles that of pernicious anemia. In the present case the blood picture changed from a moderate hypochromic anemia to a macrocytic hyperchromic anemia in a short period of 9 days.

Barker¹⁸ points out that many victims of chronic dysentery may develop a secondary sprue, and this may have occurred in the reported case. Sulfathiazole therapy apparently had induced a remission lasting 3 years.

SUMMARY

A case of sprue complicated by a hemorrhagic diathesis is reported. Although the basic factors in this condition are well known, such as deficient absorption of fat-soluble substances and the erythrocyte-maturing factor, in this case there may have been the additional factor of deficient synthesis of vitamin K. This vitamin is synthesized in the intestinal tract of mammals by the same bacteria that are eliminated by adequate dosage of certain sulfonamides.

The importance of recognizing hypoprothrombinemia in any case of steatorrhea is illustrated. The parenteral use of a vitamin K substance and a blood transfusion resulted in prompt subsidence of the bleeding in this case.

Sprue should be considered in any patient having diarrhea, even in the absence of stools characteristic of this condition during any one period of examination. Secondary nutritional disturbances may obscure the classic features of the disease.

This patient may have developed sprue secondary to bacillary dysentery.

SPRUE

REFERENCES

1. Poth, E. J., Knotts, F. L., Lee, J. T., and Inui, F.: Bacteriostatic properties of sulfanilamide and some of its derivatives: succinyl-sulfathiazole, new chemotherapeutic agent locally active in gastrointestinal tract. *Arch. Surg.* 44:187 (Feb.) 1942.
2. Poth, E. J., and Knotts, F. L.: Clinical use of succinylsulfathiazole. *Arch. Surg.* 44:208 (Feb.) 1942.
3. Quick, A. J.: *The Hemorrhagic Diseases and the Physiology of Hemostasis.* (Springfield: Charles C Thomas, 1942) p. 235.
4. Almquist, H. J., Pentler, C. F., and Mecchi, E.: Synthesis of the antihemorrhagic vitamin by bacteria. *Proc. Soc. Exper. Biol. & Med.* 38:336, 1938.
(Also subsequent publications by Almquist et al.)
5. Uvnäs, Börje: Prothrombin und Vitamin K, eine Uebersicht. *Schweiz Med. Wehnsch.* 72:461 (April 25) 1942.
6. Hanes, Frederic M.: *Sprue.* *Oxford Medicine.* Vol. V Part III p. 631.
7. Haden, Russell L.: *Principles of Hematology.* (Philadelphia: Lea & Febiger, 1939) p. 219.
8. Albright, Fuller, and Steward, John D.: Hypovitaminosis of all fat-soluble vitamins due to steatorrhea. *New England J. Med.* 223:239 (Aug. 15) 1940.
9. Butt, H. R., Snell, A. M., and Osterberg, A. S.: Further observations on the use of vitamin K in the prevention and control of the hemorrhagic diathesis in cases of jaundice. *Proc. Staff Meet., Mayo Clin.* 13:753 (Nov. 30) 1938.
10. Snell, Albert M.: Tropical and nontropical sprue (chronic idiopathic steatorrhea): their probable interrelationship. *Ann. Int. Med.* 12:1632 (April) 1939.
11. Mackie, Thomas T., Eddy, Walter H., and Mills, Moore A.: Vitamin deficiencies in gastrointestinal disease. *Ann. Int. Med.* 14:28 (July) 1940.
12. Ingelfinger, Franz J.: The diagnosis of sprue in nontropical areas. *New England J. Med.* 228:180 (Feb. 11) 1943.
13. Barker, W. Halsey: *Sprue.* *M. Clin. North America* 27:451 (March) 1943.