

PORENCEPHALIC CYST

Report of a Case

ALEXANDER T. BUNTS, M.D.

Porencephaly signifies a defect in brain structure, having the appearance of a cystlike cavity, which may communicate with the ventricular system or which may be separated from it by a thin membrane. Frequently, such defects are unaccompanied by clinical symptoms or signs during life and are usually first identified at autopsy or accidentally at operation. The condition probably arises (1) as a true developmental aplasia or hypoplasia, or (2) as an acquired defect due to trauma, to encephalitis, or to circulatory disturbances, such as thrombosis or embolism, producing ischemic necrosis and resorption of brain tissue. According to Yakovlev and Wadsworth¹ true porencephaly results from arrest of development of the wall of the secondary cerebral vesicle during fetal life, with formation of a virtual cleft in the cerebral mantle. Such clefts are usually bilateral and symmetrical and do not conform to areas of specific vascular supply. On the other hand, the acquired types are usually single and unilateral, with borders usually showing evidence of old necrotic foci, gliosis, connective scar tissue, and meningeal thickening. The cyst is filled with fluid, which is usually colorless, and is covered by a thin layer of pia-arachnoid. The acquired types may occur anywhere in the cerebrum but are most commonly found in the area supplied by the middle cerebral artery.

In porencephalic cysts which communicate with the ventricular system the diagnosis may be made by pneumoencephalography. Non-communicating cysts occasionally may be identified unexpectedly by ventriculography carried out for an entirely different diagnostic purpose. Such a case is the subject of this report.

This case is reported because of (1) the obscure clinical picture leading to an erroneous tentative diagnosis, (2) the presence of papilledema, and (3) the uncertain etiology of the cystic defect.

CASE REPORT

History. A white housewife, aged 50, first came to the Clinic on February 6, 1937. She had been married for thirty-three years and had two living children. There was no history of birth injury, febrile illness, head trauma, coma, convulsions, or paralysis prior to the onset of the present illness. She had mumps, measles, and chickenpox in childhood.

From 1934 to the summer of 1936 the patient experienced recurrent frontal "sick headaches" with nausea or vomiting about twice a week. These symptoms subsided al-

most completely and were succeeded by daily intermittent transient attacks of occipital pain, which radiated to the frontal area. These pains were sudden in onset, occurred usually in the morning, were severe and pounding in character, of short duration, and often caused the patient to scream. Sudden extension of the head usually preceded the onset of pain. During these bouts of pain the gait was somewhat unsteady. A daughter reported that the patient's memory seemed to be poor and that there had been some vague change in her personality. She worried constantly. Her vision became blurred during the month before she came to the Clinic.

Physical Examination. General physical examination revealed no signs of organic disease in the heart, lungs, or abdominal viscera. Blood pressure was 144 systolic and 98 diastolic. Neurologic examination revealed no motor, sensory, nor reflex abnormalities. The patient was rather apprehensive. Her gait was slightly unsteady. Romberg test was negative. Ophthalmoscopic examination showed a low-grade papilledema of less than 1 diopter in each eye. Examination of the visual fields revealed a moderate temporal field loss in the left eye, but no field loss in the right eye.

Blood studies indicated mild secondary anemia. Wassermann reaction was negative. Urinalysis was normal.

Roentgen examination of the skull disclosed erosion of the posterior clinoid processes suggestive of increased intracranial pressure. Films of the chest showed no abnormal changes.

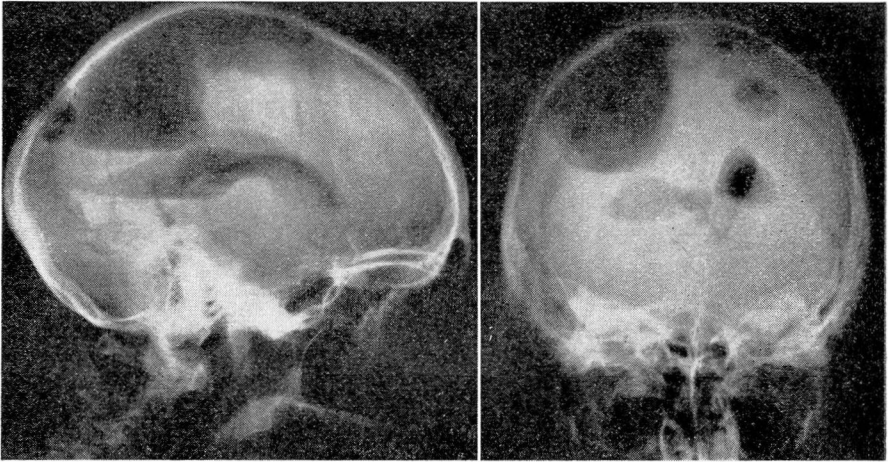
A tentative diagnosis of posterior fossa tumor was made, and a ventriculogram was proposed for the purpose of localizing the intracranial lesion.

Operation. February 12, 1937. With the patient under avertin anesthesia and in the upright position, two holes were drilled through the skull at points symmetrically located 3 cm. to each side of the midline and 6 cm. above the external occipital protuberance. A ventricular cannula was inserted into the posterior horn of the left lateral ventricle, which was encountered at a depth of 5 cm. Clear colorless fluid escaped under moderately increased pressure. A small opening was made in the dura on the right side, and a thin veil-like membrane bulged slightly through the dural opening. The dural opening was enlarged, and the thin bulging membrane was found to lie just beneath the dura. A cannula was inserted through the membrane, and clear colorless fluid escaped in large quantity (not measured) under increased pressure. One cc. of methylene blue dye was injected into the left lateral ventricle. The operator rotated the head for twenty minutes, and the dye failed to appear from the cannula on the right side, indicating absence of communication between the left lateral ventricle and the cavity in the right occipital lobe. Air was injected into the left lateral ventricle, the cannula was withdrawn, and the scalp incision was closed. Through the drill hole on the right side, the cavity was visually explored with the aid of a Cameron light and a ventriculoscope. The cavity appeared to be about the size of a tennis ball and to extend well forward from the occipital pole toward the frontal lobe. The inner surface of the large cavity appeared to be smooth, without convolutional structure, and numerous blood vessels coursed over it. No tumor nodule was found in the wall of the cavity. No choroid plexus was present, and no opening could be seen in the floor of the cavity. Air was injected into the cavity, and the scalp incision was closed. Total protein content of the fluid obtained from the left lateral ventricle was 15 mg. per 100 cc. The fluid from the cyst contained 175 mg. of total protein per 100 cc.

Ventriculograms, made in the usual positions, showed a large cystic cavity which occupied the greater part of the right occipital lobe and extended forward into the parietal lobe (fig. 1). The right lateral ventricle was depressed by the overlying cyst and dislocated toward the left side. The left lateral ventricle was moderately dilated, normal in

contour, and displaced slightly to the left. The right occipital cyst appeared to be separated from the roof of the right lateral ventricle only by a thin membrane.

After ventriculographic studies and evacuation of the cyst, further operation was not considered necessary. The patient was asked to return for observation, because the development of increased intracranial pressure might necessitate the establishment of a communication between the cyst and the right ventricle by an opening in the intervening membrane. The patient was last observed February 17, 1943, six years after ventriculography. Her general health was still good, although she continued to have headaches of moderate severity. Her vision was good, the margins of the optic discs were slightly hazy but not edematous, and the visual fields had not changed in six years. Lumbar puncture on that date showed a pressure of 120 mm. of water (normal); the fluid contained 30 mg. per 100 cc. of total protein.



FIGS. 1 and 2—Lateral and posteroanterior roentgenograms of the skull, after the introduction of air into the left lateral ventricle and into the right occipital porencephalic cyst, showing depression of the right lateral ventricle and dislocation of the midline toward the left side.

COMMENT

This cavity undoubtedly represented a porencephalic cyst, which produced symptoms and signs of increased intracranial pressure, including severe headaches and papilledema. The site of the lesion in the right occipital lobe was not suspected, and the few localizing symptoms suggested the possibility of a cerebellar lesion. In view of the extensive involvement of the right occipital lobe, it was surprising that there was no evidence of a well-defined left homonymous hemianopsia, but merely a slight partial temporal field loss in the left eye alone. Origin of the cyst was obscure, although the absence of symptoms prior to middle life, the unilaterality of the lesion, and the absence of communication with

the ventricle suggested an acquired lesion rather than a primary developmental aplasia.

It was particularly interesting that the total protein content of the cystic fluid was greatly increased (175 mg. per 100 cc.), and the total protein content of the fluid obtained from the left ventricle was normal (15 mg. per 100 cc.). This might account for the increased intracranial pressure, for there would tend to be a continuous slow passage of fluid by osmosis from the right lateral ventricle across the semipermeable membrane into the closed cyst cavity. Increased pressure within the cyst could result in downward dislocation of the right ventricle, and lateral dislocation of the posterior part of the third ventricle and of the upper part of the aqueduct. Thus the partial obstruction to the circulation of the cerebrospinal fluid could account for a moderate degree of increased intracranial pressure with low-grade papilledema.

This case presents many features of similarity with that reported by Love and Groff.² In their case a large right occipital porencephalic cyst was accompanied by increased intracranial pressure and symptoms suggestive of a cerebellar lesion. The fluid within the cyst was yellow and probably contained a large amount of protein. They established a communication between the cyst and the ventricle and thus relieved the increased intracranial pressure by destroying the osmotic mechanism.

Thus far in the case here reported, the patient's symptoms have not been troublesome nor severe enough to require such a procedure, although she will be carefully observed each year with such a possibility in mind.

SUMMARY

A case of porencephalic cyst is reported. An explanation is offered for the presence of increased intracranial pressure on the basis of osmosis between the ventricular fluid and the cystic fluid, with resultant partial obstruction to the flow of cerebrospinal fluid through the third ventricle and aqueduct.

REFERENCES

1. Yakovlev, P. I. and Wadsworth, R. C.: Double symmetrical porencephalies. *Tr. Am. Neurol. A.* 67:24, 1941.
2. Love, J. G. and Groff, J. E.: Porencephalic cyst: report of a case. *Proc. Staff Meet., Mayo Clin.* 14:709, 1939.