

# THROMBOANGIITIS OBLITERANS IN WOMEN

## *Report of Two Cases*

F. A. LeFEVRE, M.D., and JAMES BURNS, M.D.\*

From 1934 to 1943 seventy-seven cases of thromboangiitis obliterans were diagnosed at the Cleveland Clinic. Only two of these cases occurred in women, and these were observed during the past two years. It is common knowledge that this condition is exceedingly rare in the female; the cause for this has never been determined.

The two cases discussed in this paper bring the total number of cases on record to thirty-one. In a review of the literature in 1938, Millman<sup>1</sup> found only twenty-two authenticated cases, to which he added the report of one case. Since that time the following cases have been reported: Atlas<sup>2</sup> described the condition in a woman 68 years old; Seidenstein<sup>3</sup> reported a case in a 33 year old woman, which was indistinguishable from the typical syndrome in a man; Robinson<sup>4</sup> reported a case associated with the menopausal syndrome; Wilensky and Collens<sup>5</sup> reported two cases occurring in sisters; Hammarström<sup>6</sup> discussed the occurrence of the syndrome with gangrene of the extremities and of a loop of small intestine with portal thrombosis.

**Case 1**—A Gentile woman, aged 32, was admitted to the Cleveland Clinic on May 5, 1942 because of ulceration of the toes and fingers. Three months prior to her admission she first noticed pain and slight swelling with some coldness and increased sensitivity in both of her feet. The pain was rather severe and came on suddenly but persisted even when she was at rest. On several occasions the calf area was quite tender, and several small, firm, tender nodules were present on the calves of both legs. One month after the onset of this condition an infection of the right third fingernail was opened and drained, and soon after this the procedure was repeated on the right little finger. Several weeks later a painful ulcerating area involving the left little toe developed, which was soon followed by a similar ulcer at the base of the left great toe (fig. 1). Pain and ulceration continued until her admission.

The past history was not significant. A thyroidectomy was performed in March 1942, and at the time of operation the patient had an active hyperthyroid condition. She had used tobacco for twelve years and smoked about twenty cigarettes per day.

The results of the physical examination were normal except for the findings in the extremities. The left small toe was found to be swollen and painful, the distal two-thirds bright blue in color, the tip ulcerated, and the toenail almost completely destroyed. There was a large irregular area of necrosis beneath the left great toe. The distal phalanx of the right middle finger was likewise swollen, dull red in color, and tender. There was an ulcer on the ulnar side of the nail fold, and the nail was almost completely separated from its bed. Further examination of the extremities revealed no areas of active phlebitis. Several firm nodules were present in the left calf but were not tender. X-ray of the left extremity revealed no evidence of arterial calcification. Routine laboratory tests were normal. The feet were moderately cold to palpation, and definite alterations in color upon change of position were noted. There was a slight delay in venous filling time. Readings with the oscillometer revealed the following results:

\*Former Fellow in Medicine.

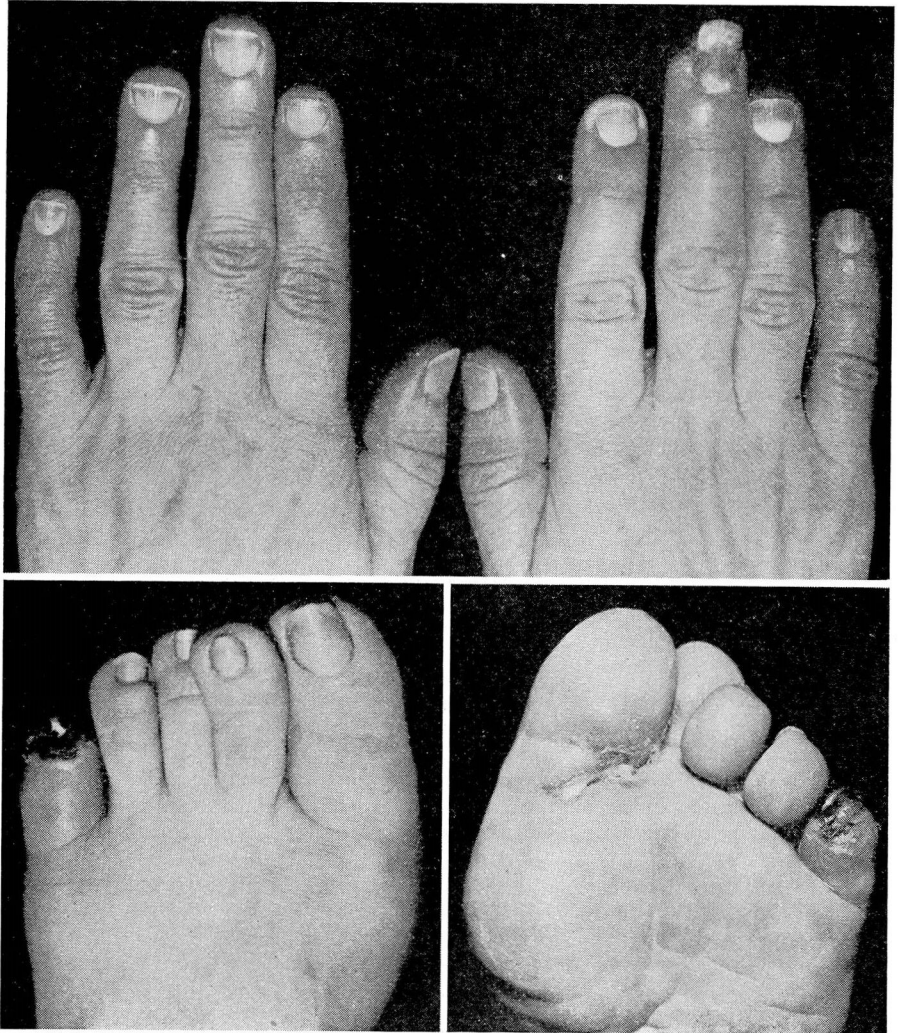


FIG. 1  
OSCILLOMETRIC INDEX

	<i>Right</i>	<i>Left</i>
Calf.....	5	1
Ankle .....	2	$\frac{1}{2}$
PULSE		
Femoral.....	3	3
Popliteal.....	2	0
Posterior tibial.....	2	0
Dorsalis pedis.....	1	0

The clinical diagnosis was thromboangiitis obliterans.



## THROMBOANGIITIS OBLITERANS

**Case 2**—A Gentile woman, aged 37, was admitted to the Cleveland Clinic on December 27, 1943 because of an ulcerated toe. Ten months prior to her admission she first noted pain in the right calf, which occurred especially while walking and was usually relieved by resting. This was followed by some increased coldness of the leg with color changes. In addition she noticed pain in the right second toe, even at rest. Two weeks before admission she cut the toe while trimming the nail. It did not heal readily, and soon an area of considerable tenderness and ulceration developed (fig. 2).

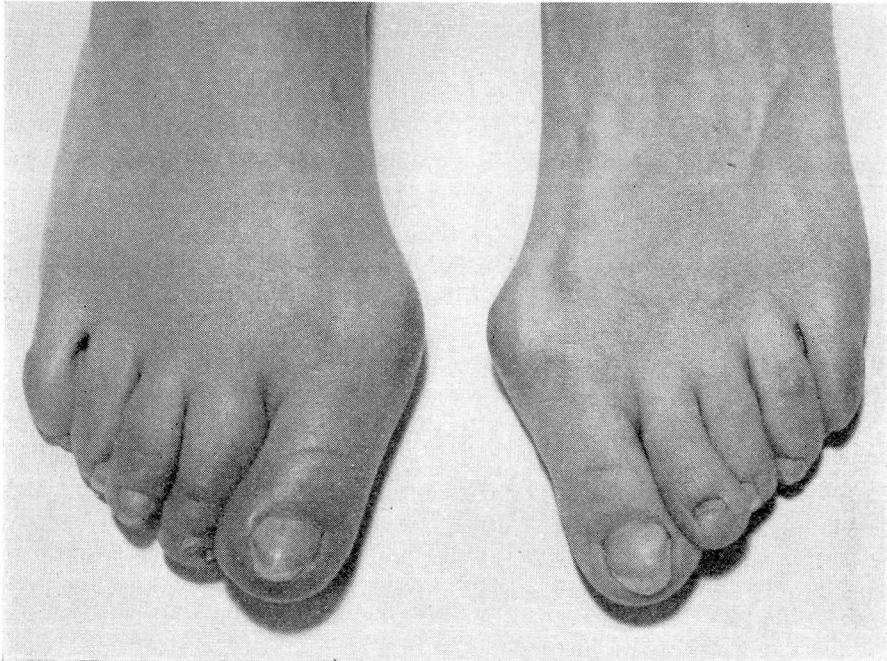


FIG. 2

The past history was essentially negative. She had had no serious illnesses nor operations. For the past ten to twelve years she had smoked ten to twenty cigarettes a day.

The results of the physical examination were normal except for the findings in the right leg. The right foot was colder than the left and color changes were rather marked, particularly on change of position. X-ray examination of the extremities revealed no evidence of arterial calcification. Routine laboratory work was normal. Oscillometric readings were as follows:

OSCILLOMETRIC INDEX		
	<i>Right</i>	<i>Left</i>
Calf.....	5	5
Ankle .....	1½	1½
PULSE		
Femoral.....	3	3
Popliteal.....	2	2
Posterior tibial.....	1	1
Dorsalis pedis.....	0	0

Thromboangiitis obliterans was the clinical diagnosis.

### TREATMENT

The treatment<sup>7</sup> for these patients was similar. Both were hospitalized immediately and placed at complete bedrest. The head of the bed was raised slightly in order to keep the extremities at the optimum level for circulation. Heat was applied by means of a thermostatically controlled heat cradle. Buerger-Allen exercises were carried out regularly. Typhoid vaccine was given intravenously, the dosage regulated to produce a rise of only two to three degrees in temperature. On alternate days 3 per cent saline solution was given intravenously. The use of tobacco was discontinued. After three weeks of therapy definite improvement in both patients was noted. The first patient returned home and resumed her smoking habit. Several months later she was readmitted with a recurrence of ulceration, and treatment as outlined was repeated.

### COMMENT

In our opinion the two cases presented a true clinical picture of thromboangiitis obliterans. The diagnosis was made from the history of a progressive circulatory disturbance involving the extremities, resulting in ulceration and gangrene. Examination revealed definite evidence of reduced circulation in the extremities as indicated by color changes, change of temperature, and reduced peripheral pulsation, and in the first case by reduced oscillometric readings. The oscillometric readings were not greatly reduced in the second case, although the readings at ankle level were slightly lowered. This can be explained by the short duration of the condition. X-ray studies ruled out demonstrable arterial calcification in both cases. It is interesting to note that both of the patients had used tobacco rather heavily for several years.

Two features of the history of the first case are interesting. The history of thrombophlebitis is quite consistent with the occurrence of thromboangiitis obliterans and frequently precedes arterial involvement. This patient had hyperthyroidism preceding the onset of vascular changes; in our experience, the occurrence of hyperthyroidism and thromboangiitis obliterans is exceedingly rare.

### REFERENCES

1. Millman, Samuel: Thromboangiitis obliterans in a woman. *Am. Heart J.* 15:746-748 (June) 1938.
2. Atlas, L. N.: A case of Buerger's disease in an old woman. *Am. Heart J.* 26:120-123 (July) 1943.
3. Seidenstein, Harold: Unusual peripheral vascular disease in a woman (thromboangiitis obliterans?). *Bull. Hosp. Joint Dis.* 3:73-75 (April) 1942.
4. Robinson, S. K.: Thromboangiitis obliterans in a woman with the menopausal syndrome. *Medical Record* 149:223-224 (April 5) 1939.
5. Wilensky, N. D., and Collens, William S.: Thromboangiitis obliterans in sisters. *J.A.M.A.* 110:1746-1747 (May 21) 1938.
6. Hammarström, E.: Gangrene of extremities and of loop of small intestine and portal thrombosis in a woman. *Svenska läk-tidning.* 36:1565-1572 (Aug. 25) 1939.
7. Le Fevre, F. A.: Thromboangiitis obliterans. *Cleve. Clin. Quart.* 9:104-109 (April) 1942.