

Oral infection with hypertrophy of the gums is a prominent symptom in monocytic leukemia. The spleen is seldom palpable. The leukocyte count is usually not very high. The anemia is often macrocytic.

Acute lymphoid leukemia is characteristically a disease of childhood. Anemia, bleeding, and joint pain and swelling are frequent symptoms.

Acute myeloid leukemia occurs in all ages and is characterized by the greatest variety of symptoms and clinical findings.

Chronic lymphoid leukemia is often a very mild disease and runs a benign course. Enlargement of glands and spleen is the outstanding feature.

Chronic myeloid leukemia is characterized by marked toxemia causing almost constant fever and anemia.

## **INTRAMEDULLARY FIXATION OF CERTAIN FRACTURES OF BOTH BONES OF FOREARM**

### *Report of Two Cases*

JAMES A. DICKSON, M.D.

Everyone who has treated many fractures in the middle third of both bones of the forearm realizes the difficulty of reducing and maintaining these fractures in proper position. Even in skilled hands several manipulations may have to be carried out before a satisfactory and acceptable position can be obtained in both bones.

The use of the Kirschner wire through the lower end of the radius and the upper end of the ulna to maintain traction is attended with certain difficulties and the possibility of pin infection. Internal fixation by means of a metal plate is also a difficult procedure, particularly in children because the bones are quite small and do not lend themselves to plating.

Intramedullary use of the Kirschner wire in fractures of the clavicle has been reported on many occasions with excellent results, and it has been suggested that intramedullary use of the Kirschner wire might prove effective in fractures of both bones of the forearm. However, I cannot find any article in the literature in which this method has been previously employed for this type of fracture. In cases in which open operation was indicated in order to procure a satisfactory reduction, I found the use of intermedullary fixation so simple in application and so gratifying in result that I wish to report two cases.

## FRACTURES OF FOREARM




FIG. 1. Case 1. (a and b) Position of fracture after manipulations before open reduction. (c) Wire in position.

### CASE REPORTS

**Case 1.** A boy, 14 years of age, received fractures of both bones of the forearm. When he was referred to me, three unsuccessful attempts at reduction had been made

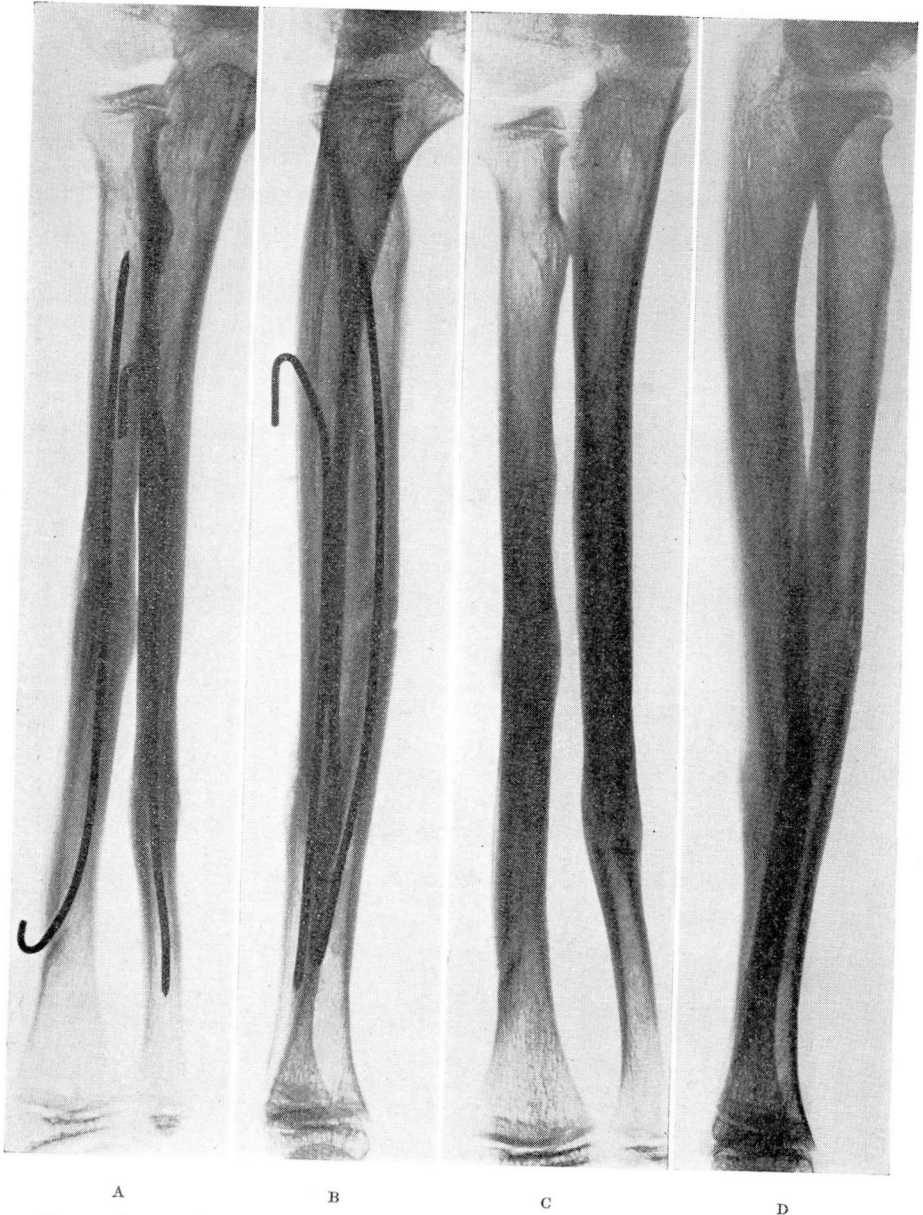

FIG. 2. Case 1. (a and b) Excellent callus formation at the end of eight weeks. (c and d) Result at end of twelve weeks after removal of wires.

under anesthesia. The position that was obtained is shown in figure 1. The arm was very swollen, and any further attempt at manipulation seemed contraindicated.

## FRACTURES OF FOREARM

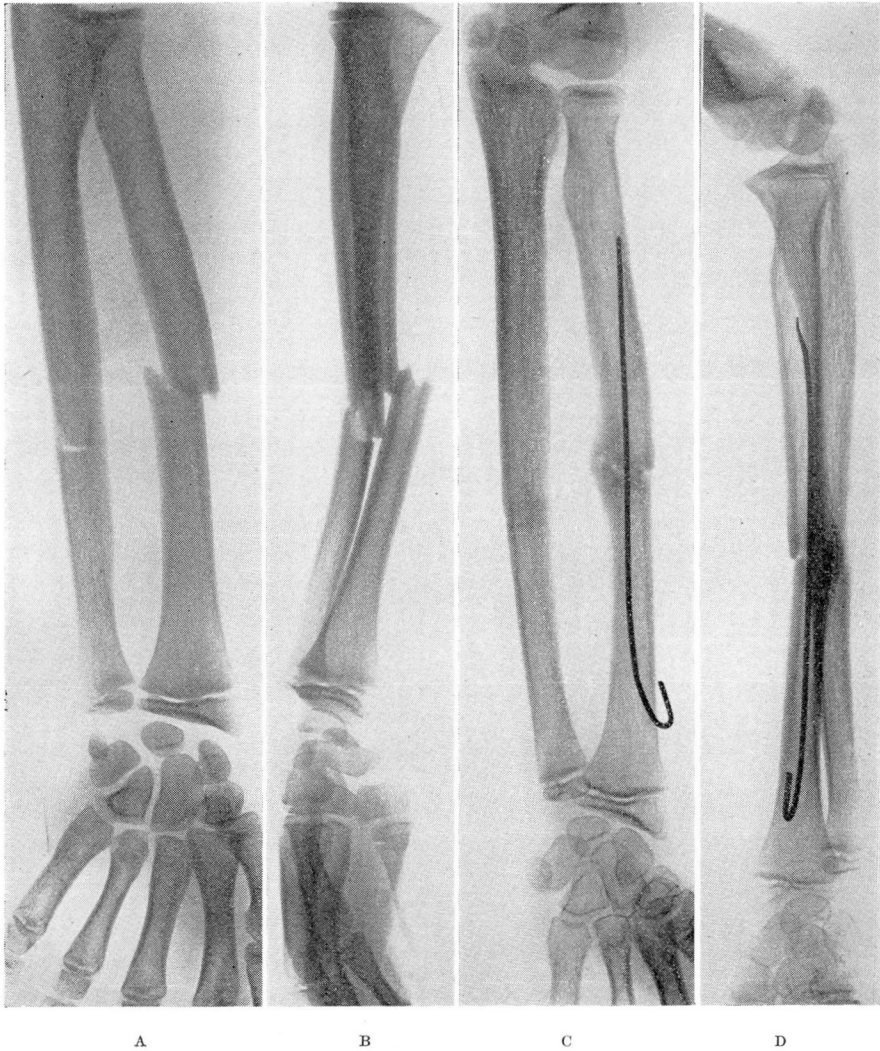


FIG. 3. Case 2. (a and b) Position of fragment before open reduction after open manipulation. (c and d) Position and callus formation at end of eight weeks. Wire removed under local anesthesia at end of twelve weeks.

Under anesthesia an incision was made over the fracture site of the radius, and without stripping the periosteum the fracture was reduced, the ends of the bone being held by means of bone forceps. A small incision was made over the lower end of the radius and a hole drilled into the medulla in a slanting position. Into this was threaded a Kirschner wire. The wire was slightly bent on the tip to facilitate its passage up the medullary canal. The wire was gradually eased up the canal with pliers, as the use of a drill tends to engage the point of the wire in the cortex. When the wire reached the site of the fracture, the wire outside the bone was measured. The fracture was then

## JAMES A. DICKSON

brought into position, and the wire threaded 2 or 3 inches into the upper fragment. The end of the wire was cut and turned upwards over the outer surface of the bone. A similar procedure was carried out for the fracture of the ulna, but this time the wire was inserted into the upper fragment of the ulna and passed across the fracture line into the lower fragment. The results of the procedure are readily demonstrated in the x-ray photographs (figure 1).

The tissues were allowed to fall back into position and the wounds closed. A light, rather loosely fitting cast was applied from the palm to the midupper arm. The usual postoperative care was given, and when satisfactory callus formation was obtained, the child was allowed normal function. At the end of the third month a small incision was made over the hooks of the Kirschner wires under local anesthesia and the wires readily removed. The results are shown in figure 2.

**Case 2.** A boy, aged 13, also had two manipulations under anesthesia before he was referred to me, and further attempts at closed reduction were deemed inadvisable. In this particular case after reduction of the radius the ulna came into such excellent position that insertion of the second wire into the ulna was not thought to be necessary. The position obtained and the excellent callus formation are shown in figure 3.

### SUMMARY

Intramedullary fixation by means of Kirschner wires is an excellent procedure for fractures of the forearm which are not satisfactorily reduced by manipulation alone. When open operation is believed necessary, this method is much simpler than the use of metal plates. There is no stripping of the periosteum, and the fracture ends are maintained in the most favorable position for repair. This also affords a certain amount of impaction at the fracture site, which stimulates callus formation. The method is simple in application and should produce a perfect anatomic result with the minimum possibility of any complications. It has the added advantage that the internal fixation can readily be removed when it has served its purpose.

## PROTRUSION OF INTERVERTEBRAL DISK

### *A Common Cause of Sciatica*

W. JAMES GARDNER, M.D.

Since the days of *Pithecanthropus erectus*, man has been paying for the privilege of walking on his hind legs. Nature designed the human body for four-legged locomotion, and evolution has not yet accomplished the structural changes required by this relatively new mode of progression. As a result, certain inherent anatomic weaknesses are expressed in the form of peculiarly human maladies. Some of the more common are flat feet, varicose veins, hemorrhoids, cystocele, hernia, backache, and sciatica. The latter condition is usually due to