

# RETICULUM CELL SARCOMA OF JEJUNUM

## *Report of a Case*

R. S. DINSMORE, M.D., and V. C. ANCONA, M.D.

Ewing<sup>1</sup> in 1913 was probably the first to divide lymphosarcoma into two histologic types, (1) the malignant lymphocytoma (small round cell sarcoma) and (2) the reticulum cell sarcoma (large round cell sarcoma). It was his belief that the former originated from the lymphocyte, and the latter from the reticulum cells of the germ centers of the lymph follicles and pulp cord. Kundrat<sup>2</sup> was the first to isolate lymphosarcoma from other lymphatic diseases and describe its clinical characteristics.

Sarcoma of the small intestine is rare. According to some writers<sup>3</sup> lymphosarcoma is one of the more common sarcomas of the gastrointestinal tract. Chont,<sup>4</sup> in a review of specimens from 2250 necropsies and 20,603 surgical operations at the University of Oklahoma Hospital, found only 8 tumors of the small intestine, 4 of which were sarcomas.

In a review of the literature up to June 1, 1919 Graves<sup>5</sup> reported 166 cases of sarcoma of the small intestine. Ullman and Abeshouse<sup>6</sup> collected 77 additional cases up to 1932. In August 1941 Frank, Miller and Bell<sup>7</sup> collected 114 cases reported in the previous ten years and added 4 more.

### CASE REPORT

A white woman, aged 58, seen on January 7, 1944, complained of loss of appetite of two months' duration, vomiting for three weeks, and pain in the abdomen for several weeks. Apparently she was in good health until six months before admission, when she began to complain of a feeling of fullness and a dull, aching pain in the epigastrium. About four months later her pains became more frequent and more persistent, and her appetite began to fail. Vomiting was present for three weeks before admission and often occurred shortly after eating. In six months she lost 7 pounds, and according to her own report she had lost 53 pounds in two years.

The family history, the history of past illnesses, and symptoms were not significant.

Physical examination revealed a slight pallor. On abdominal examination a firm, tender, movable mass was palpable just to the right of the umbilicus. There was tenderness and slight spasticity along the right margin of the rectus muscle. Examination of the rectum was normal.

The red cell count was 3,760,000 with hemoglobin of 43 per cent, and white cell count was 5300. Total serum proteins measured 4.8 Gm. per 100 cc. Blood urea and chlorides were normal, and the blood sugar was slightly above normal.

X-ray examination of the small intestine with opaque barium revealed on the right side of the abdomen opposite the fourth lumbar vertebra marked narrowing of a seg-

ment of the upper jejunum, which measured about 12 cm. in length. The intestine proximal to this lesion was dilated.

On February 9, 1944 laparotomy was performed. A mass involving the midportion of the jejunum was immediately revealed. The surface of the jejunum was smooth and glistening, but the wall was thickened, indurated, and replaced by white, soft tissue resembling lymphosarcoma. The involved portion of the intestine was resected and a side to side anastomosis performed.

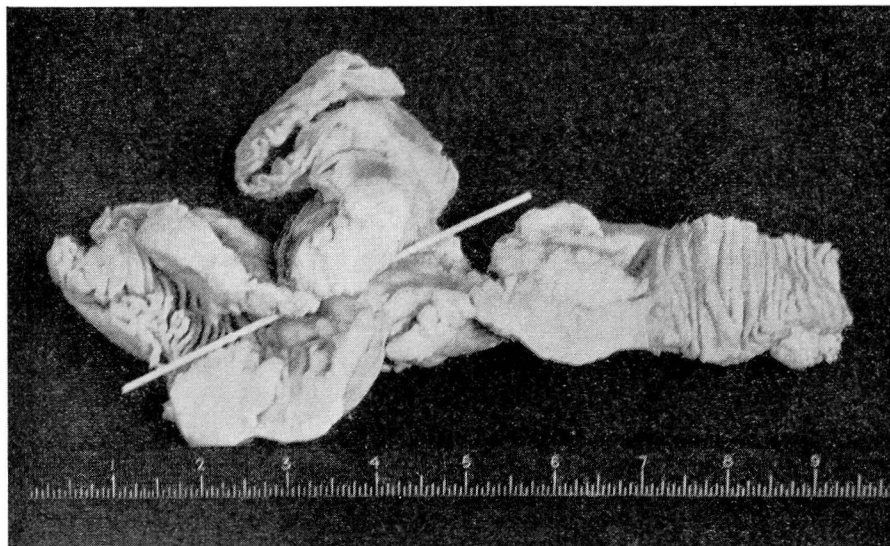


Figure. Reticulum cell sarcoma of jejunum with probe demonstrating marked narrowing of lumen of jejunum.

**Pathologic Findings.** The specimen consists of a midportion of the segment of jejunum with attached omental fat (figure). The segment measures 30 cm. in length. A tumor mass consisting of two nodules is located in the center of this segment. The serosa is pinkish white in color and fairly smooth. The tumor area is whitish gray and firm. In the center of the tumor mass is a considerable amount of stenosis causing almost complete obstruction and admitting a probe the size of a lead pencil. The segment is opened longitudinally along the anti-mesenteric border; a large tumor growth involves 16 cm. of the segment encircling the entire circumference and practically the entire mucosa. The largest tumor mass measures 2.6 cm. in thickness. The tumor is soft, very smooth, cellular, and greyish white in color. Throughout the lumen some necrosis appears to be present. In the omental fat are twelve rather firm, small lymph nodes.

The tumor involves the entire wall of the jejunum. It consists of a diffuse, fine mesh of large, slightly varied, stellate cells with no stroma other than that accompanying small blood vessels. The cells have scant cytoplasm, partly eosinophilic and partly basophilic. The nuclei are large, round, oval, uniform and irregular, hyperchromatic, and vesicular. Most have large nucleoli. Up to twenty, often atypical, mitotic figures are seen in high power field. In the mucosa replaced by tumor are a few persistent crypts of Lieberkühn, and strands of smooth muscle occur in the region of the muscularis; other-

## SARCOMA OF JEJUNUM

wise all normal structures have been replaced. The serosa is thickened by tumor, which is limited externally by fibrous tissue, mesothelium, and a few strands of fibrin. An adjacent portion of jejunum shows chronic inflammation of fourteen lymph nodes; one shows complete and another almost complete replacement by tumor like that in the jejunum, with the tumor breaking through the capsule. The other nodes show slight follicular hyperplasia, fibrosis, and chronic inflammatory infiltrate.

Reticulin preparations of the tumor show networks of fine fibrils between and apparently within the cytoplasm of tumor cells in some areas.

Pathologic diagnosis:

- (1) Reticulum cell sarcoma of jejunum with metastasis to mesenteric lymph nodes
- (2) Chronic jejunitis
- (3) Chronic hyperplastic lymphadenitis (mesenteric)

The postoperative course was uneventful, and the patient was discharged about two weeks after operation February 24, 1944. After discharge a series of x-ray treatments was applied to patient's abdomen and lumbar and sacral regions.

### SUMMARY

A case of reticulum cell sarcoma (lymphosarcoma) of the jejunum has been reported, characterized by an insidious onset, and followed by symptoms of obstruction. A palpable mass was later found to involve the entire wall of the midportion of the jejunum and to cause marked stenosis.

### REFERENCES

1. Ewing, cited by Usher, F. C., and Dixon, C. F.: Lymphosarcoma of the intestines. *Gastroenterology* 1:160-178 (February) 1943.
2. Kundrat, cited by Ullman, A., and Abeshouse, B. S., see reference 6.
3. Menne, F. R., Mason, D. G., and Johnston, R.: Lymphosarcoma of the intestine; report of 2 cases. *Arch. Surg.* 45:945-956 (December) 1942.
4. Chont, L. K.: Sarcomas of small intestine and reference to their radio-sensitivity. *Radiology* 36:86-97 (January) 1941.
5. Graves, cited by Ullman, A., and Abeshouse, B. S., see reference 6.
6. Ullman, A., and Abeshouse, B. S.: Lymphosarcoma of the small and large intestines. *Ann. Surg.* 95:878-915 (June) 1932.
7. Frank, L. W., Miller, A. J., and Bell, J. C.: Sarcoma of the small intestine; report of 4 cases. *Ann. Surg.* 115:544-565 (April) 1942.

## NARCOLEPSY AND CATAPLEXY

### *Report of Two Cases*

R. H. McDONALD, M.D.

Narcolepsy is a term suggested by Gélinau<sup>1</sup> in 1880 to designate an uncontrollable desire for sleep resulting in a trancelike state of varying duration indistinguishable from normal sleep. This occurs under condi-